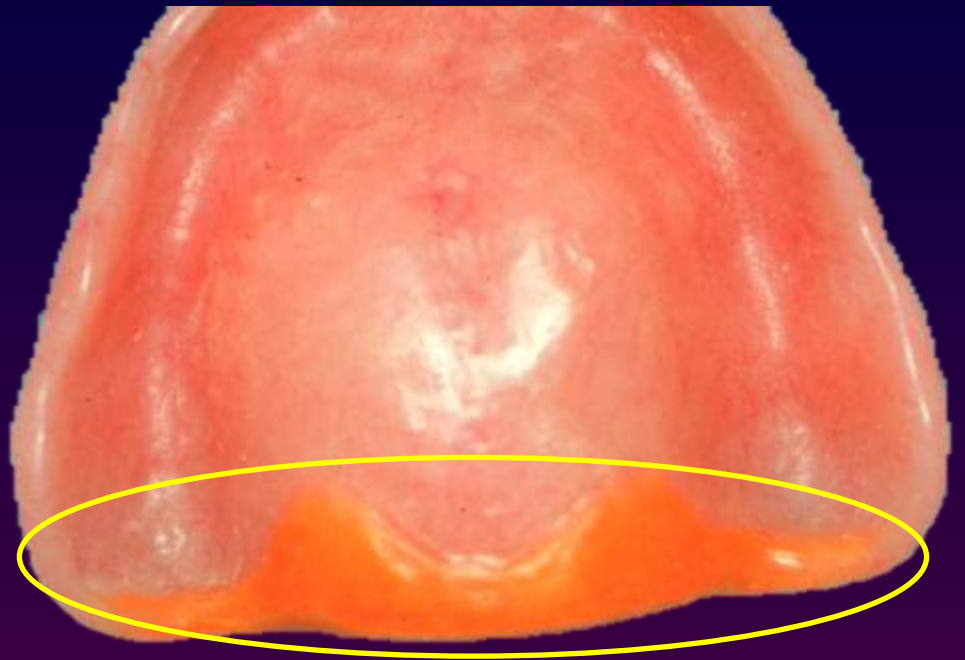
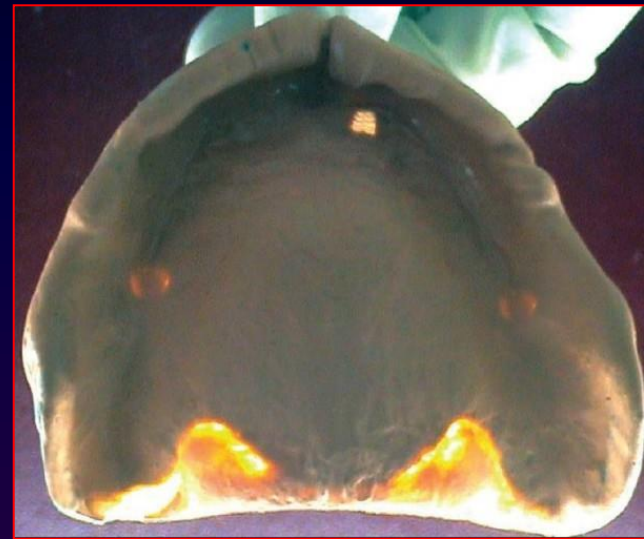
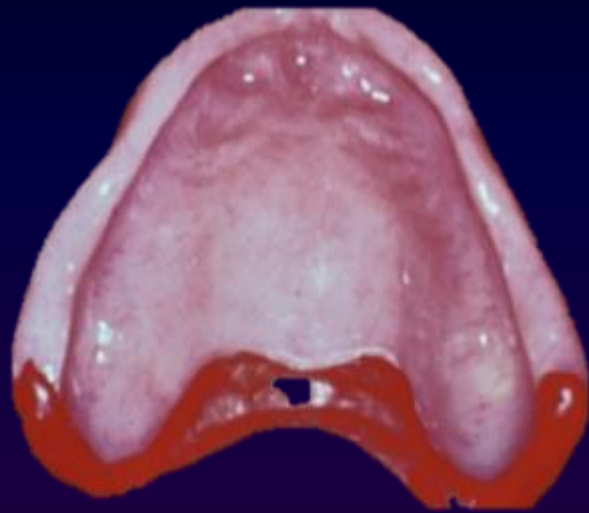
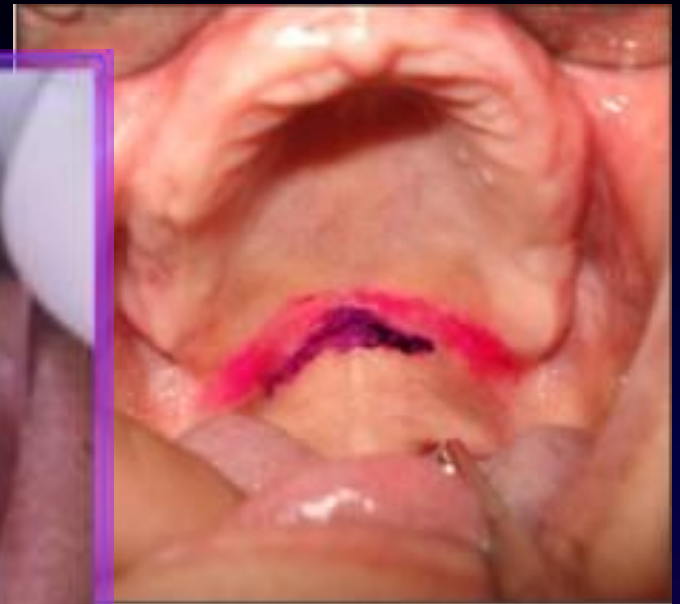
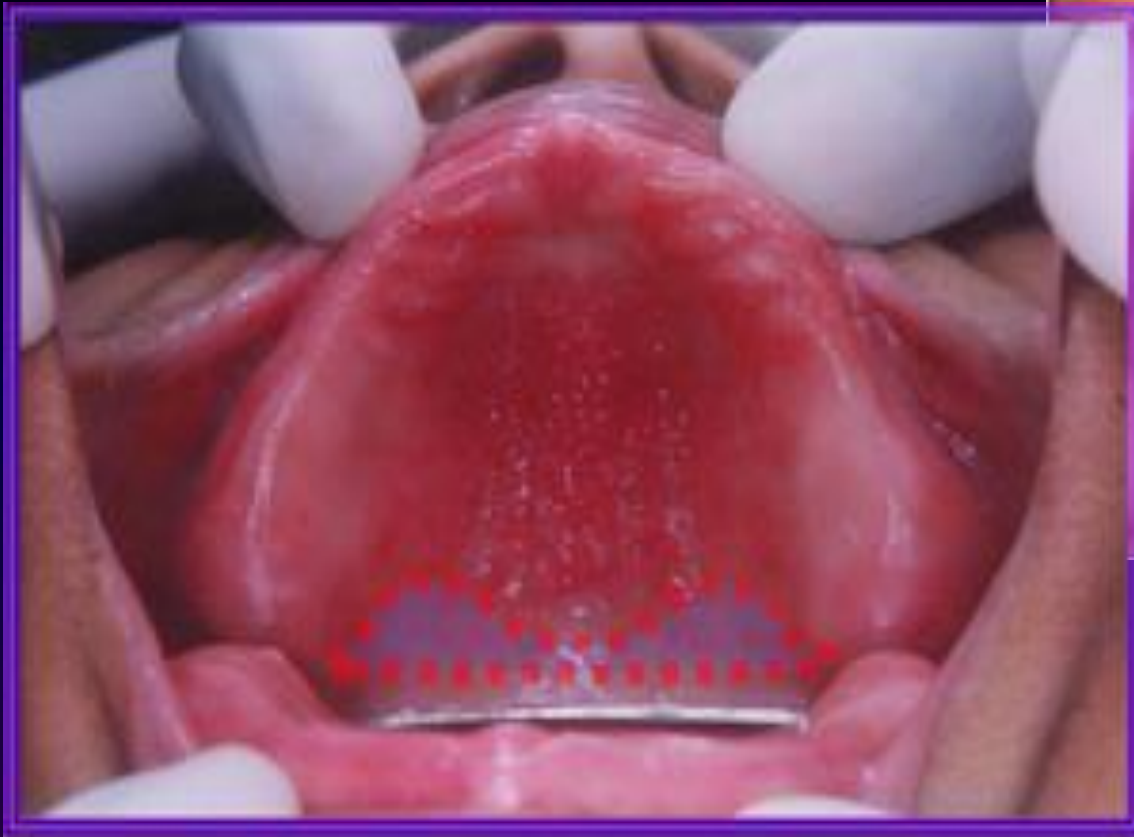
Posterior Palatal Seal



Posterior palatal seal area.

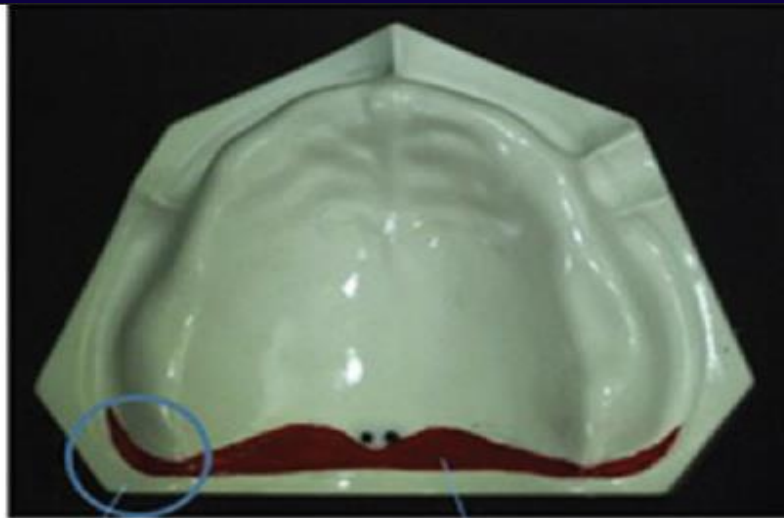




Anatomic considerations

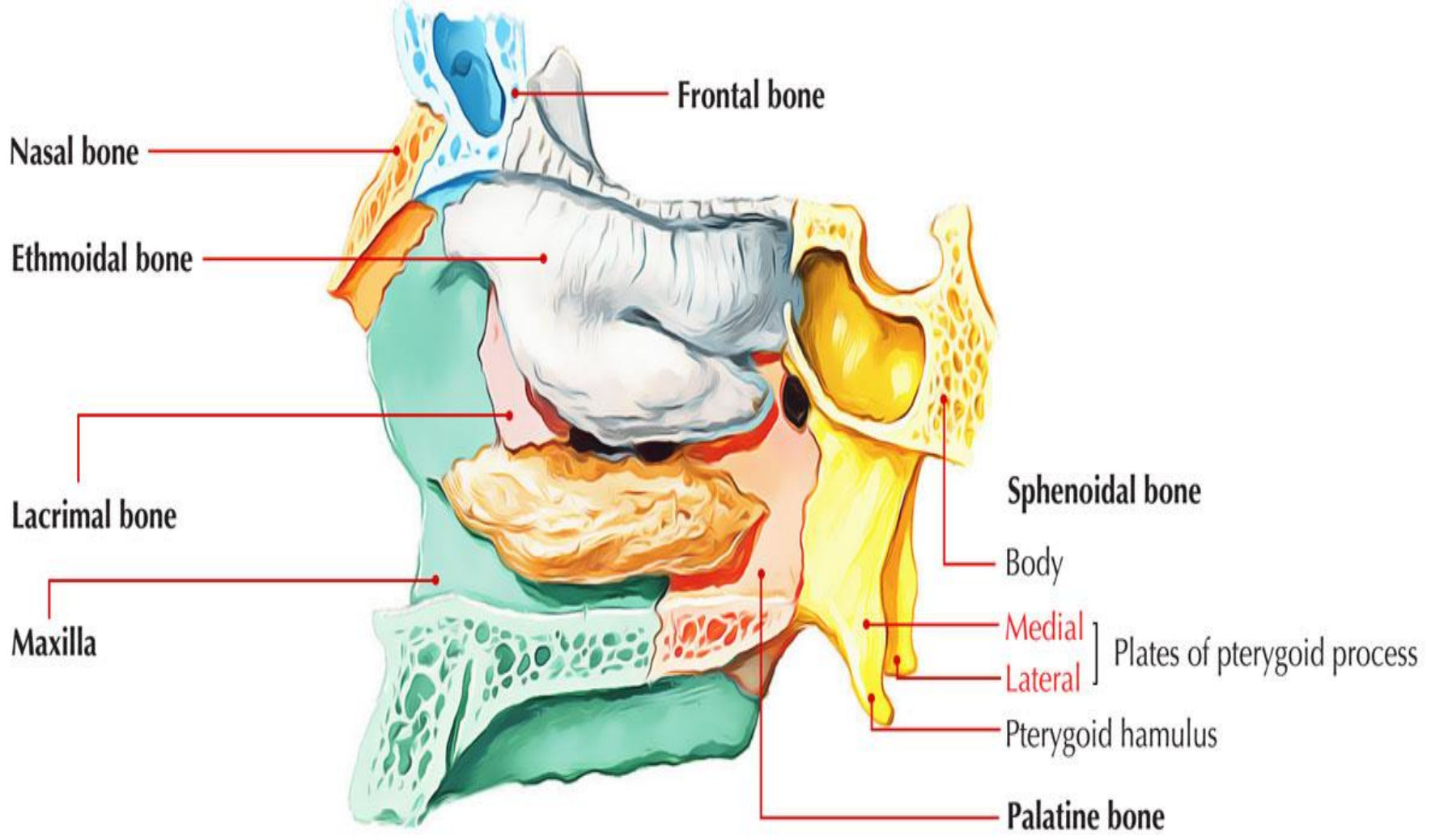
Posterior palatal seal divided according to anatomic boundaries into

- 1- Pterygomaxillary seal
- 2- Post palatal seal



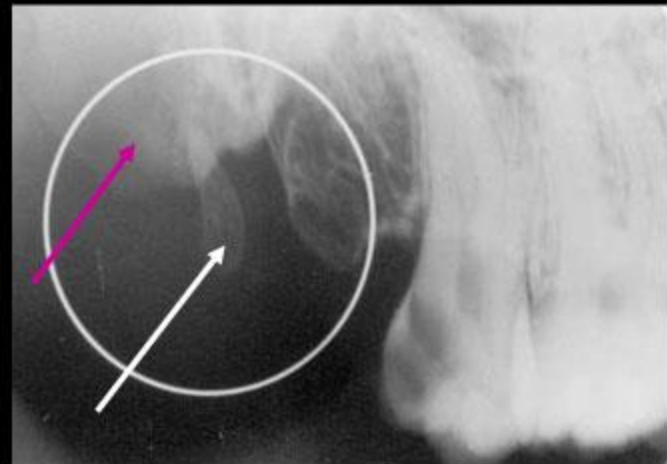
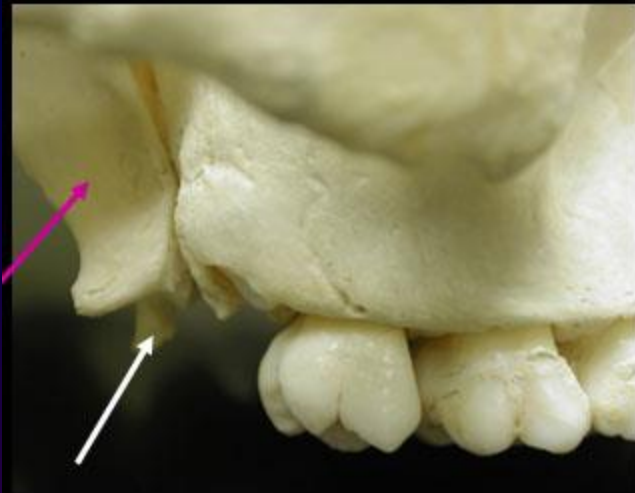PTERYGOMAXILLARY SEAL

POST PALATAL SEAL

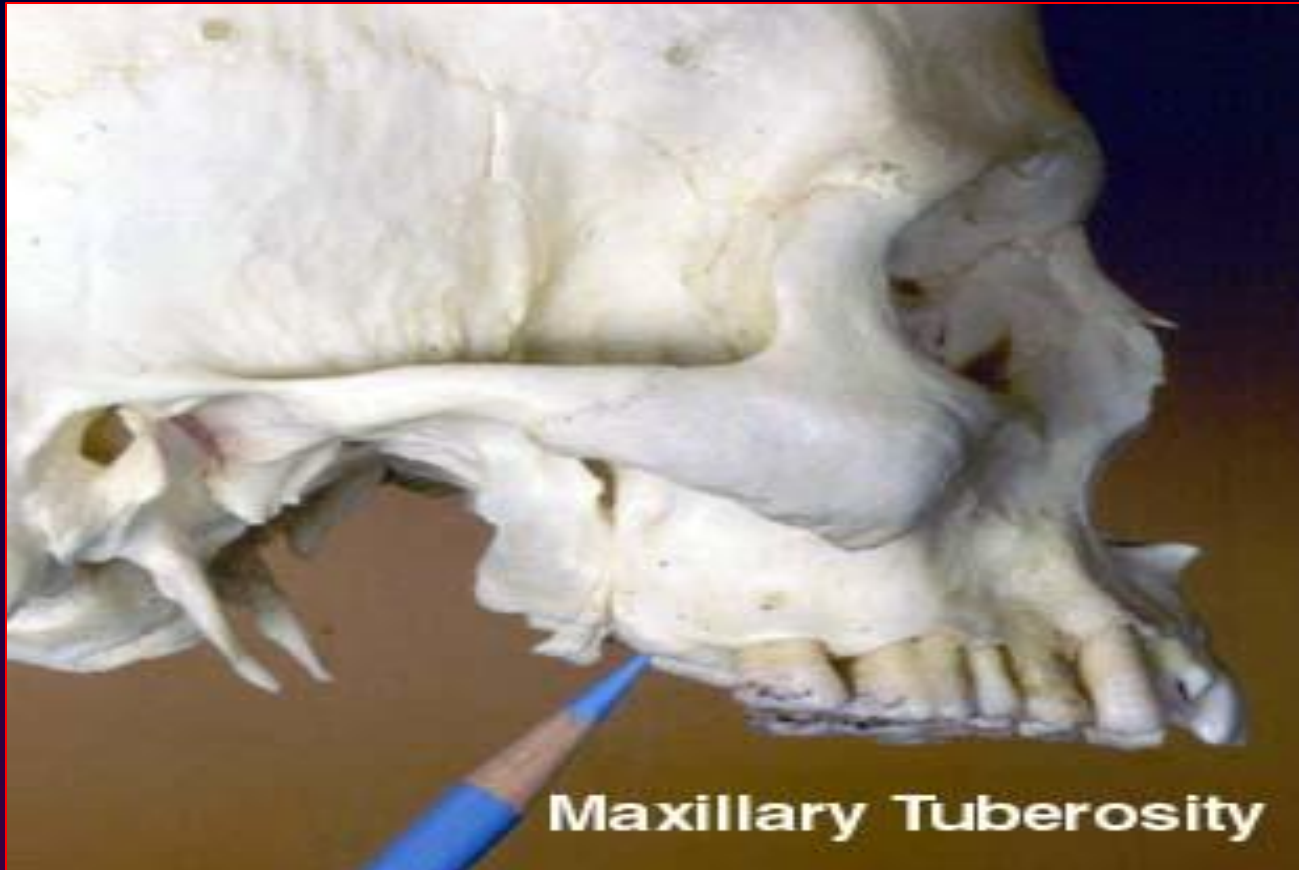

Anatomic consideration

hamular notch

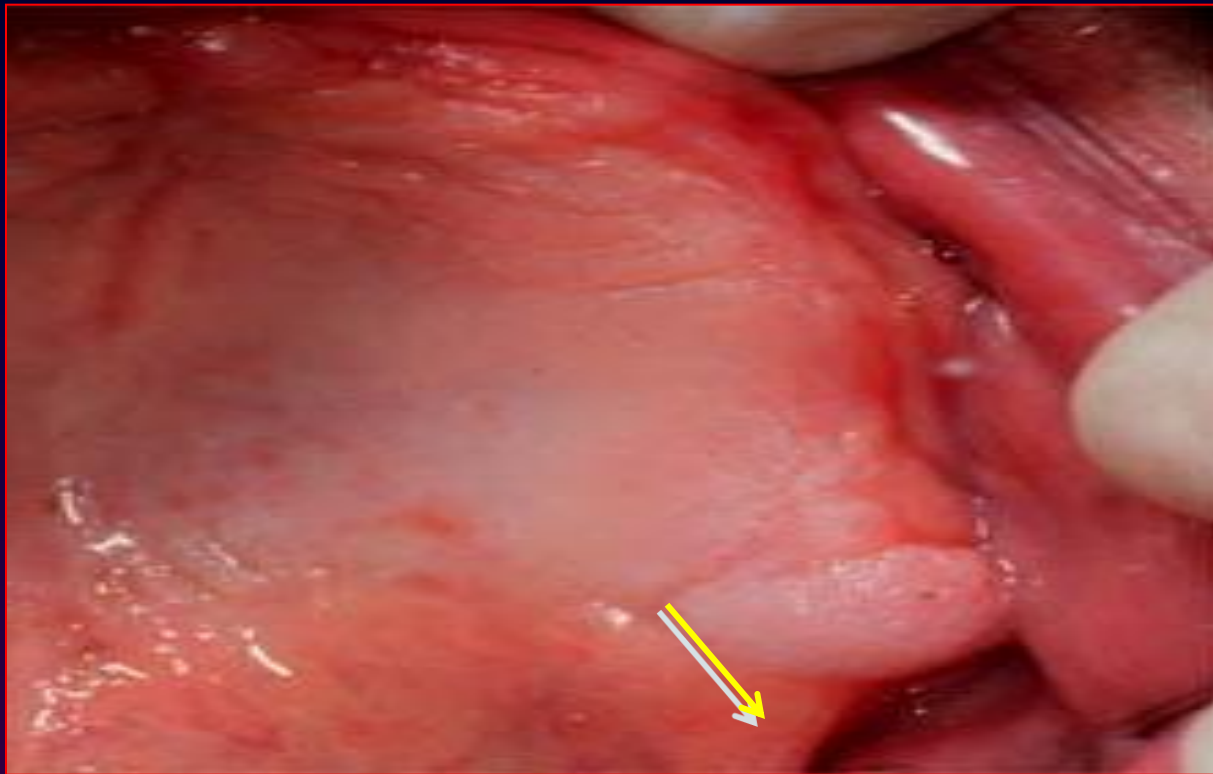


Anatomical considerations

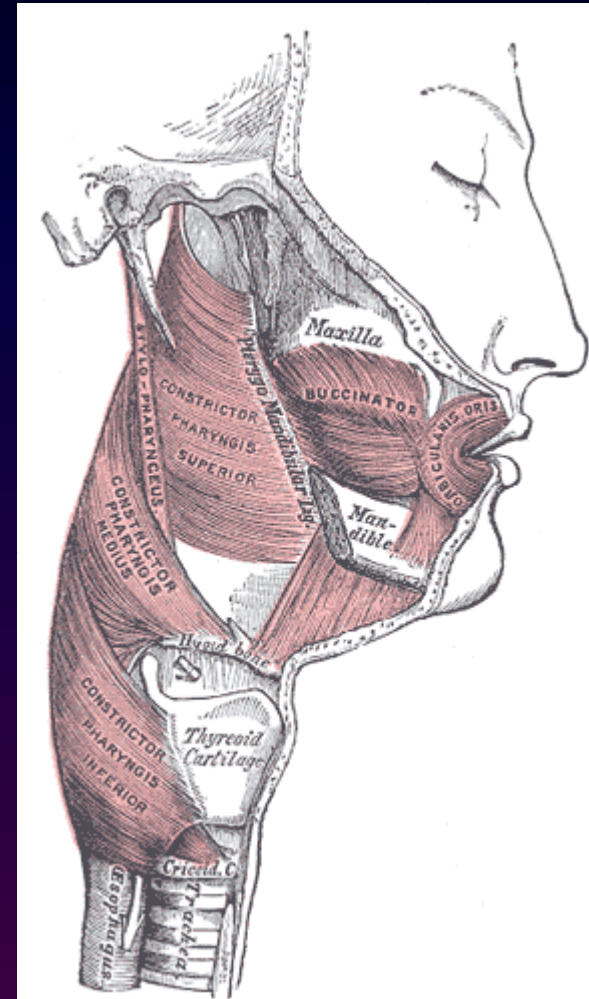
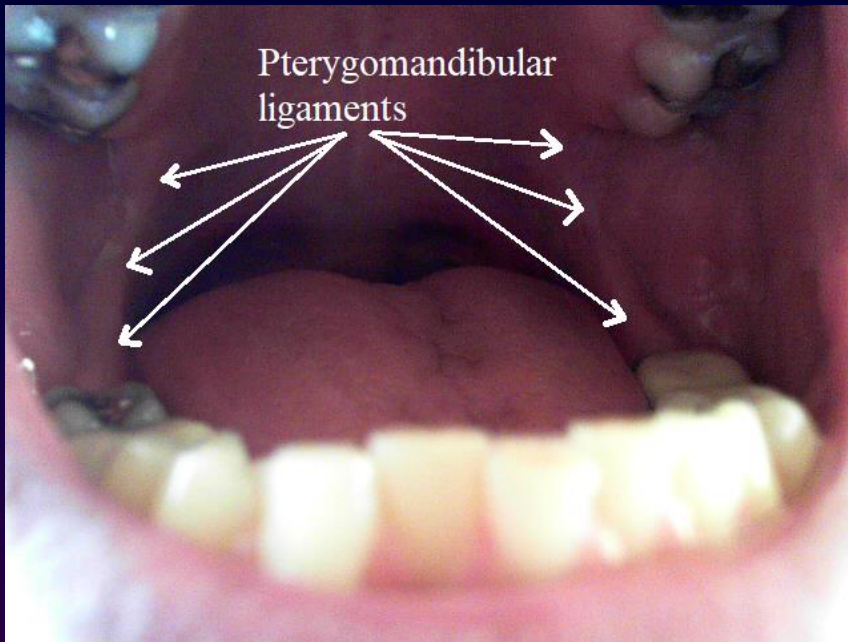


Anatomical considerations

Pterygomandibular raphe

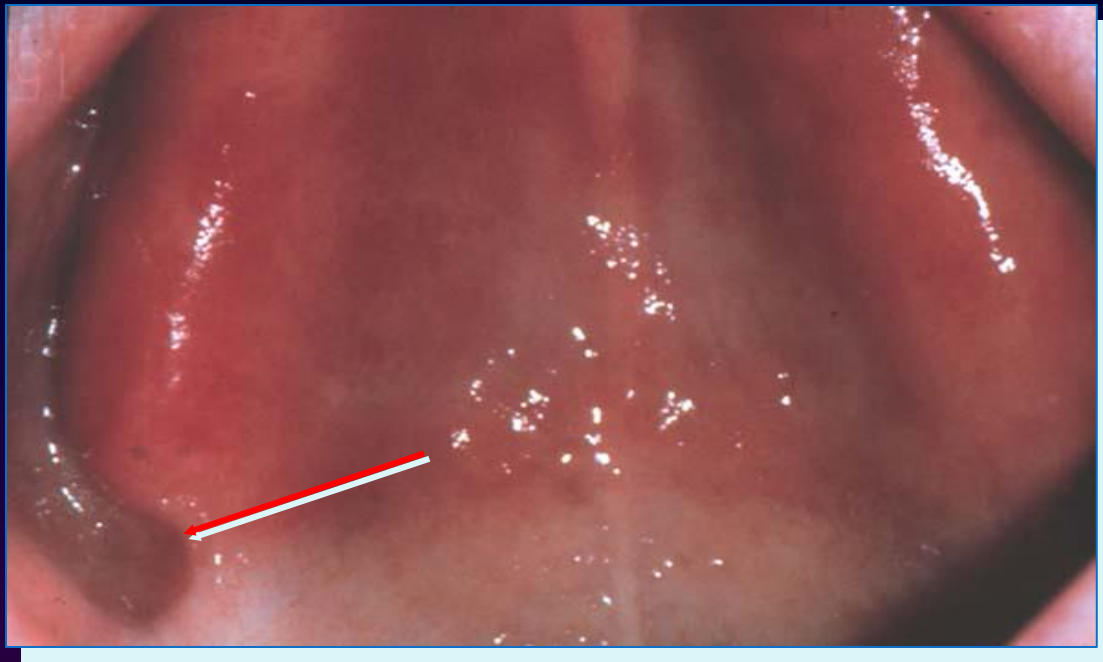

Anatomic consideration

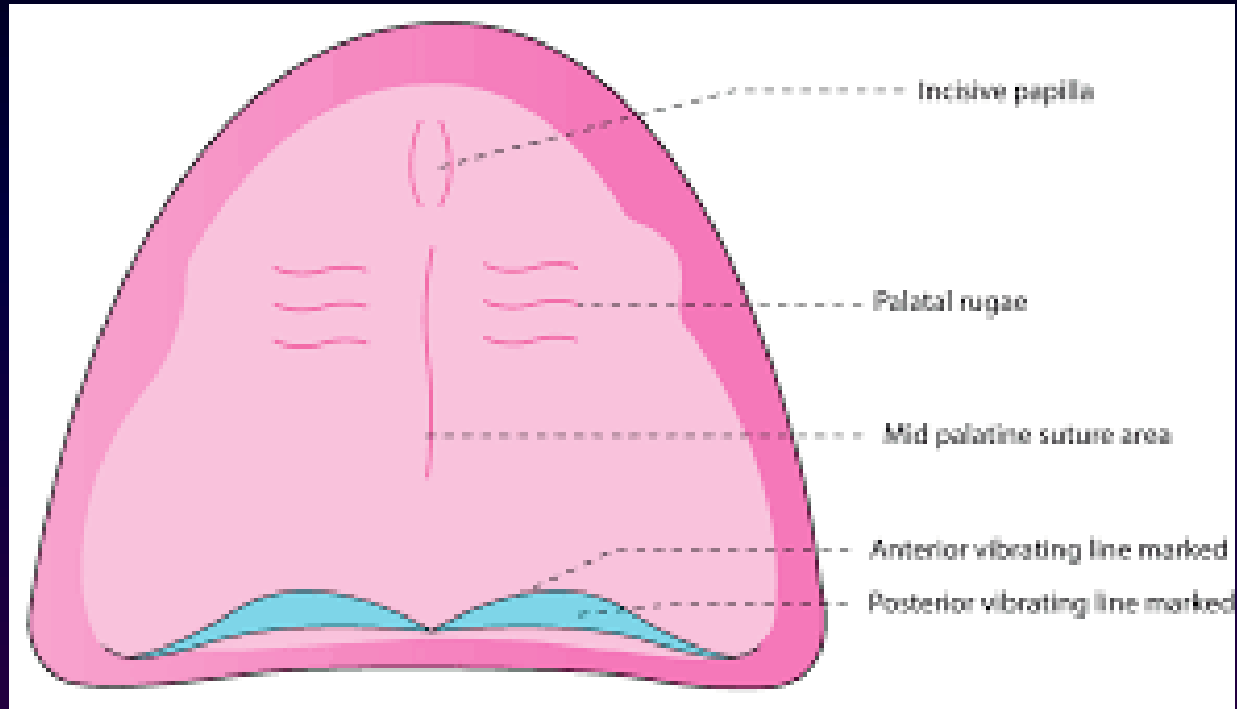


Anatomic Considerations

Hamular notch



Post palatal seal

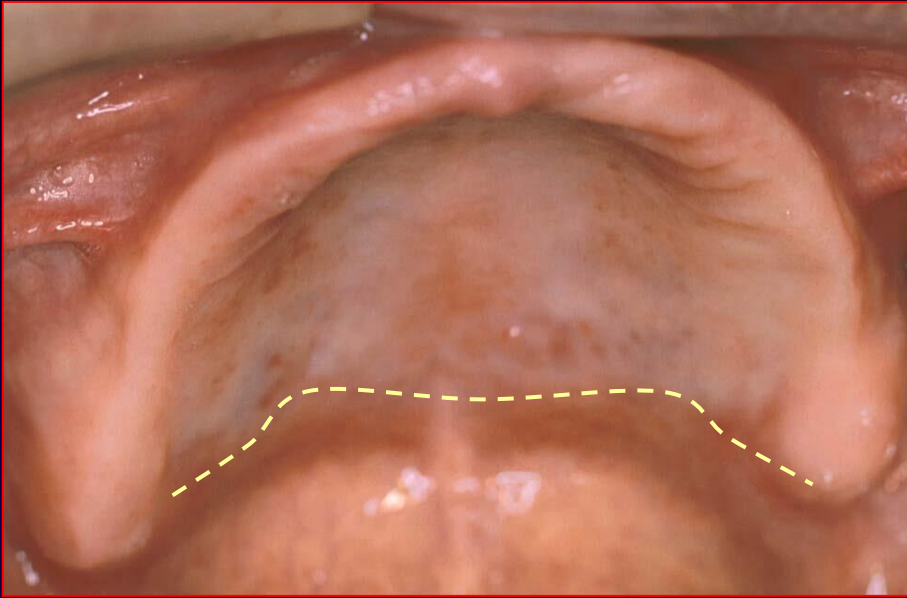


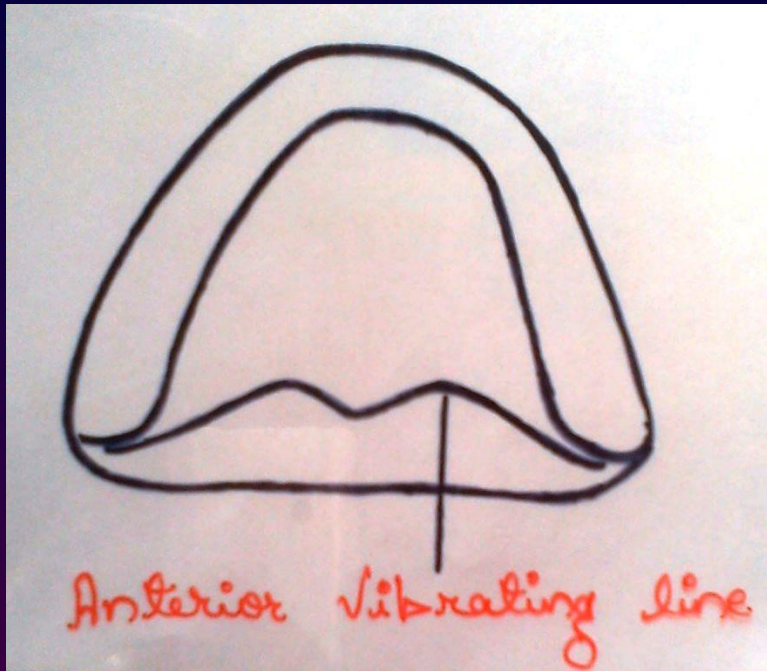

These lines are defined as follows:

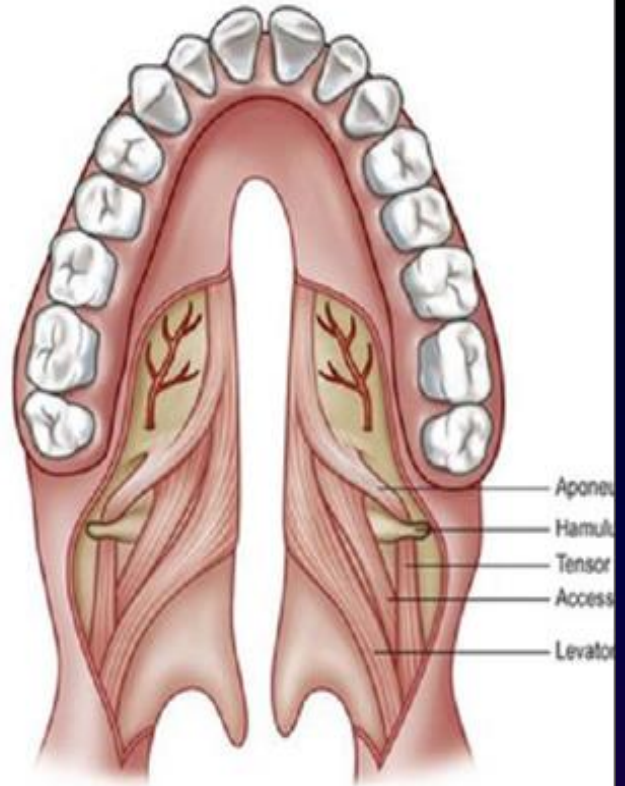
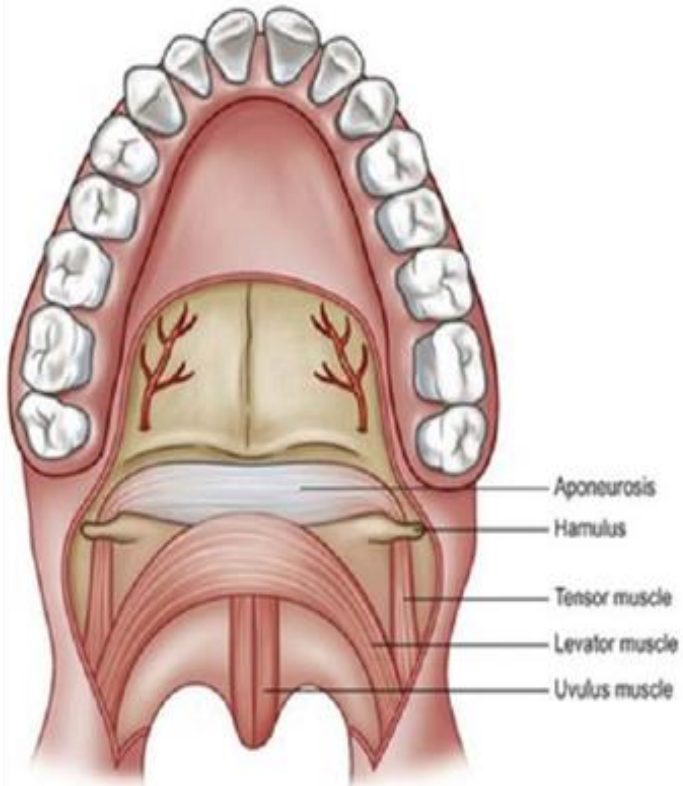
Anterior
vibrating line

Posterior
vibrating line


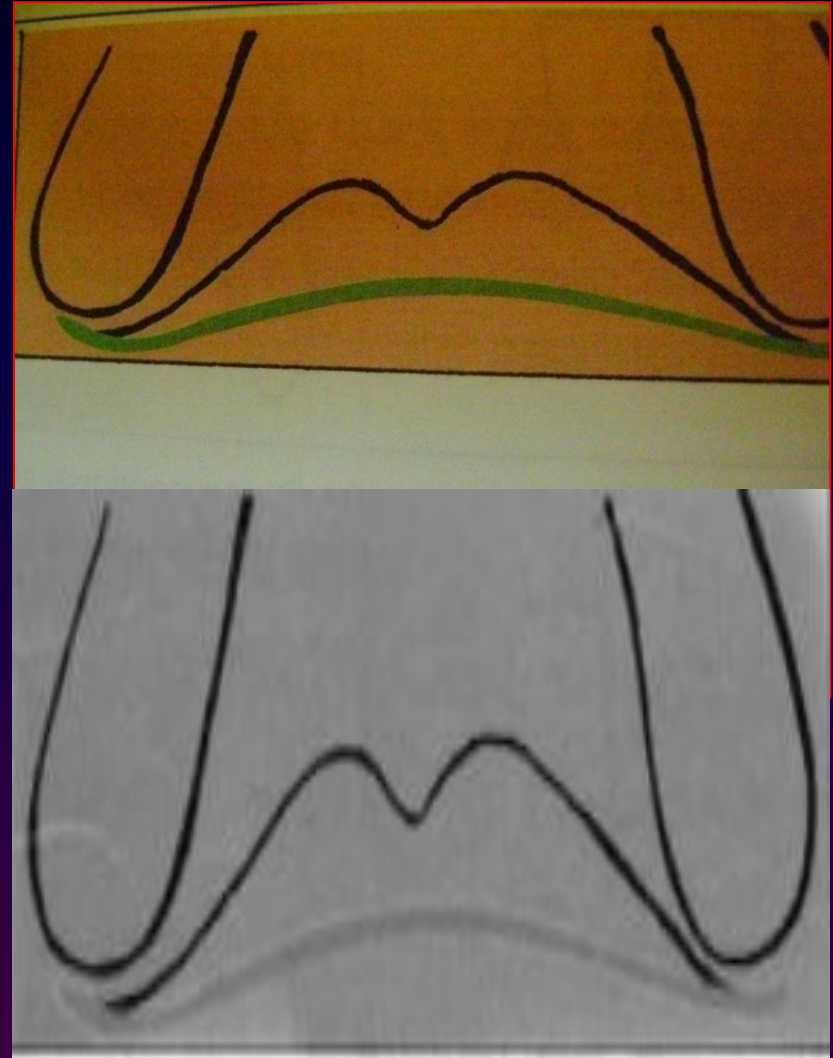
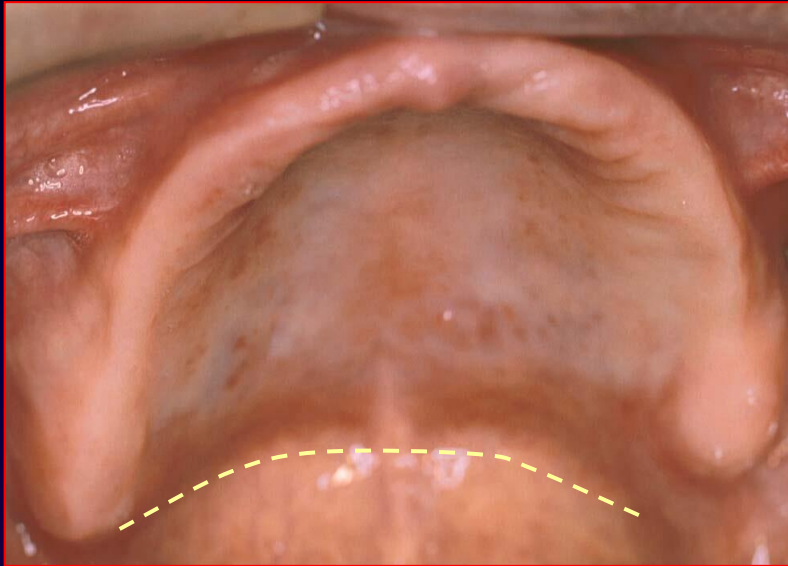
Anterior vibrating line





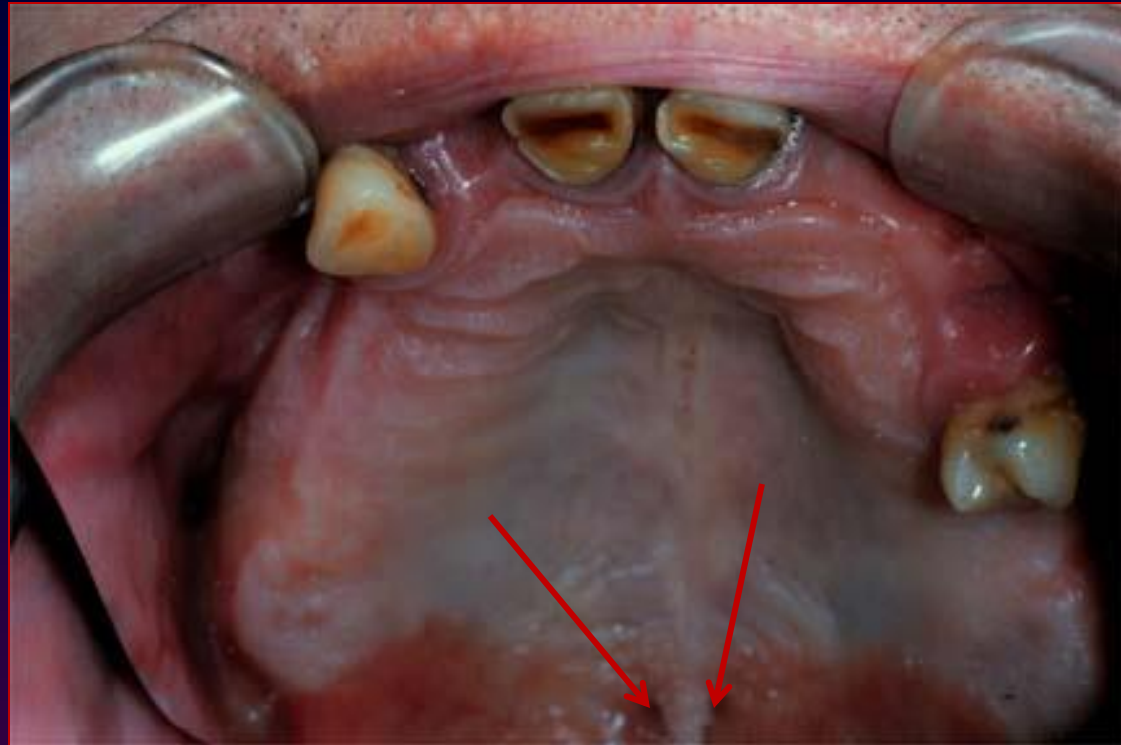


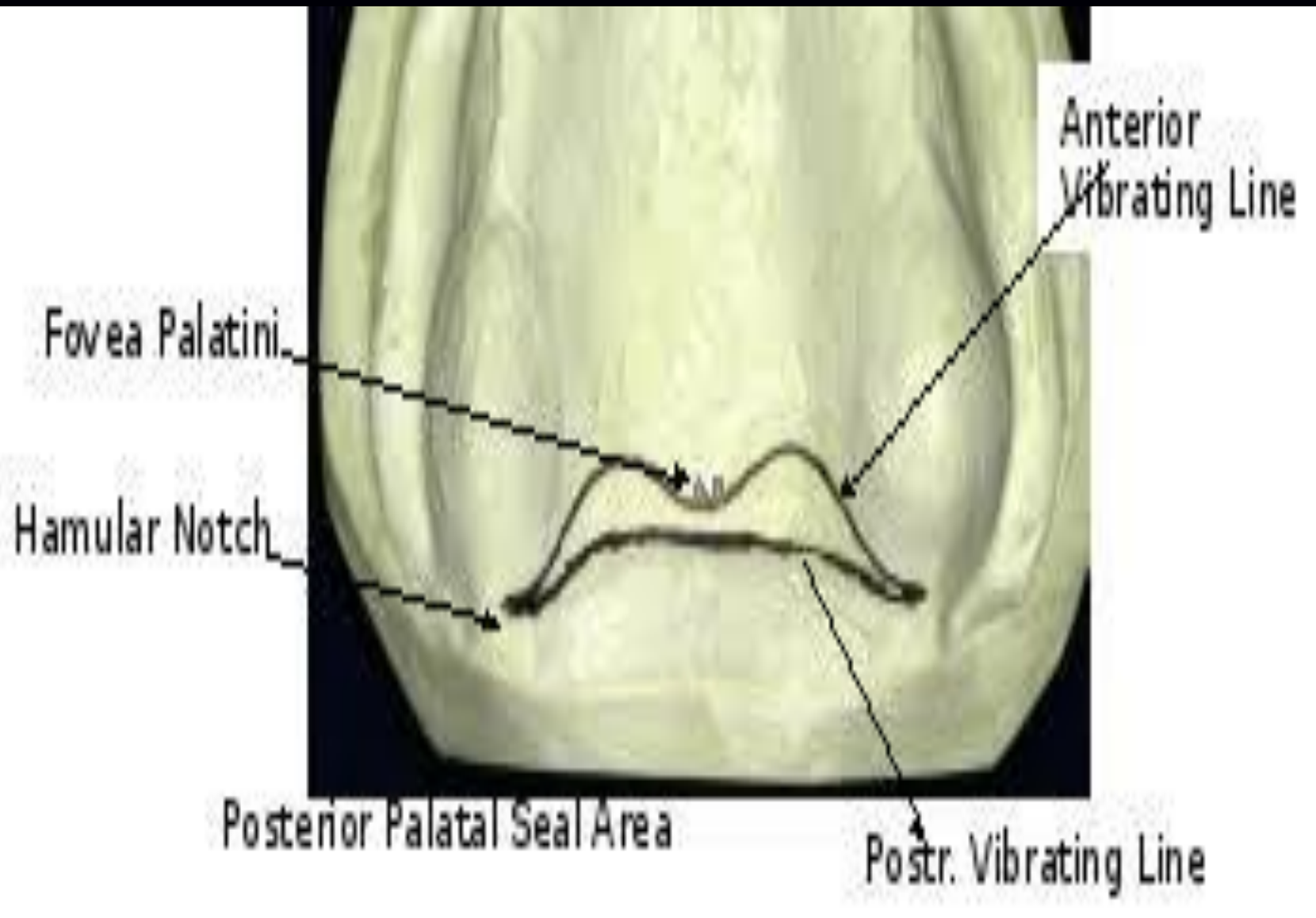
Posterior vibrating lines



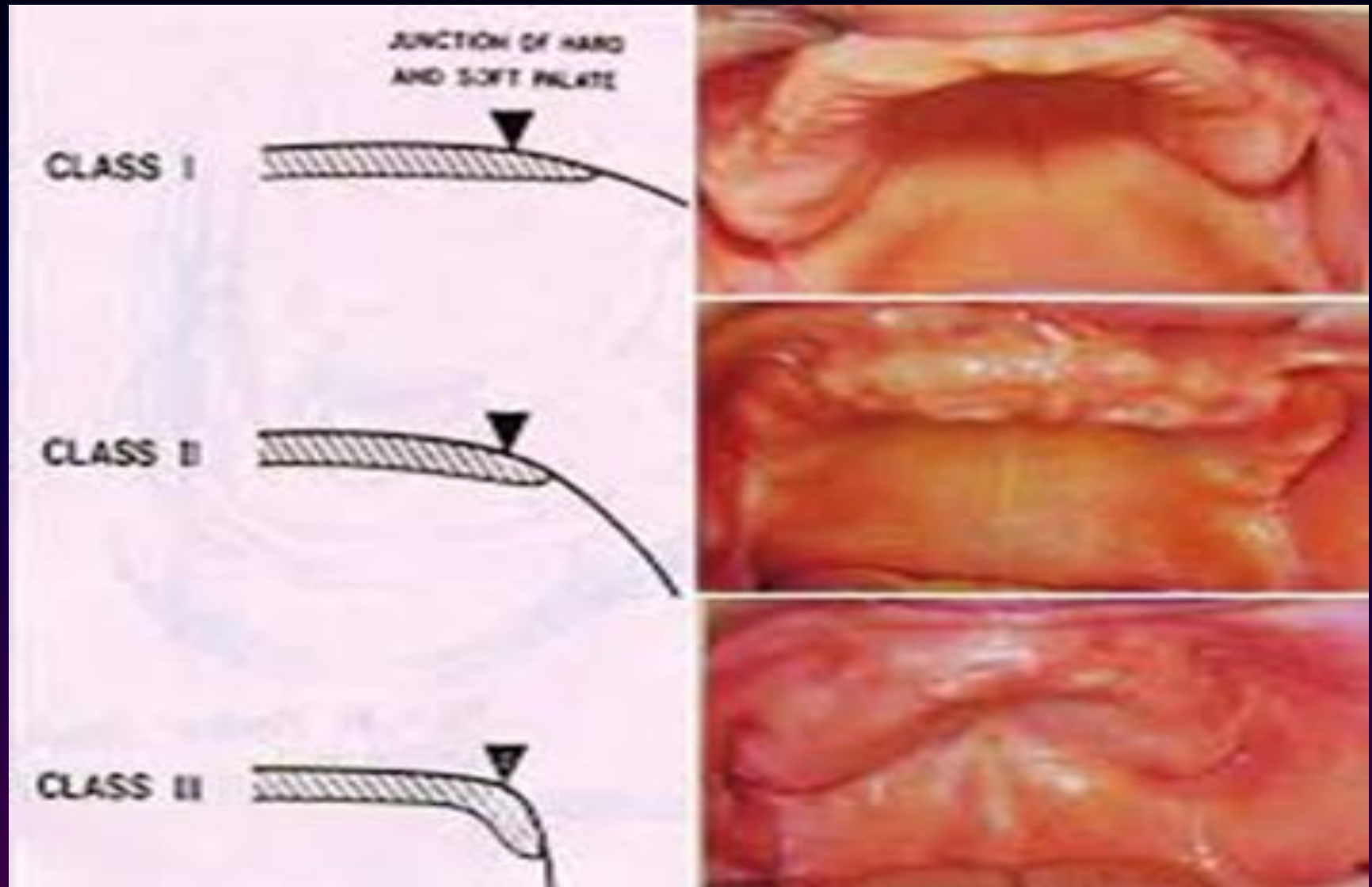
Posterior vibrating line.

Fovea palatini

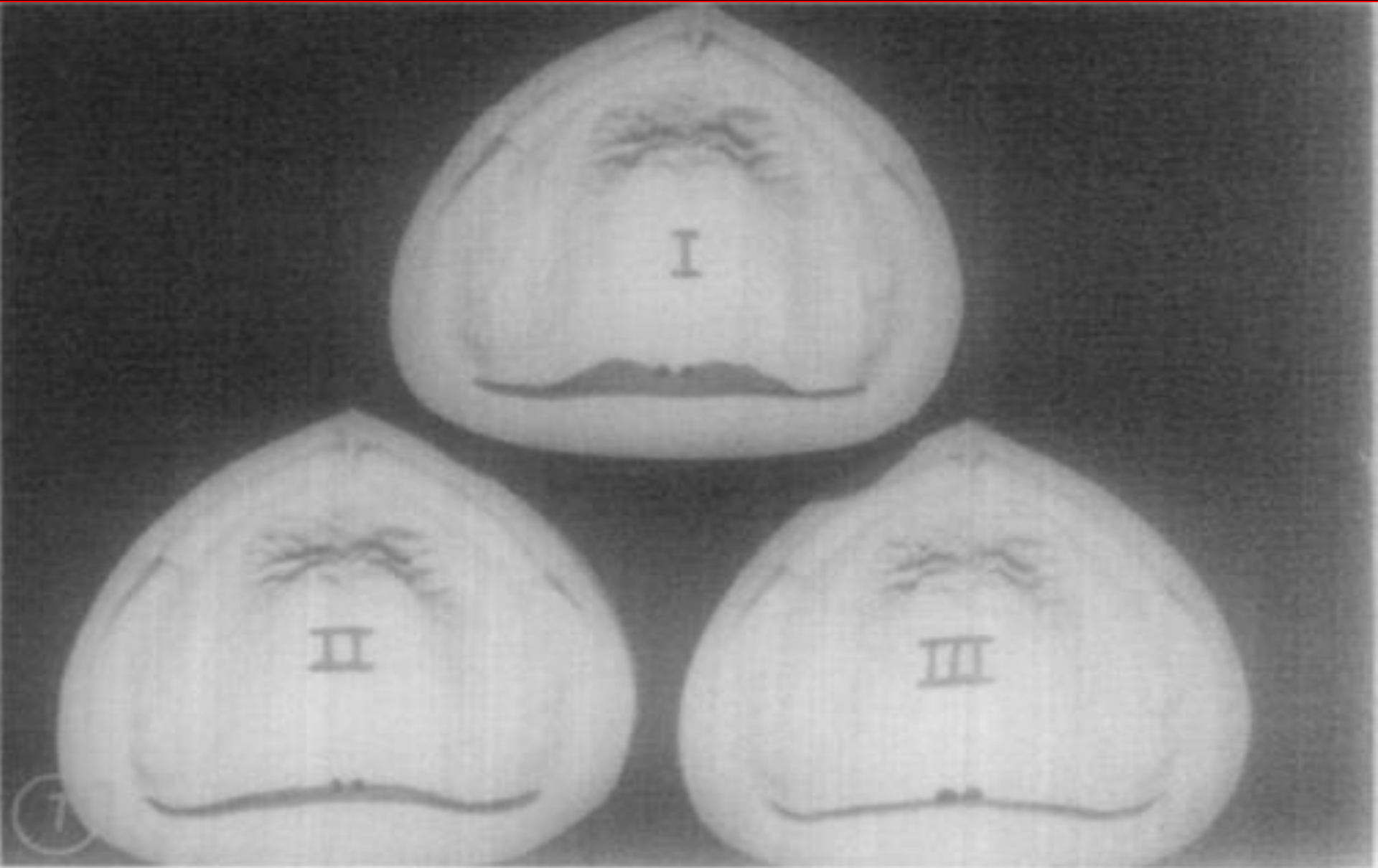




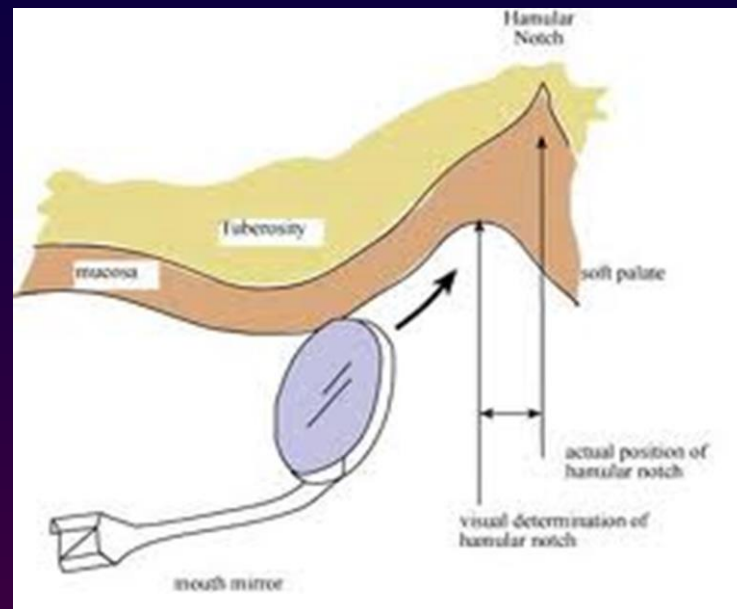
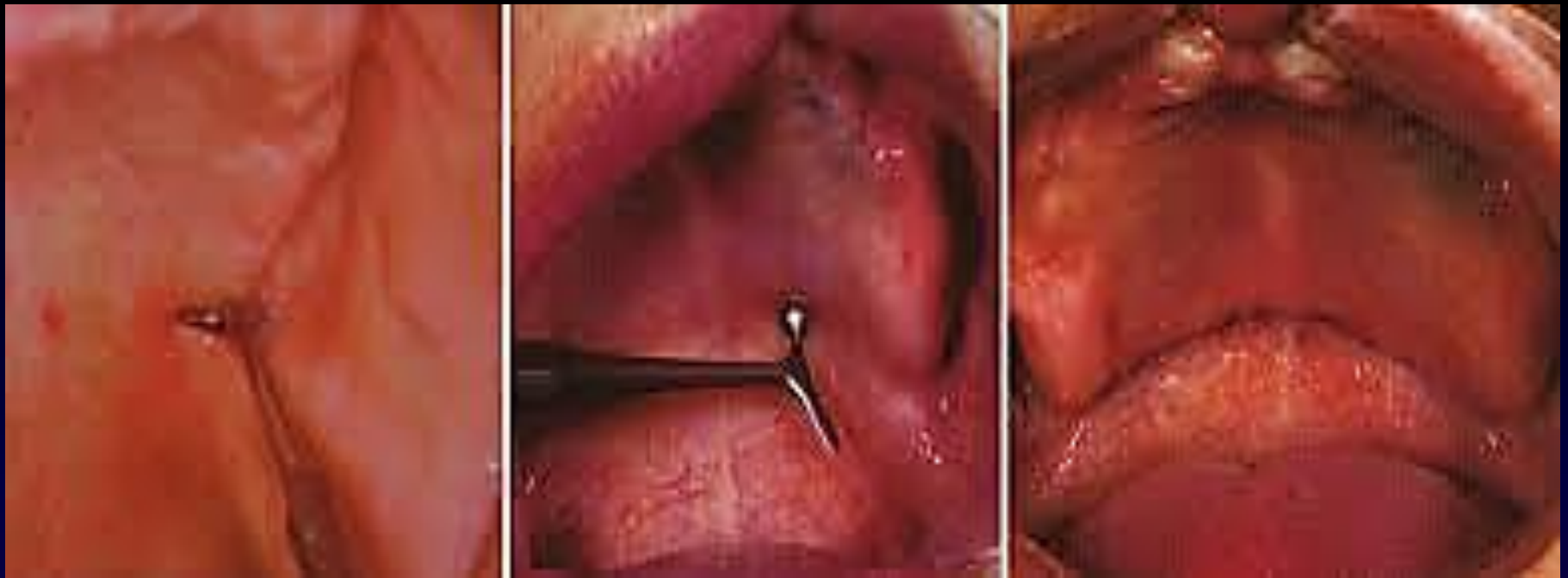Classification of Soft Palates; (House classification)


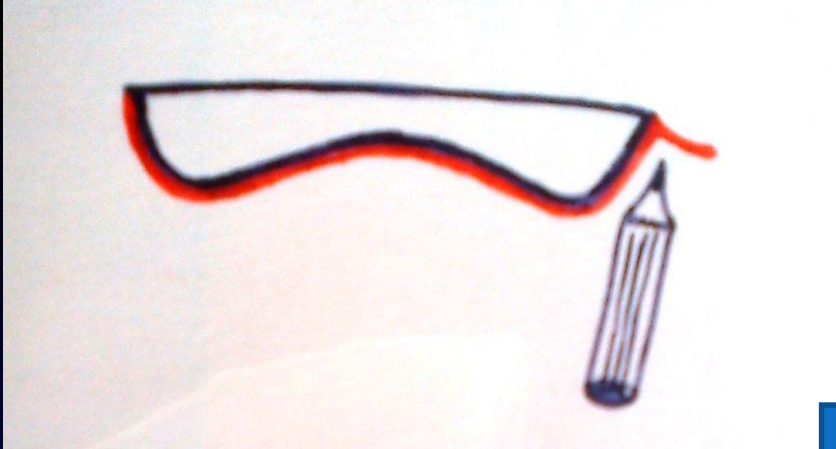


Designs of the posterior palatal seal



CONVENTIONAL APPROACH

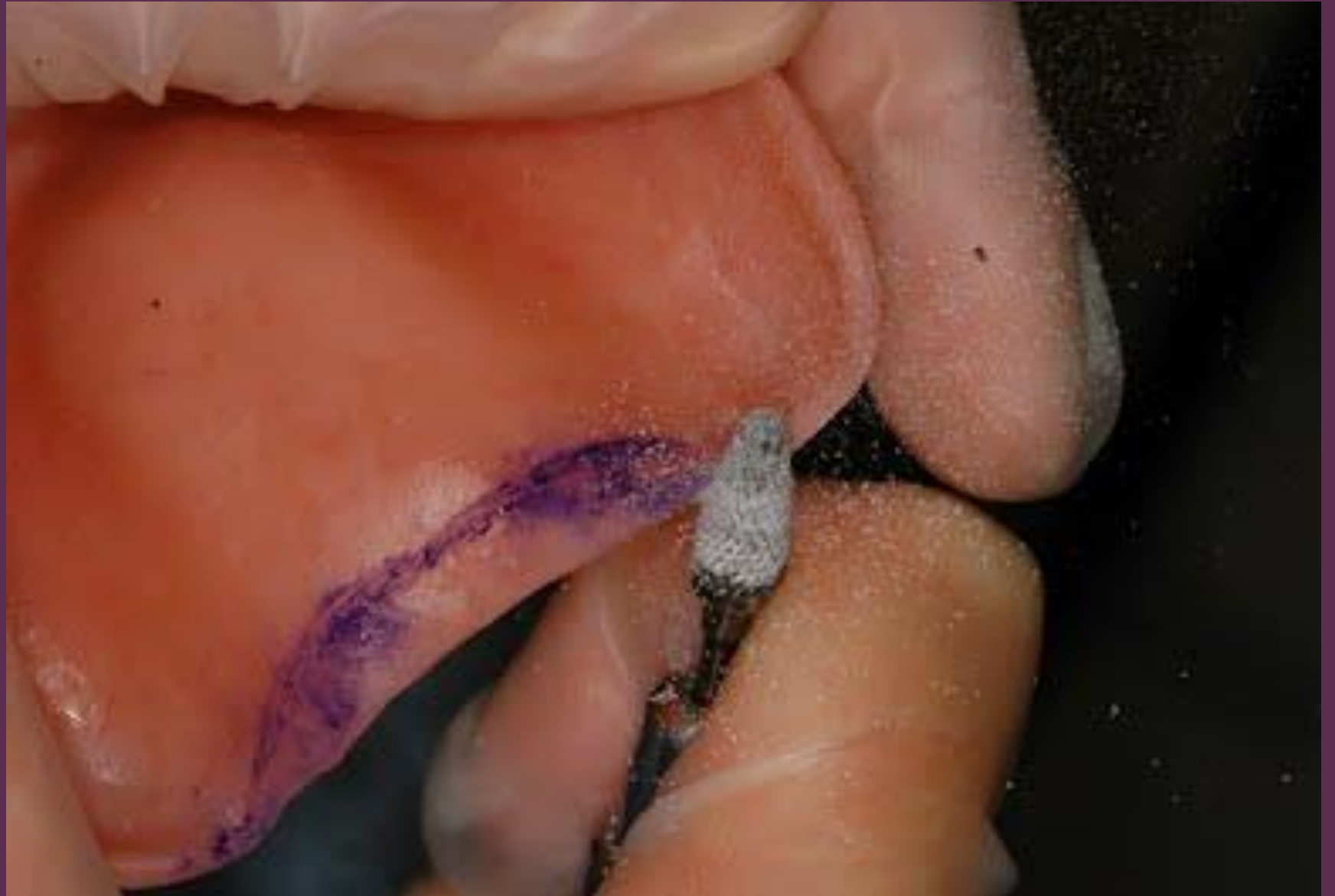

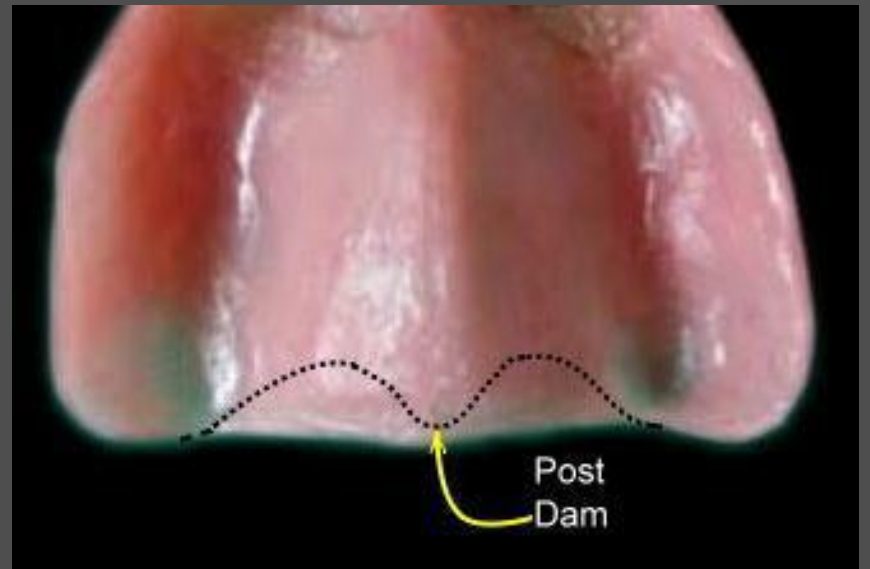

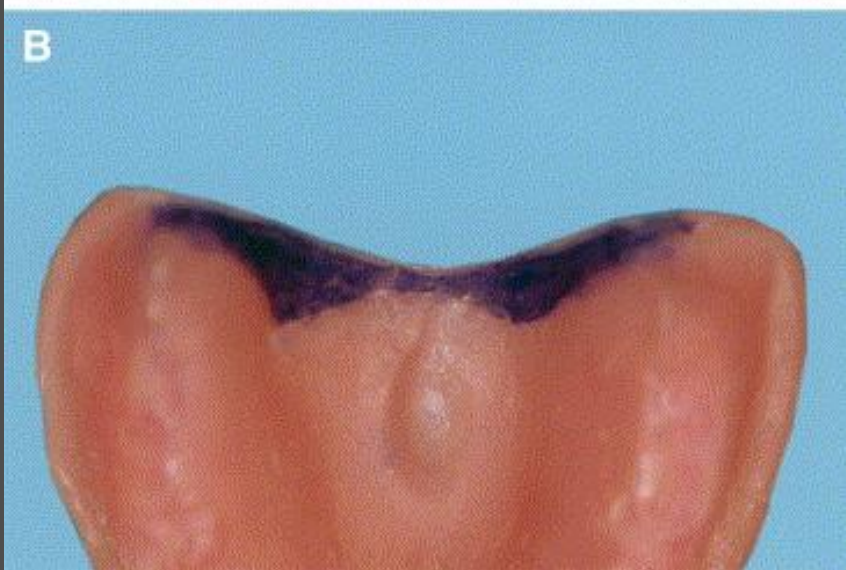
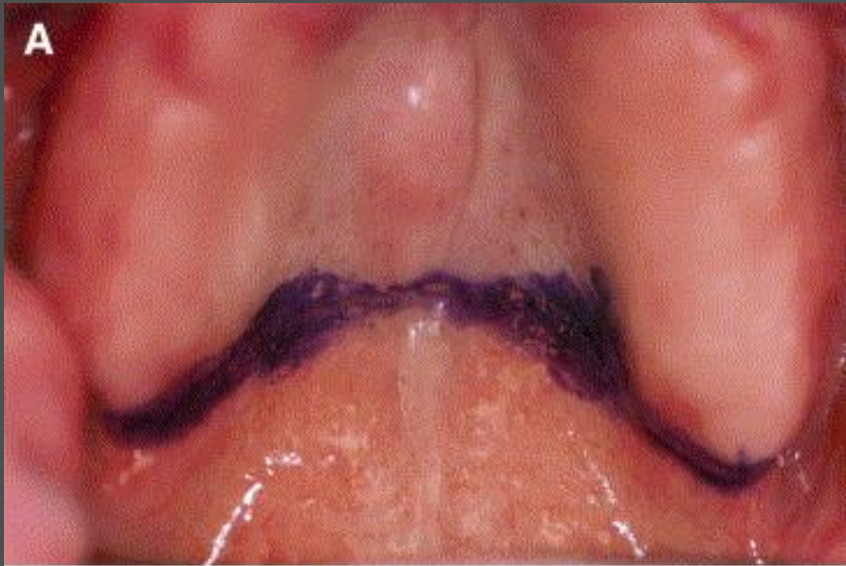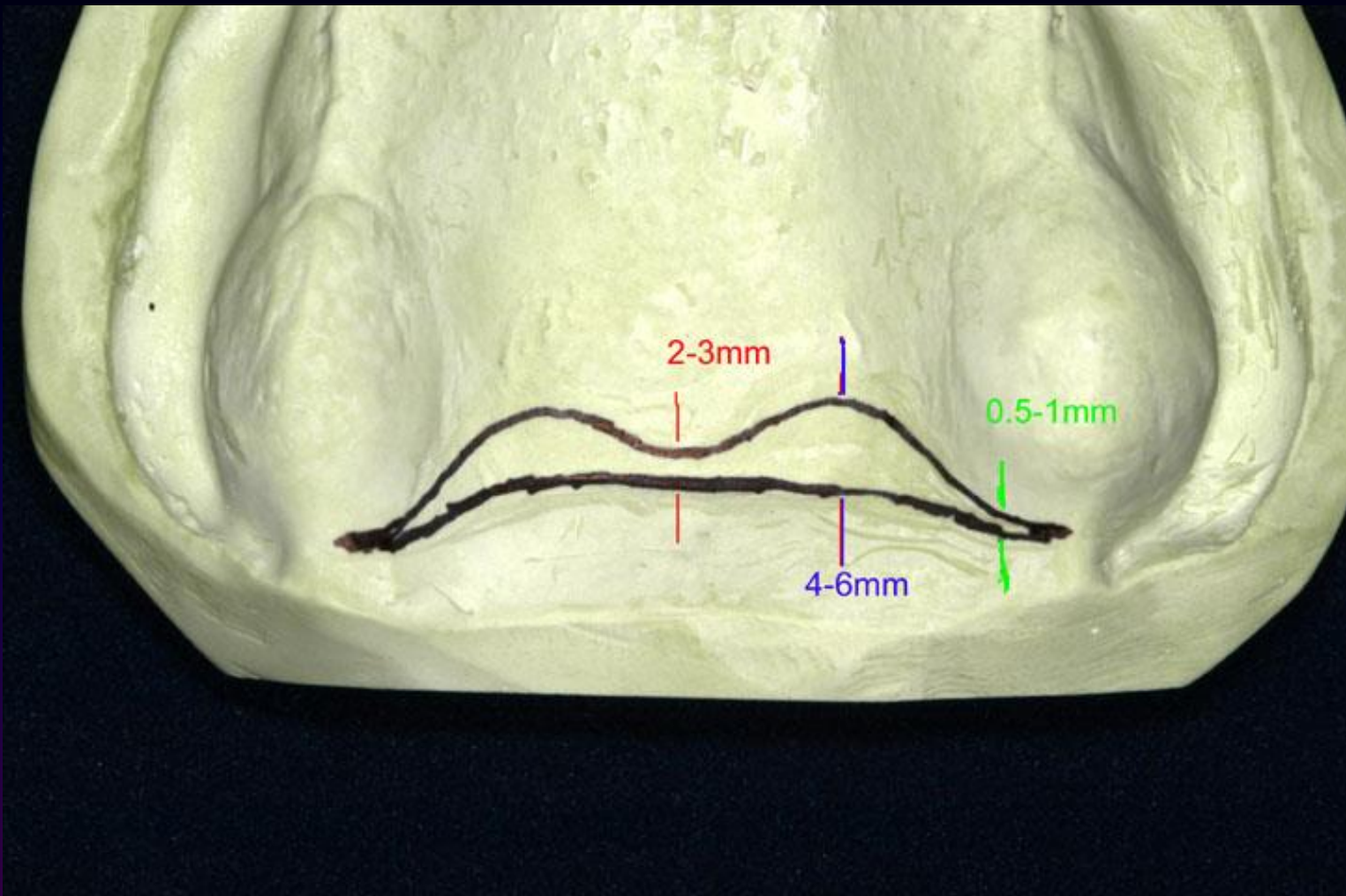
The hamular notch is marked using indelible pencil



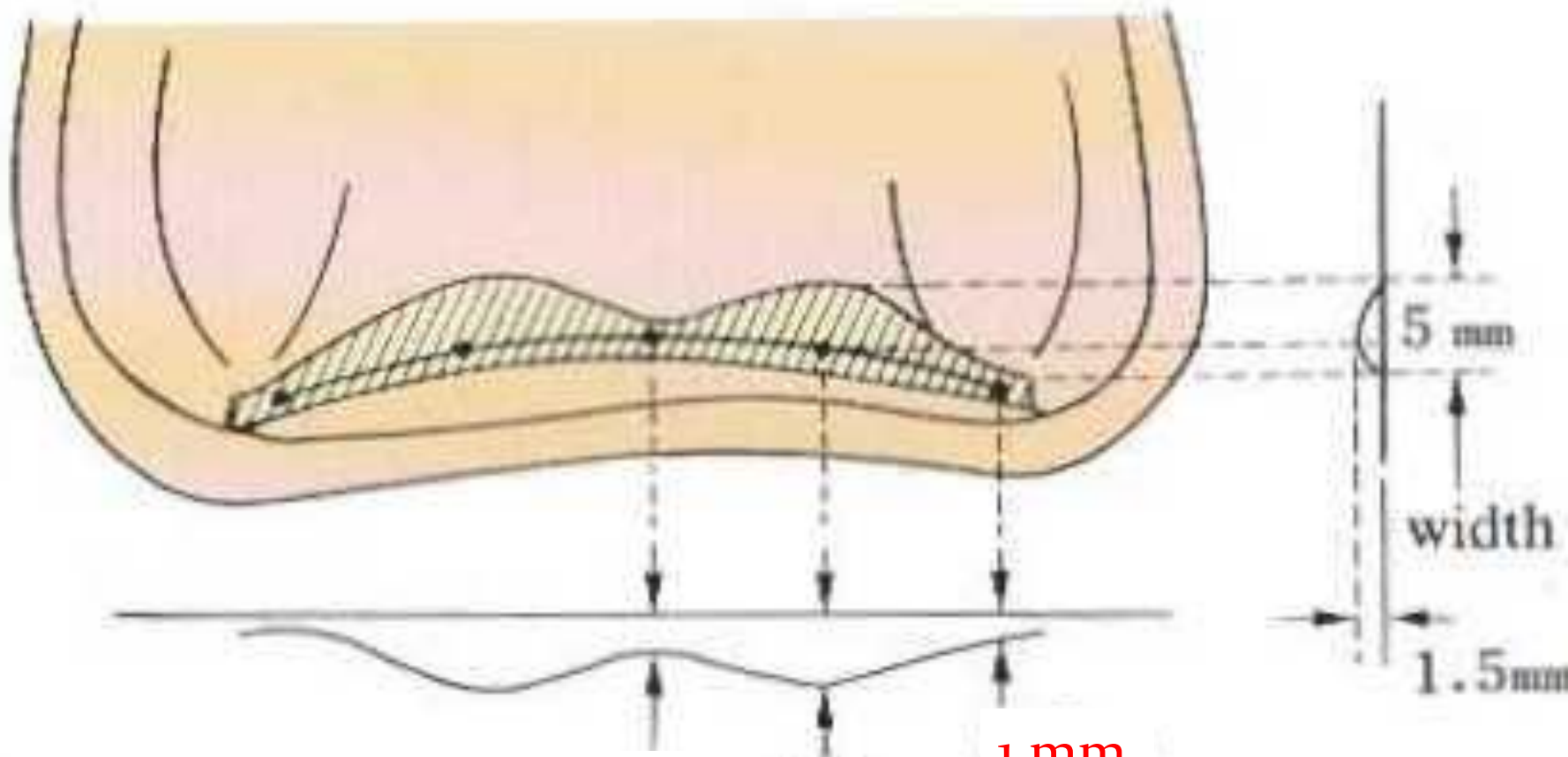
The posterior vibrating line is marked between the movable and immovable soft palate, using an indelible pencil by asking the patient to say “Ah” in a non-vigorous manner.











0.5 mm 1.5 mm

1 mm

depth

muhadharaty.com



A.



B.

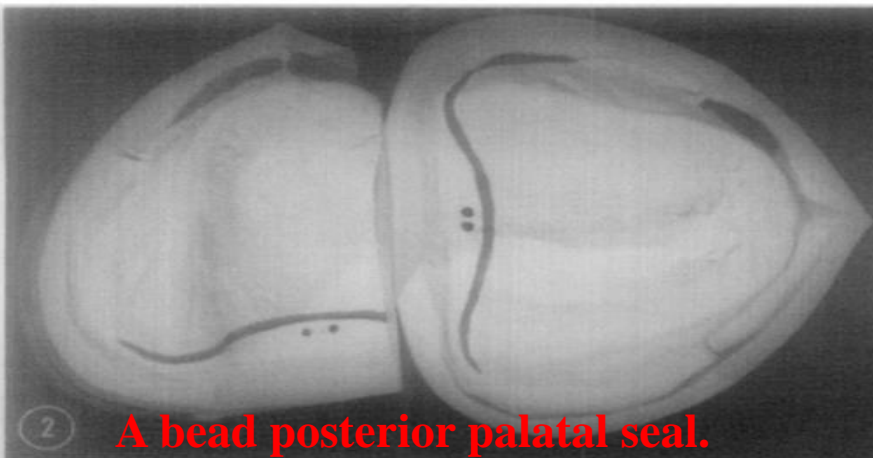


C.

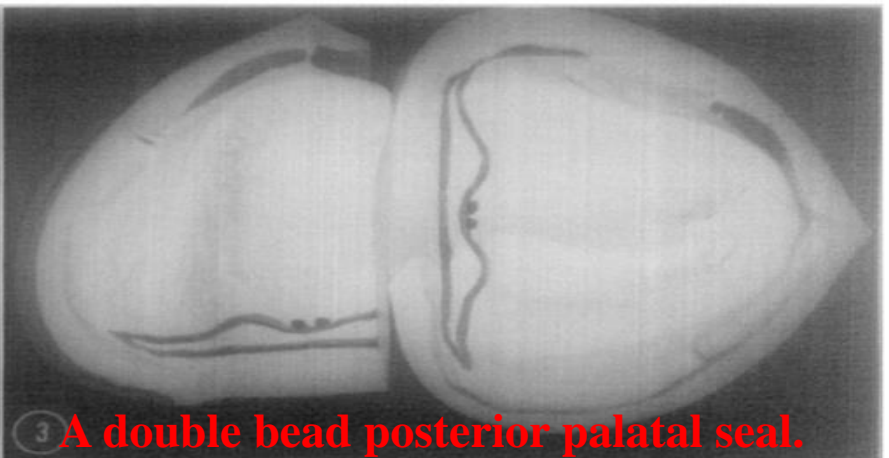


D.

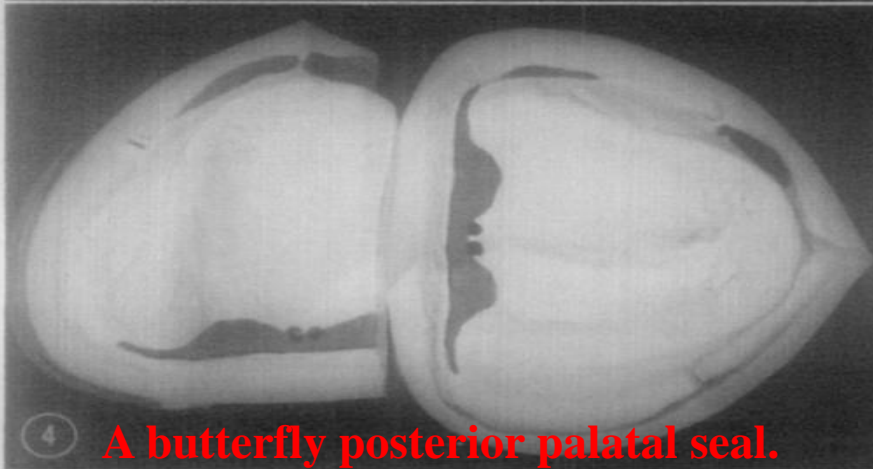
Fig. Cross-sectional views of various posterior palatal seals: (A) bead, (B) double bead, (C) butterfly, and (D) butterfly with bead.



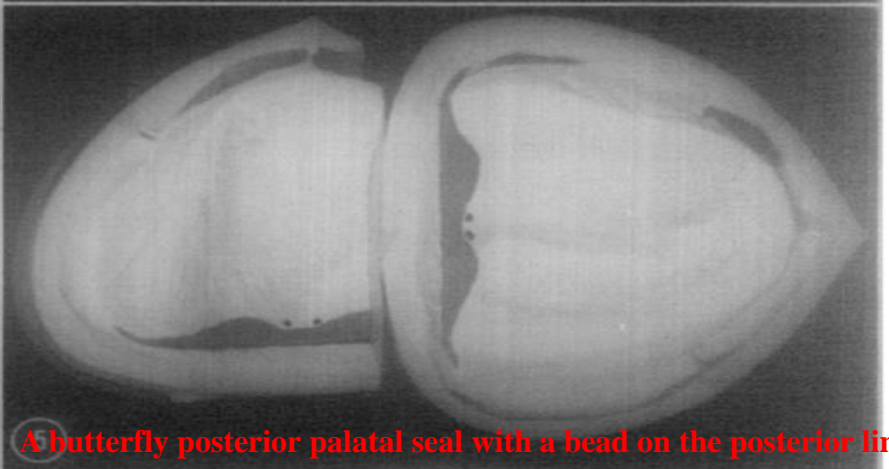
2 A bead posterior palatal seal.



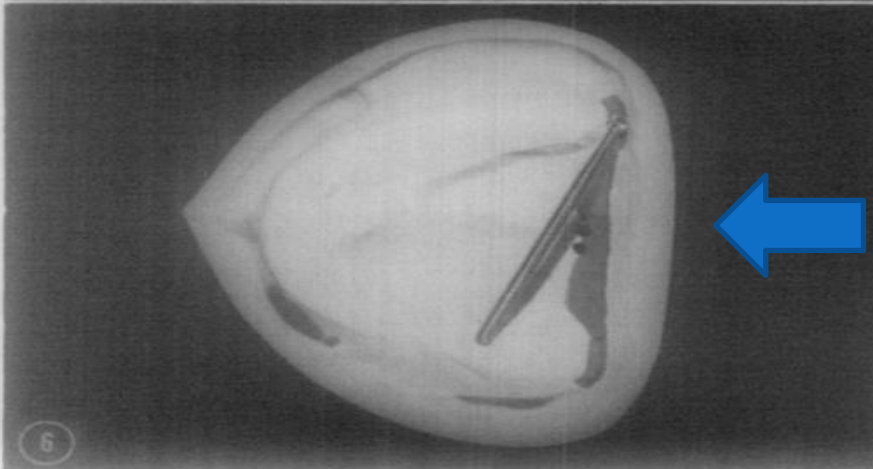
3 A double bead posterior palatal seal.



4 A butterfly posterior palatal seal.

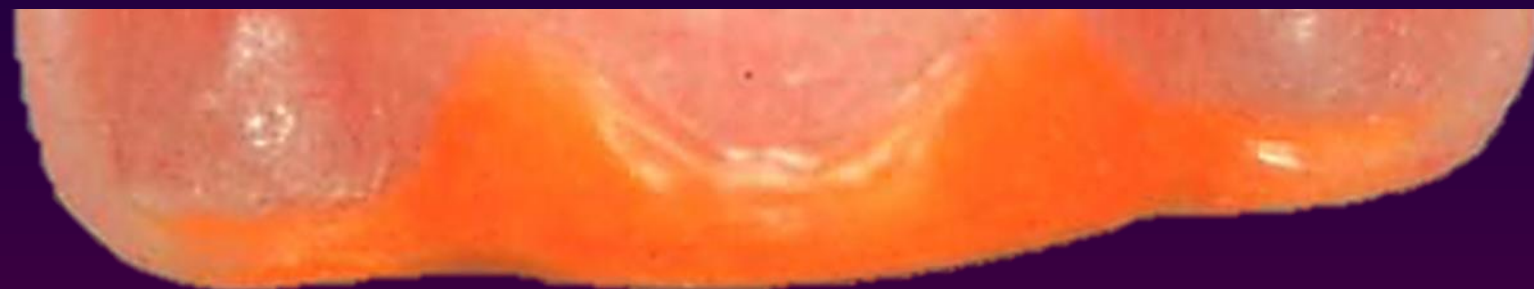
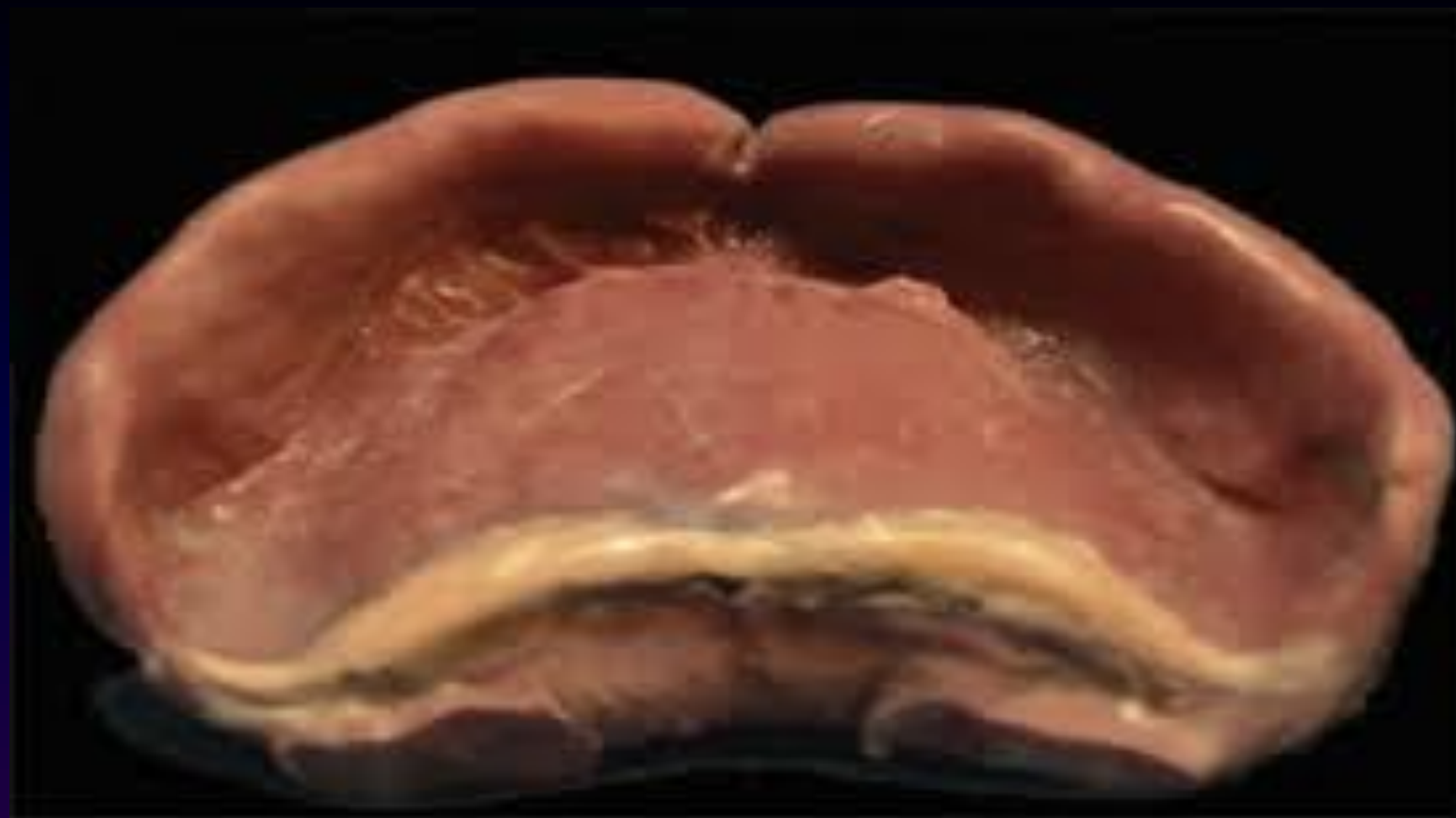
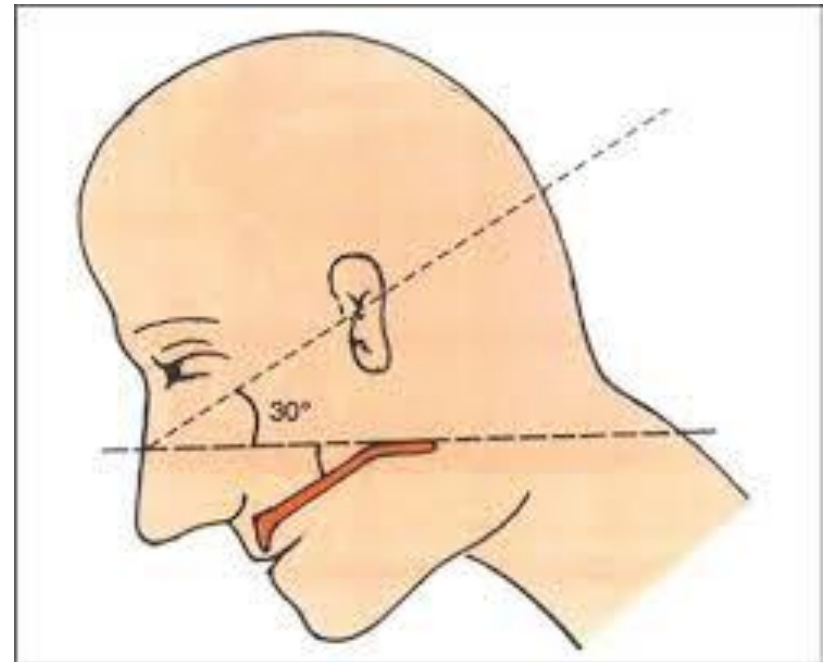
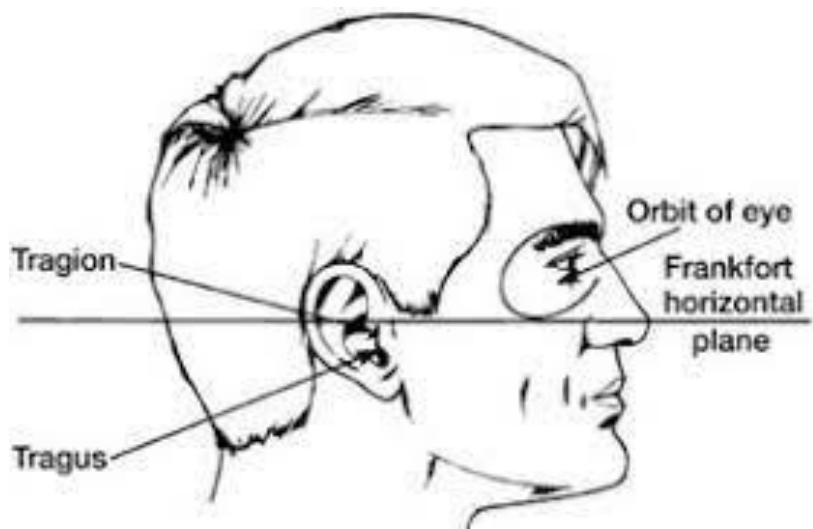
5 A butterfly posterior palatal seal with a bead on the posterior limit.



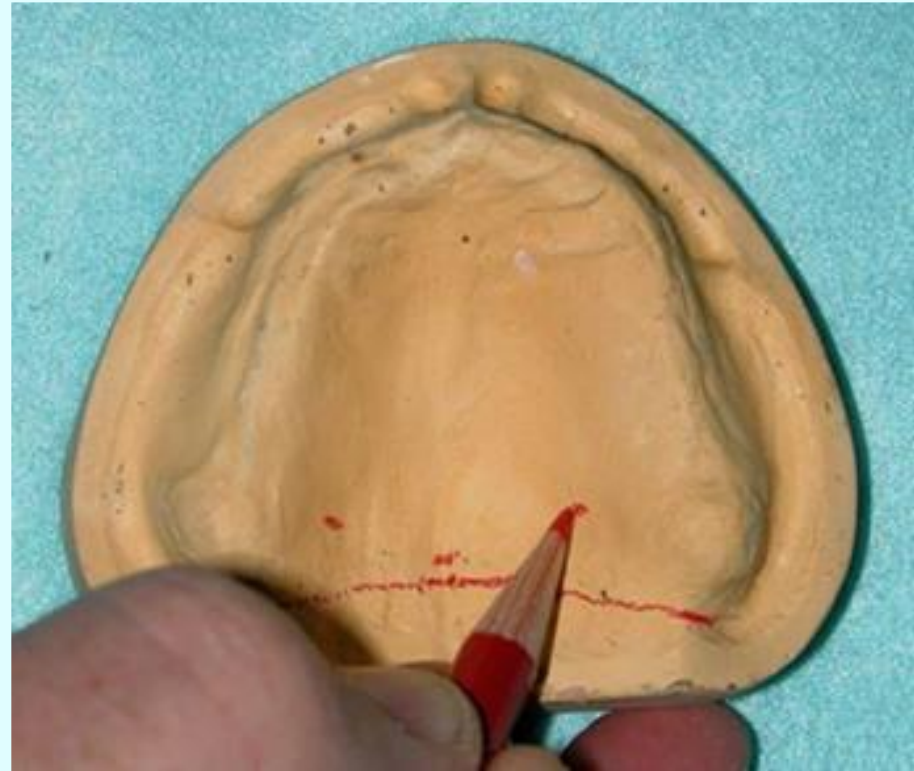
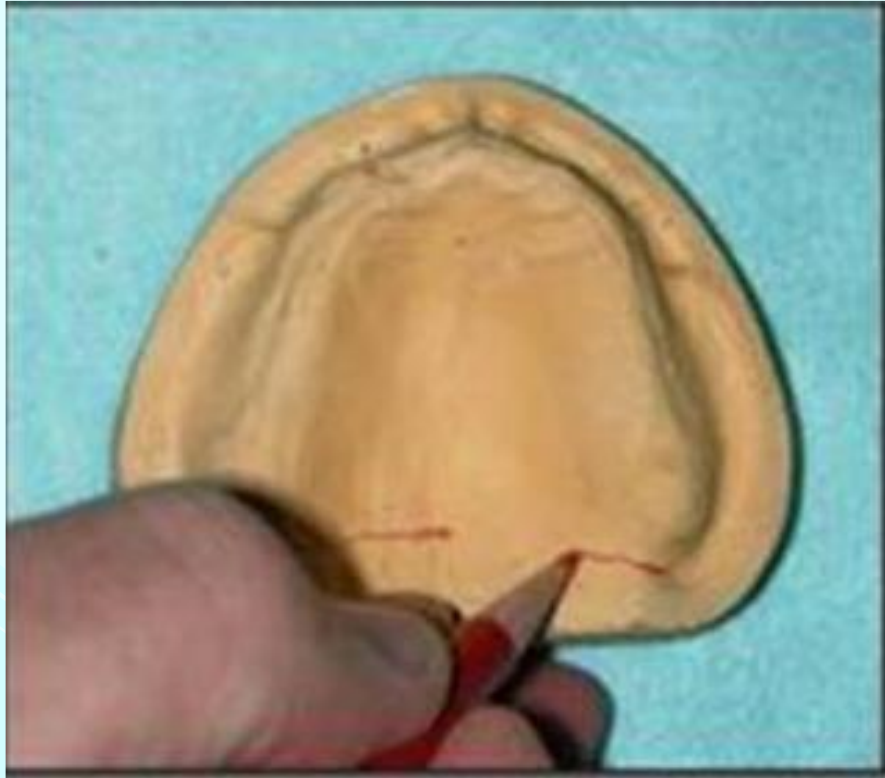6

A butterfly posterior palatal seal with the hamular notch area cut to half the depth of a #9 bur.





Arbitrary scraping of master cast:



Errors in recording the posterior palatal seal

Underextension

Overextension

Underpostdamming

Overpostdamming



Thank you