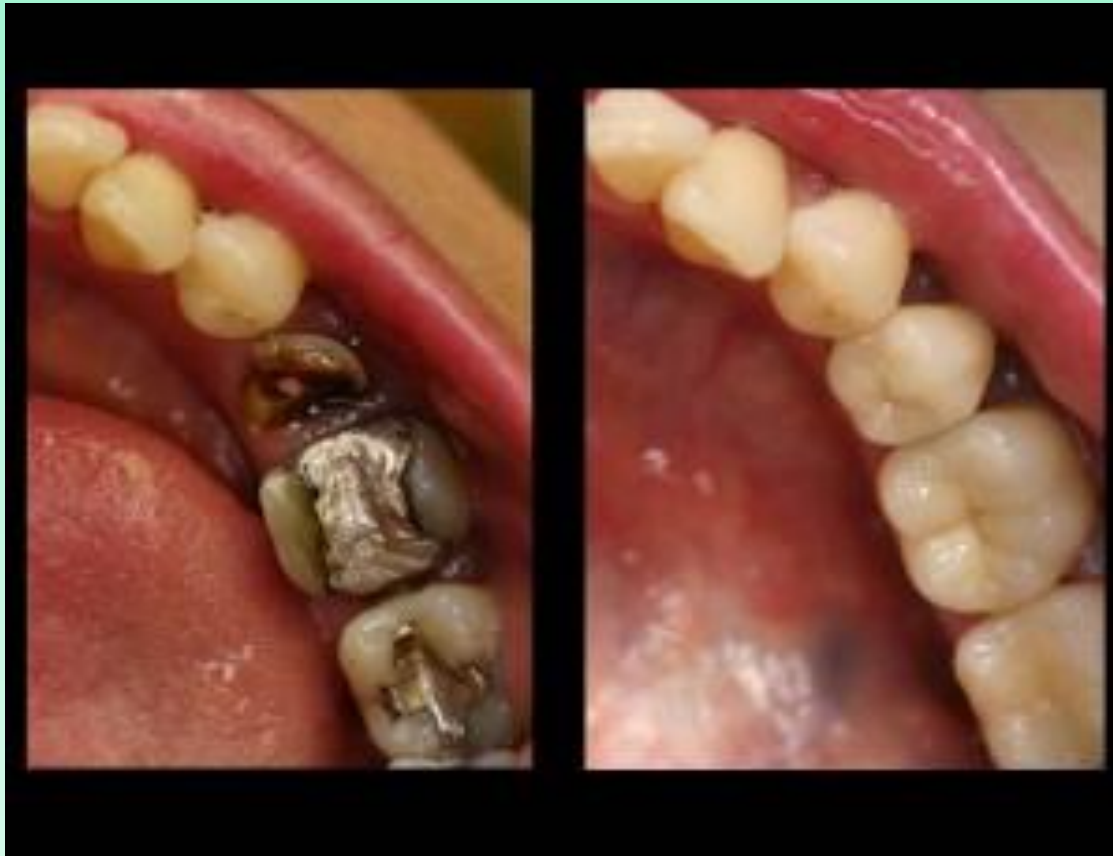

Posterior composite restorations



Advantages

1. Esthetics

2. Conservative tooth structure removal

3. Easier, less complex tooth preparation

4. Economics (compared to crowns and indirect tooth colored restorations)

5. Bonding benefits

- Decreased microleakage
- Decreased recurrent caries
- Decreased postoperative sensitivity
- Increased retention
- Increased strength of remaining tooth structure

- Disadvantages

- 1. Material related

- • Greater localized wear
- • Polymerization shrinkage effects
- • Linear coefficient of thermal expansion (LCTE)
- • Biocompatibility of some components unknown

- 2. Require more time to place

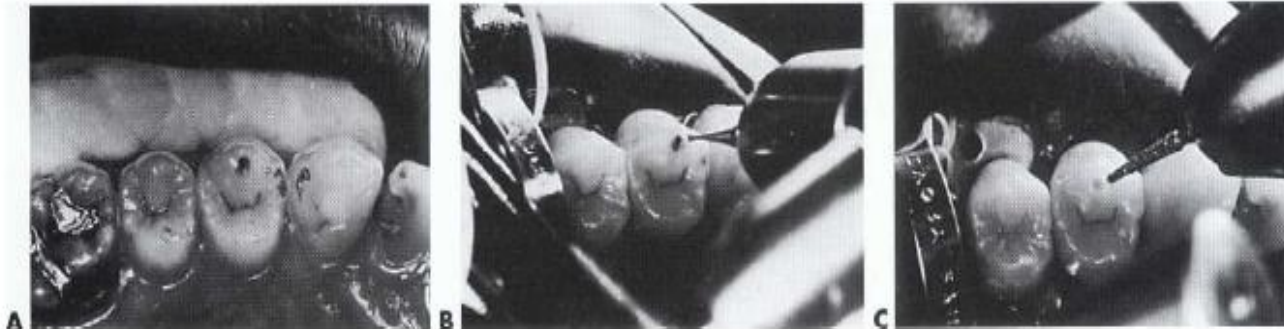- 3. More technique sensitive

- • Etching, priming, adhesive placement
- • Inserting composite
- • Developing proximal contacts
- • Finishing and polishing

- 4. More expensive than amalgam restorations

***CL VI Composite restorations**

- indicated for a small faulty developmental pit located on a cusp tip.
- Usually no anesthesia is required because the fault is entirely in enamel.
- The tooth is isolated with a cotton roll.
- should be as small in diameter and as shallow in depth as possible.
- started with a small, round bur or diamond directed perpendicular to the surface and extend pulpally. the fault is limited to enamel because the enamel in this area is quite thick.
- Complete the preparation using either a flame-shaped or round diamond instrument to roughen the prepared surfaces.



CL I and II Composite restorations

Indications

- 1 Small and moderate restorations, preferably with enamel margins.**
- 2 Most premolar or first molar restorations.**
- 3 A restoration that does not provide all of the occlusal contacts.**
- 4 A restoration that does not have heavy occlusal contacts.**
- 5 A restoration that can be appropriately isolated during the procedure.**
- 6 Some restorations that may serve as foundations for crowns.**
- 7 Some very large restorations that are used to strengthen remaining weakened tooth structure.**

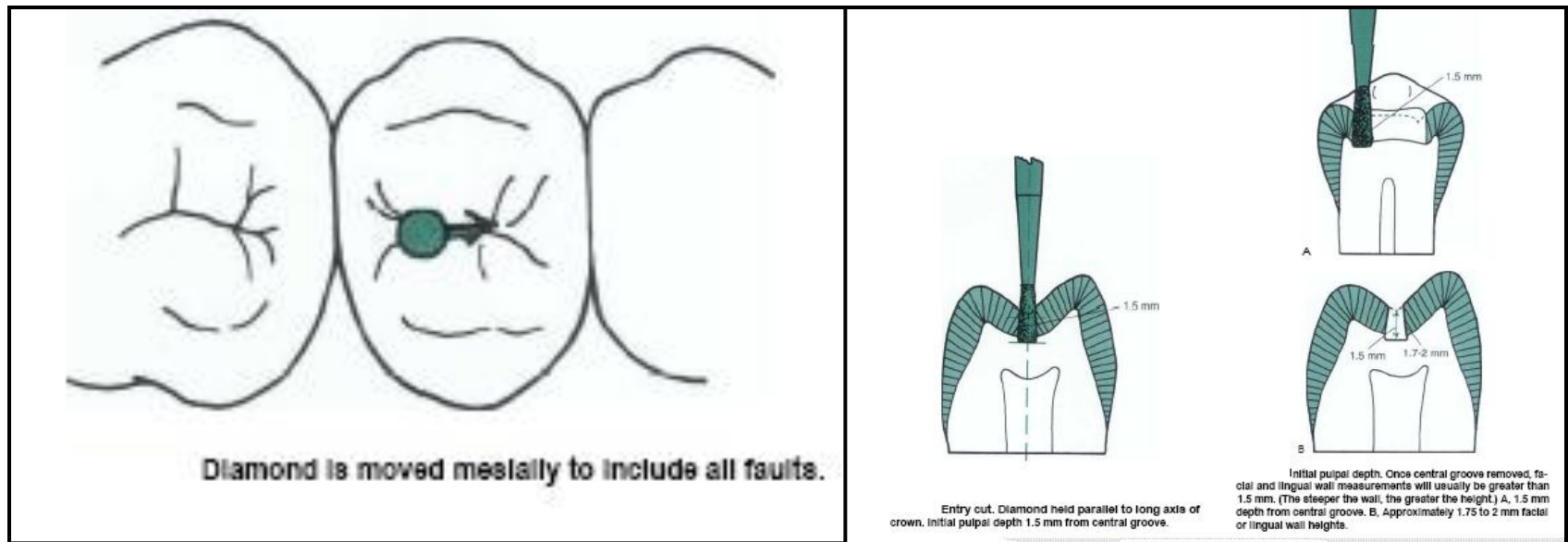
CL I and II Composite restorations

Contraindications

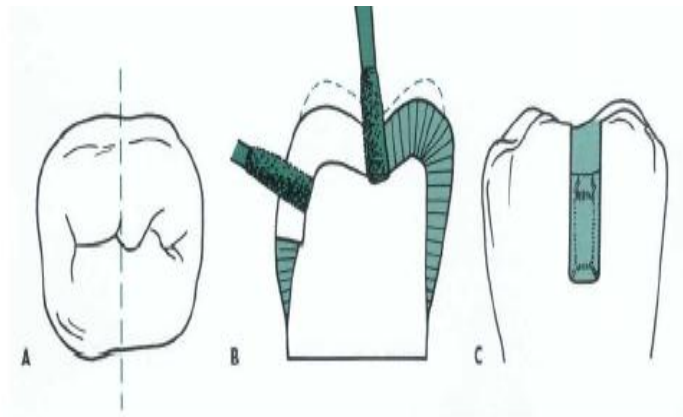
1. When the operating site cannot be appropriately isolated.
2. With heavy occlusal stresses.
3. With all the occlusal contacts only on composite.

Conventional Class I Tooth Preparation.

For the large Class I composite tooth preparation. This would be most necessary for large preparations or restorations subjected to heavy occlusal forces. the more boxlike preparation design may be preferred, resulting in greater retention and resistance to fracture. This form is generated by any flat tipped bur or diamond. However,

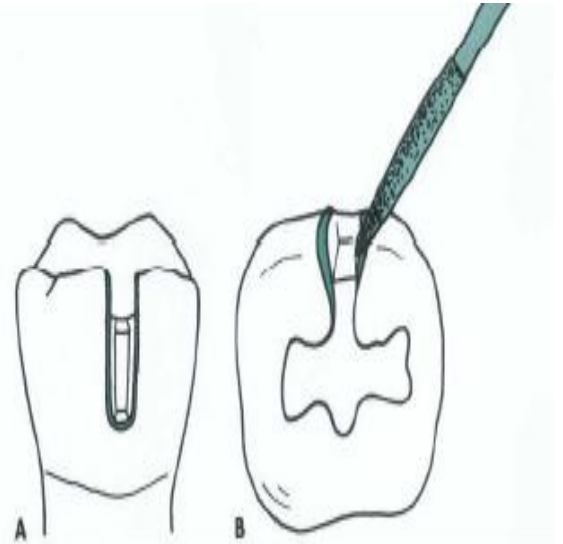


➤The outline form extended to sound tooth structure. Occlusal margin does not have a beveled, because it may result in thin composite in areas of heavy occlusal contact.



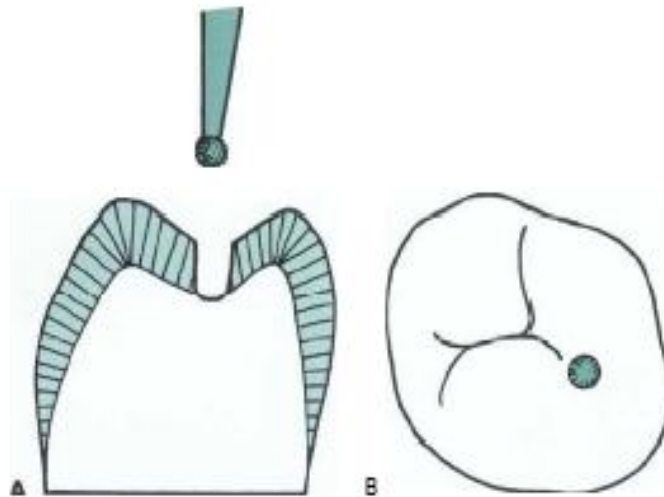
Groove extension. A, Cross-section through facial and lingual groove area. B, Extension through cusp ridge at 1.5 mm initial pulpal depth; facial wall depth is 0.2 mm inside the DEJ. C, Facial view.

Beveling a facial groove extension. Coarse diamond creates a 0.5-mm bevel width at a 45-degree angle. A, Facial view. B, Occlusal view.



Modified Class I Tooth Preparation

- These preparations have a scooped-out appearance.
- Prepared with a small round or inverted cone diamond.
- The initial pulpal depth is still 1.5 mm and 0.2 mm inside the DEJ, but may not be uniform (i.e., the pulpal floor is not necessarily flat throughout its length). If a round diamond is used, the resulting cavosurface margin angle may be more flared than if an inverted cone diamond was used.

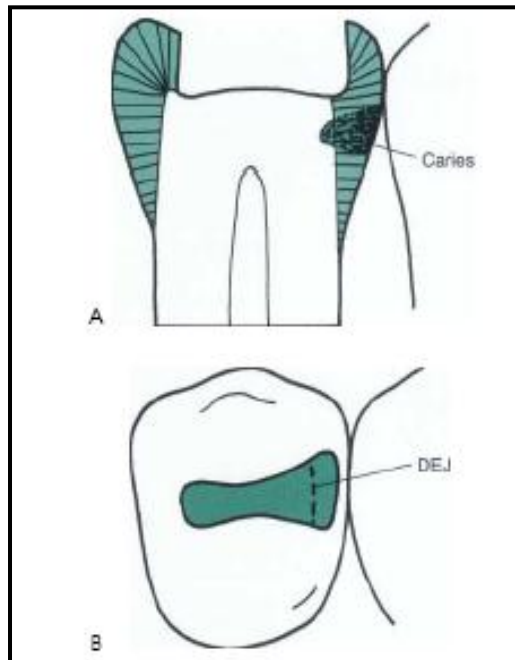


Conventional Class II Tooth Preparation

Care is taken to preserve cuspal areas as much as possible.

➤At the same time, the diamond extends through the marginal ridge within 0.5 mm to exposes the proximal DEJ and also protects the adjacent tooth.

➤The occlusal walls generally converge occlusally because of the inverted shape of the diamond. This provide the strongest enamel. Also the occlusal walls and pulpal floor are left in a roughened state because of the diamond instrument. This increases the surface area for bonding.

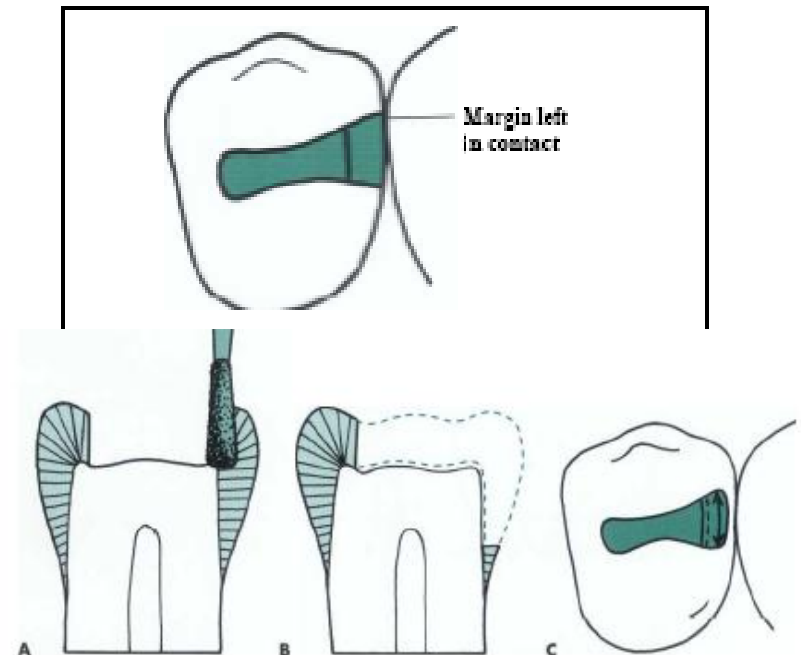


Proximal Box.

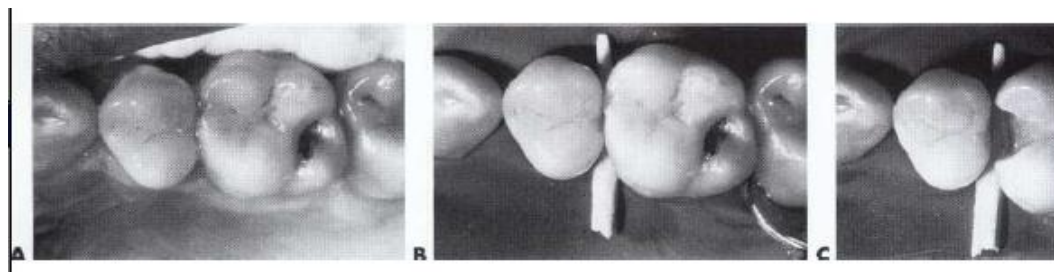
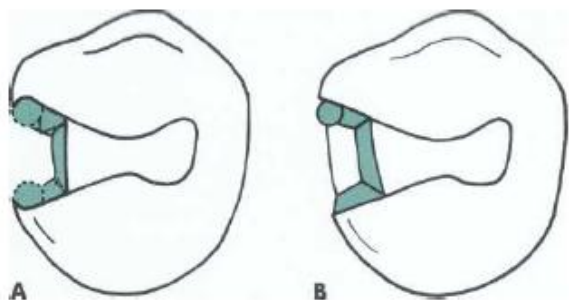
The facial, lingual, and gingival extension of the proximal box depends on two factors:-

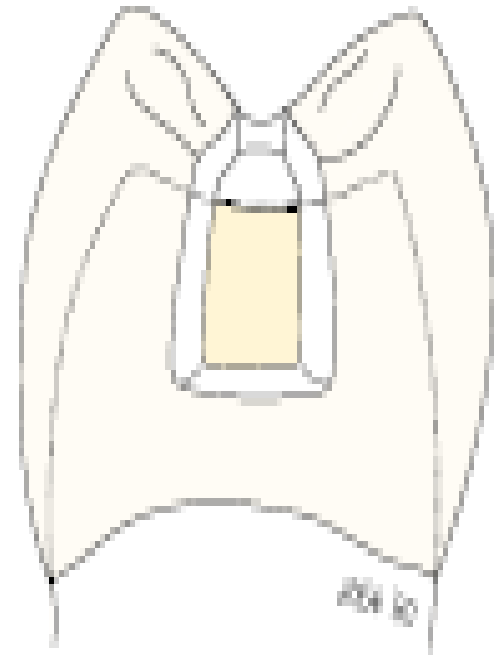
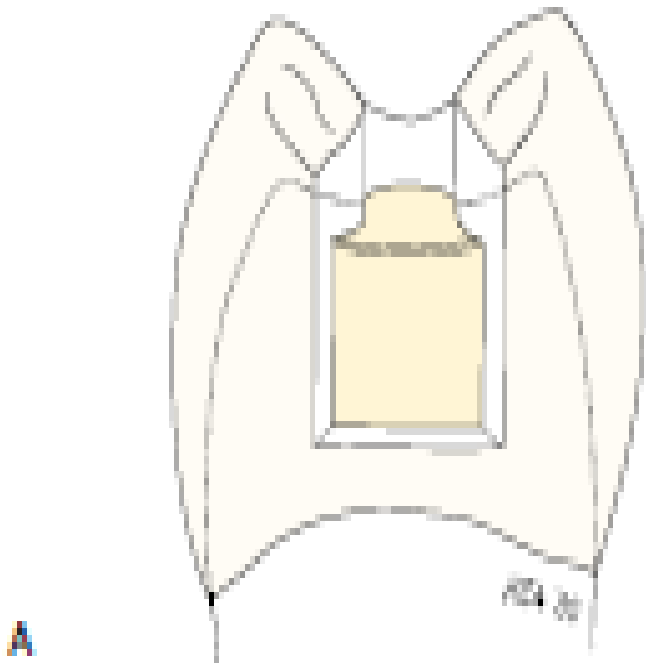
- 1- The extent of the carious lesion.
- 2- The amount of old restorative material.

It is not required to extend the proximal box beyond contact with the adjacent tooth (i.e., provide clearance with the adjacent tooth).

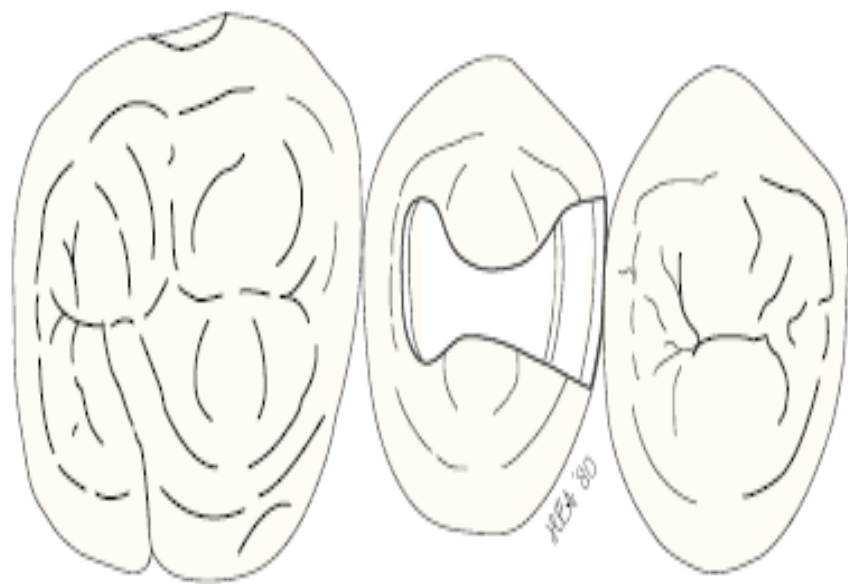

- The facial and lingual occlusal walls will be convergent occlusally, adding to retention form. No bevels are placed on the cavosurface margins, especially the occlusal margins.
- Bevels can be placed on the proximal facial and lingual margins if the proximal box is already wide faciolingually, such bevels will increase the surface area and expose enamel rod ends and improve retention.
- In case of extensive caries, many areas of the enamel are unsupported by dentin, but if enamel is not friable; enamel is not removed.
- Early wedging with a short segment of a wooden toothpick initiates tooth separation, which is essential for establishing a tight proximal contact.

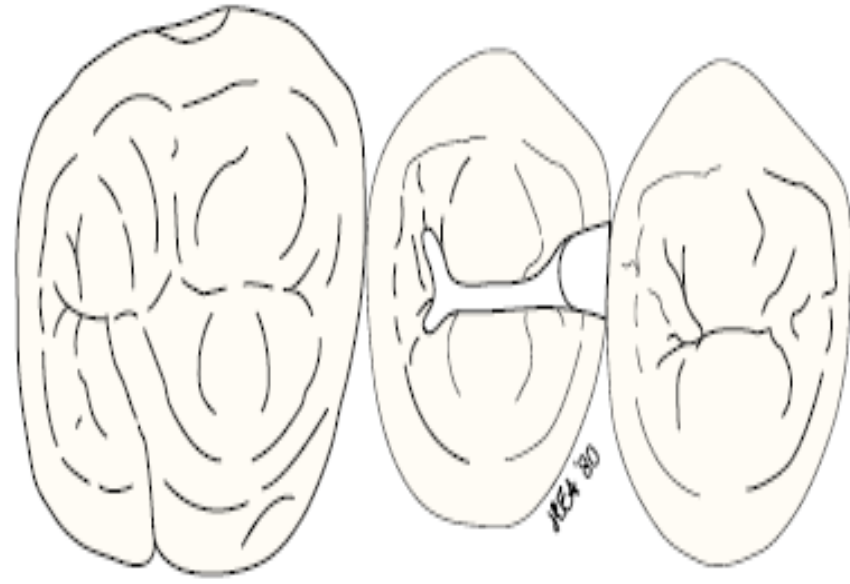




The proximal box outline: *A*, for an ideal Class II amalgam preparation, and *B*, for an ideal Class II composite preparation for occlusal and proximal caries.



A

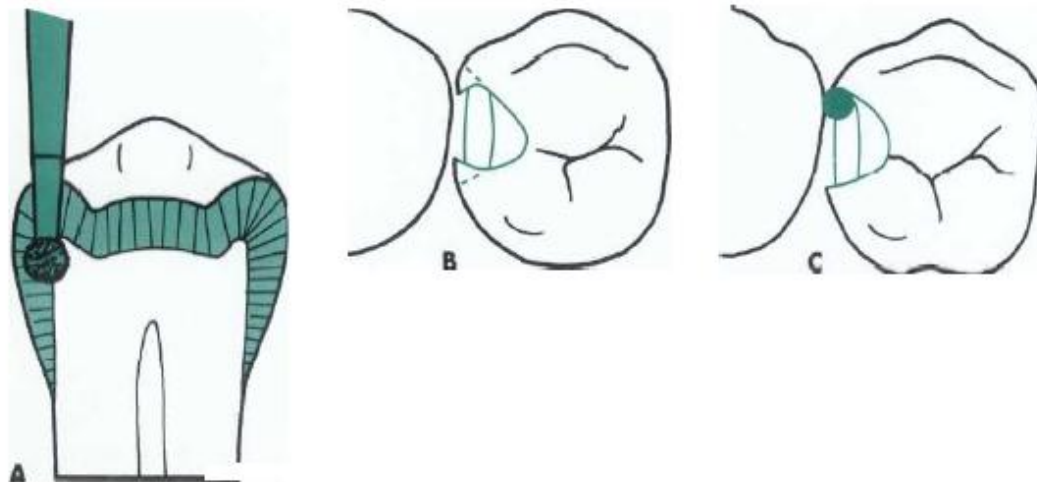


B

Schematic occlusal view of typical Class II preparations: *A*, for amalgam, and *B*, composite restoration of a tooth with occlusal and proximal caries.

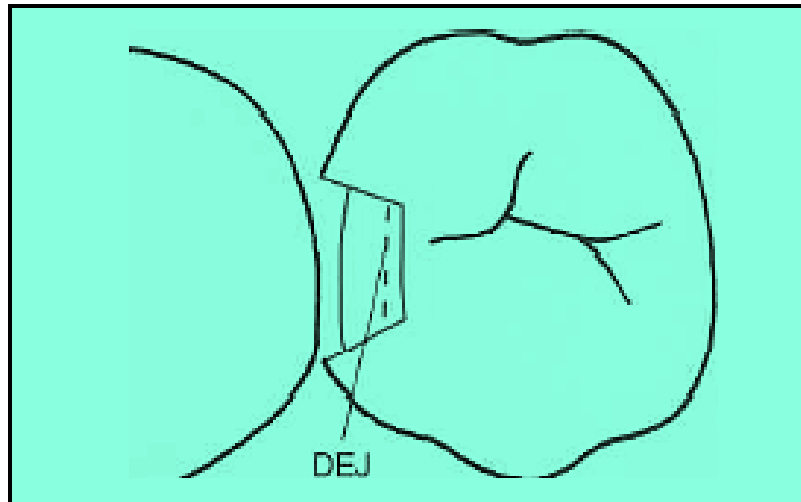
Modified Class II Tooth Preparation:

- For small, initial restorations.
- A small round or inverted cone diamond may be used to scoop out the carious or faulty material (**scooped appearance**) on both the occlusal and proximal portions.
- The pulpal and axial depths are limited to the depth of the lesion and not necessarily to be uniform.
- The proximal extensions are limited to the extent of the lesion.



Another modified design is the **box-only tooth preparation**.

- ❖ This design is indicated when only the proximal surface is faulty, with no lesions on the occlusal surface.
- ❖ prepared with either an inverted cone or round diamond, held parallel to the long axis of the tooth crown. The axial depth is prepared 0.2 mm inside the DEJ.
- ❖ The shape of the box is dependent on which diamond is used, the boxlike shape with the inverted cone, and the scooped shape with the round diamond. The facial, lingual, and gingival extensions are limited to the fault or caries. No beveling or secondary retention is indicated.

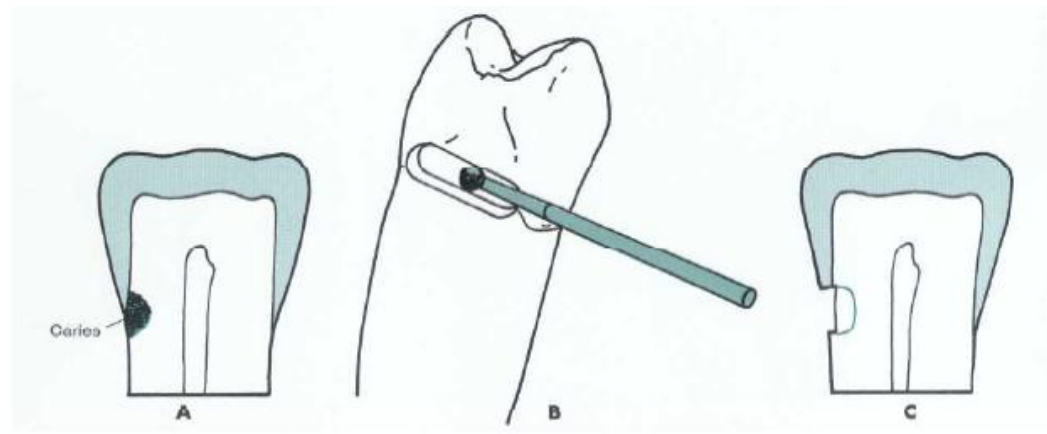


- A third modified design is the **facial or lingual slot preparation**.

•

Here a lesion is detected on the proximal surface and the access to the lesion can be obtained from either a facial or lingual direction not through the marginal ridge in a gingival direction. small round diamond is used to gain access to the lesion. The diamond is oriented at the correct occlusal-gingival position and the entry is made with the diamond as close to the adjacent tooth as possible, thus preserving as much of the facial or lingual surface as possible. The preparation is extended occlusally, facially, and gingivally enough to remove the lesion.

The axial depth is 0.2 mm inside the DEJ. This preparation is similar to a Class III preparation for an anterior tooth.

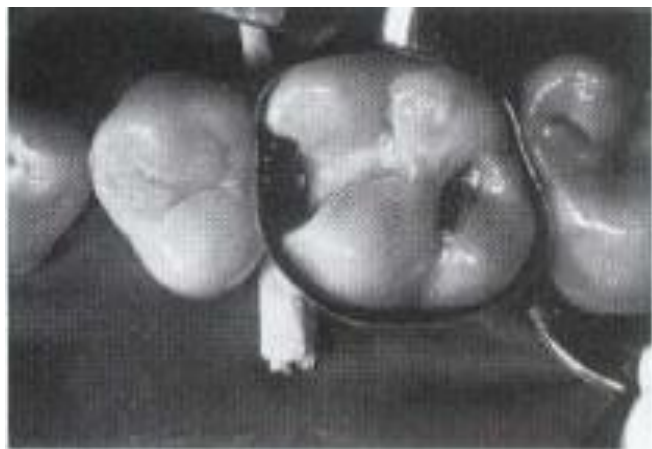


RESTORATIVE TECHNIQUE:

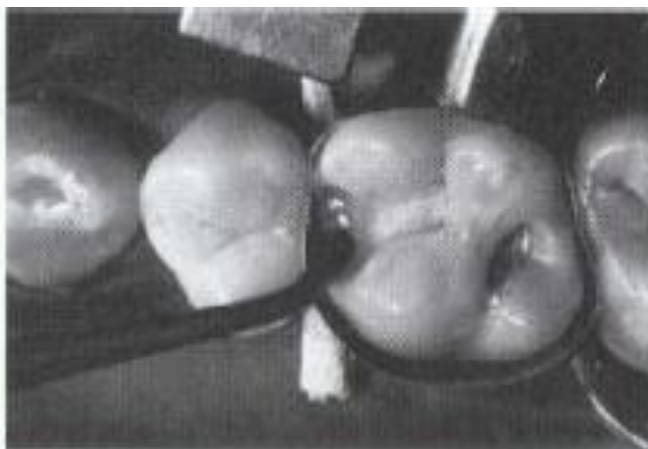
Matrix Application.

The important steps is the selection and proper placement of the matrix.

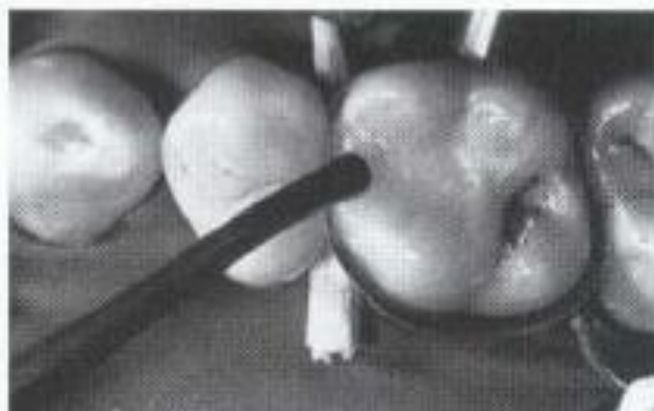
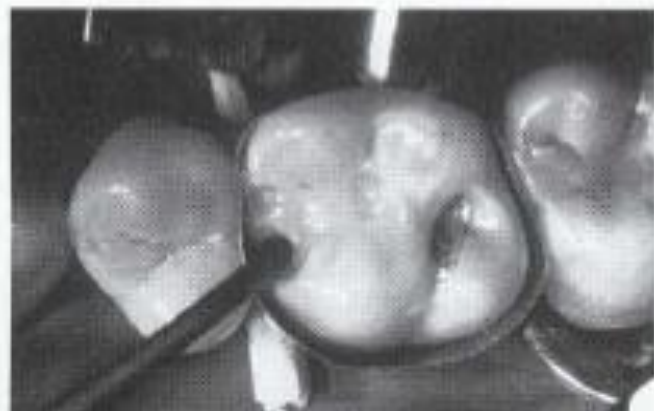- Unlike amalgam, which can be condensed to improve the proximal contact
- Early wedging and retightening of the wedge during tooth preparation aid in achieving sufficient separation of the teeth to compensate for the thickness of the matrix band.
- **The matrix band (strip) must be in absolute contact with (touching) the adjacent contact area.**
- An ultra thin metal matrix band is preferred for the restoration of a Class II composite,
- Following matrix placement; etching, priming, and adhesive placement. then the posterior composite material is followed in a small increments (usually not exceeding 2 mm in thickness at a time).



B

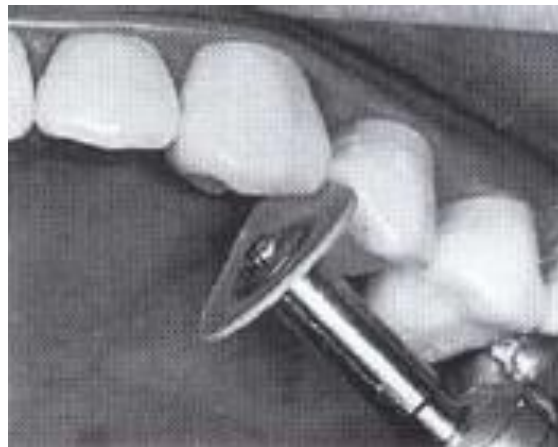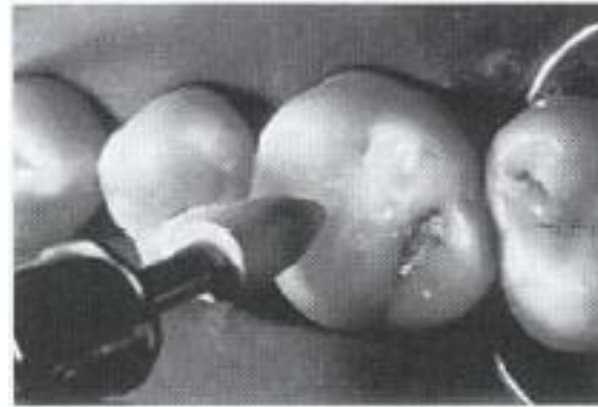
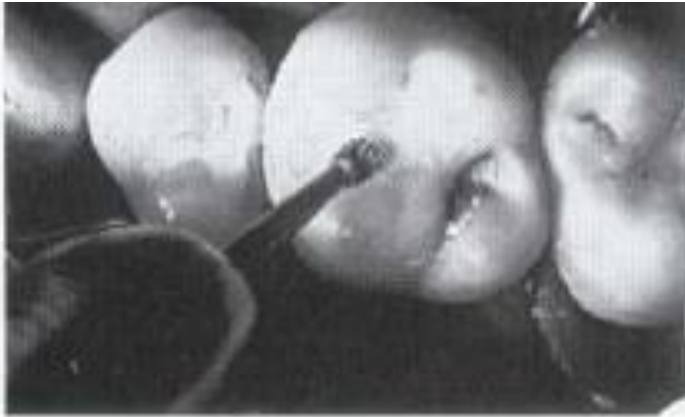


C



Contouring and Polishing the Composite.

Contouring can be initiated immediately after a light-cured composite or 3 minutes after the initial hardening of a self-cured material. The occlusal surface is shaped with a round or oval **carbide finishing bur or finishing diamond**. Excess composite is removed at the proximal margins and embrasures with a flame-shaped, 12-bladed carbide finishing bur or **finishing diamond and abrasive discs**.

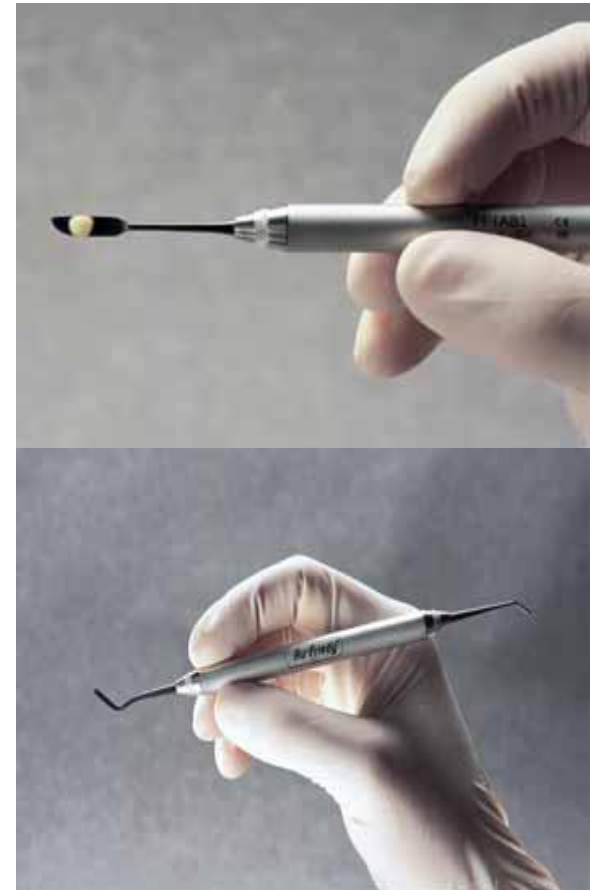


Composite placement instrument

Designed specifically for the placement of composite restorative materials.

**Excellent Handling
without discoloring the filling
No Adhesion Effect
Long Service Life**

1. Anodized aluminum
2. Teflon
3. Titanium coated
4. Plastic
5. Aluminum-titanium nitride coatings
6. Gold-colored titanium coatings

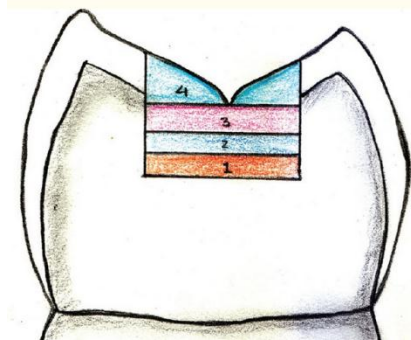


Application techniques of composite resins

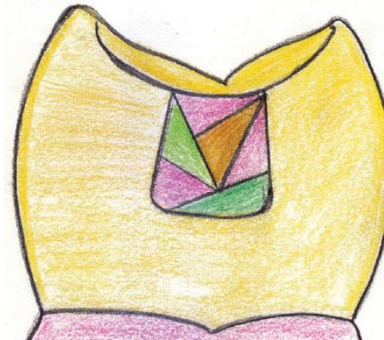
1. The incremental techniques

To reduce polymerization shrinkage by:

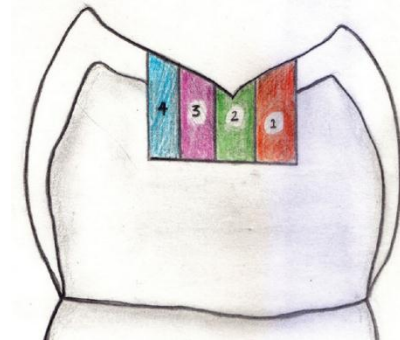
1. Using small composite increments (2-mm)
2. Minimizing the cavity factor (C-factor)



Shrinkage stresses
between the opposing cavity walls



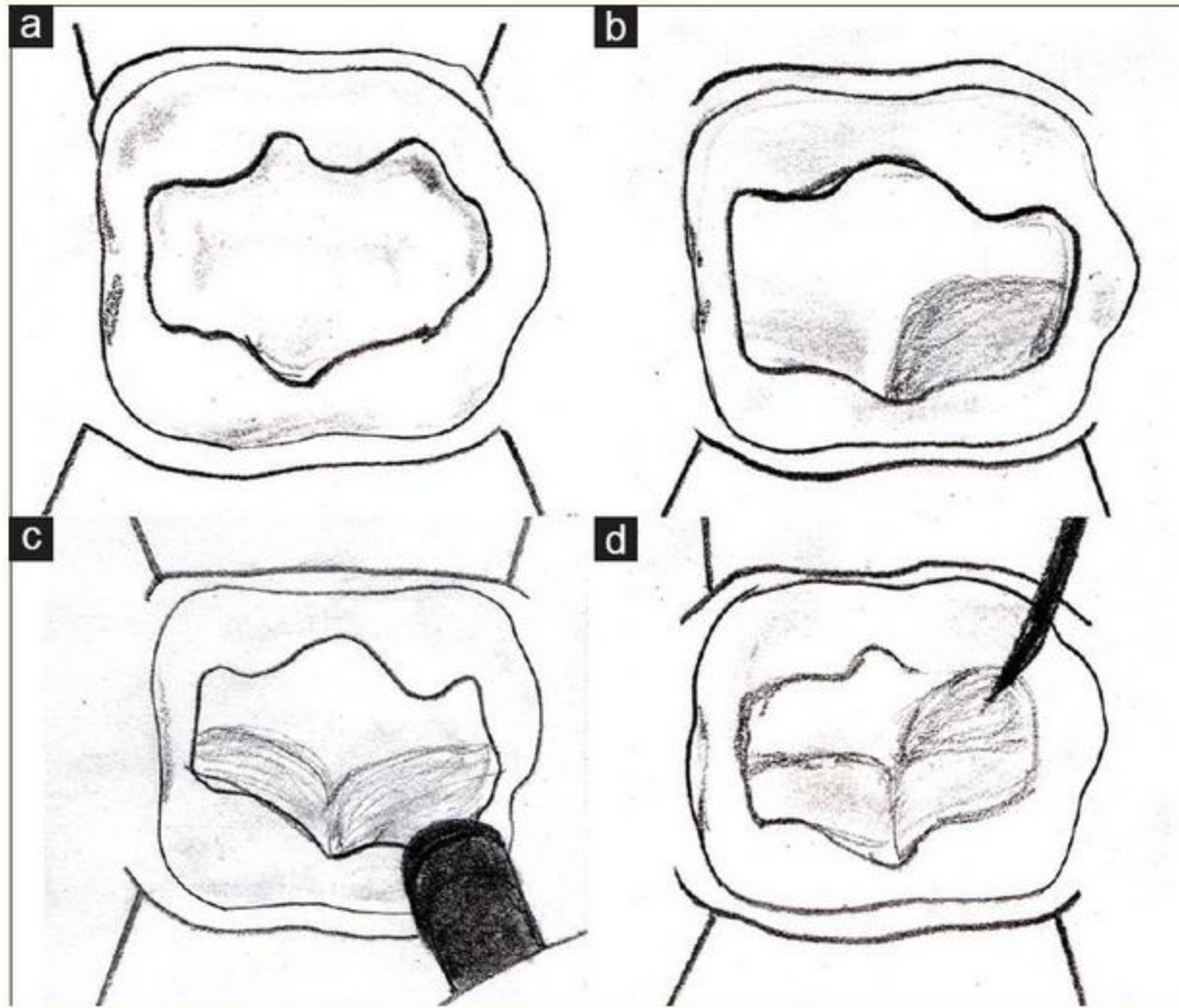
This technique reduces
the C-factor

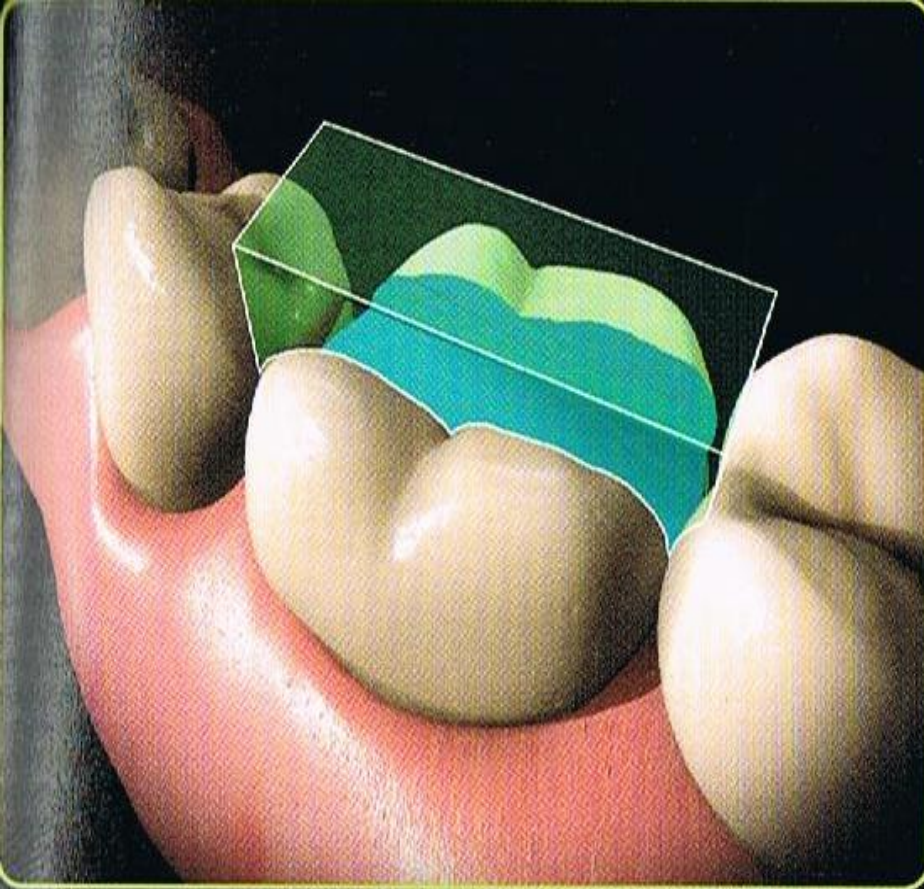


This reduces gap at
gingival margin

Also these techniques have many advantages including; easier handling, better modeling of the restoration, and improved material polymerization

- Successive cusp buildup technique



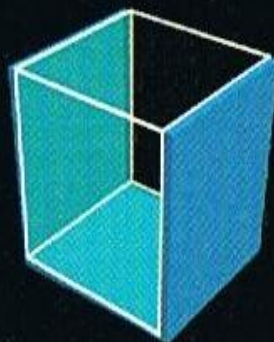


Bonded surfaces

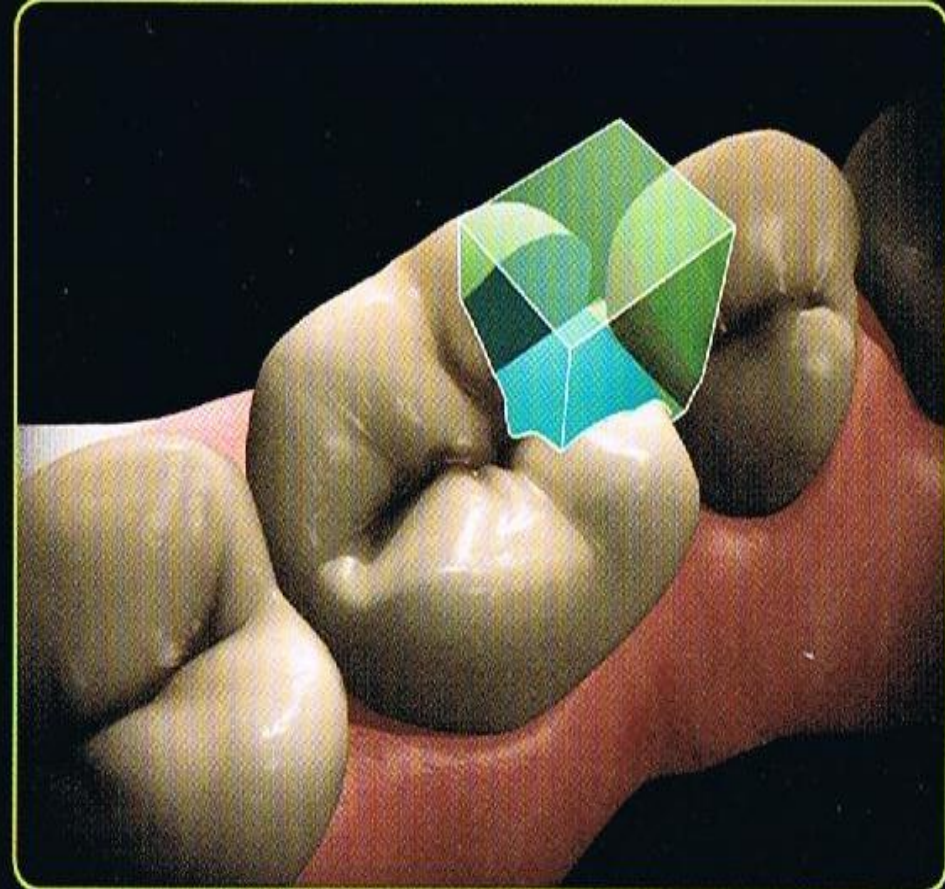
3

Unbonded surfaces

3



"C" Factor = 1

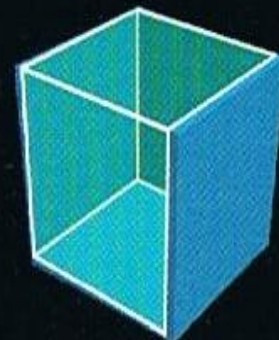


Bonded surfaces

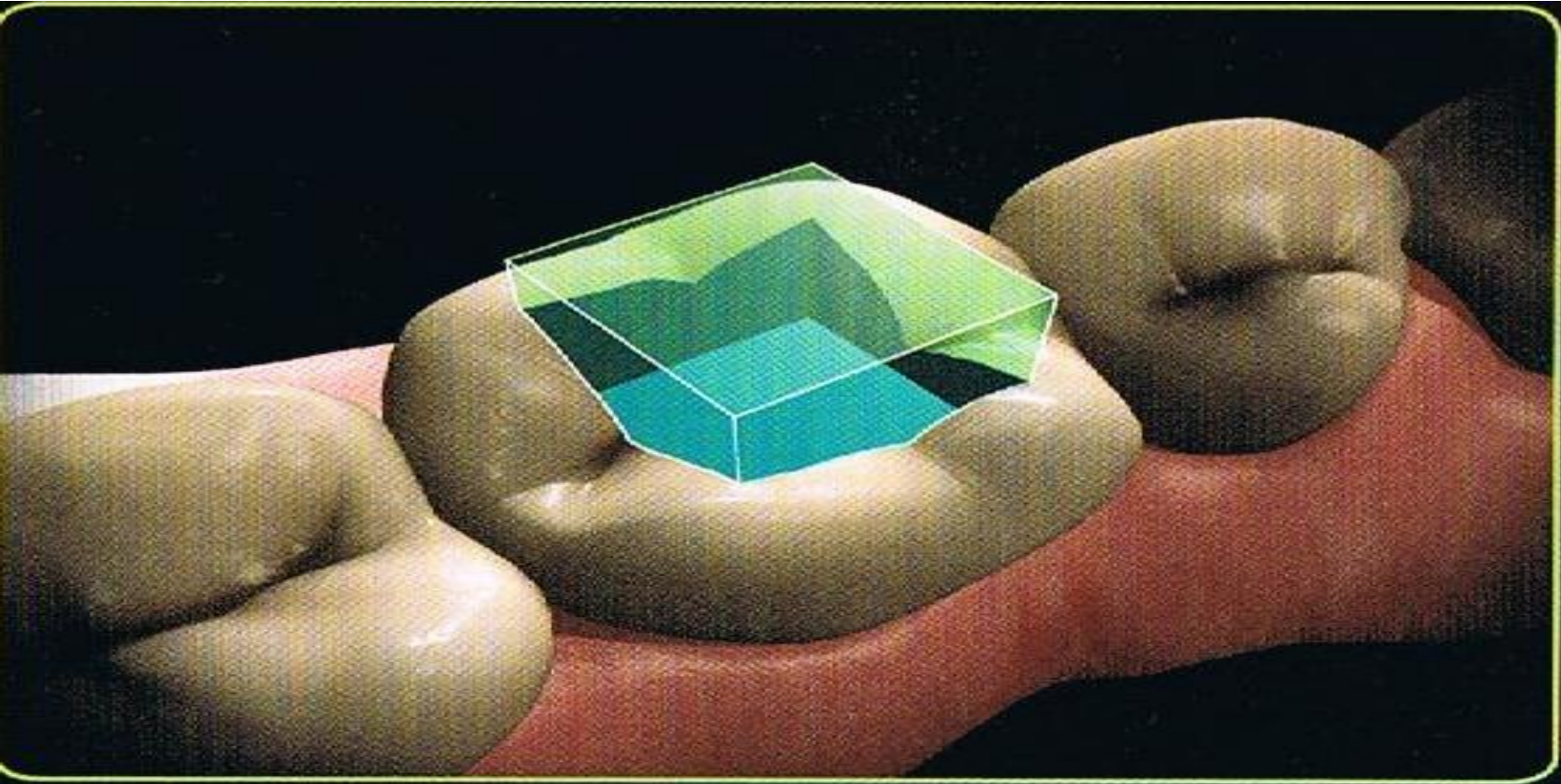
4

Unbonded surfaces

2



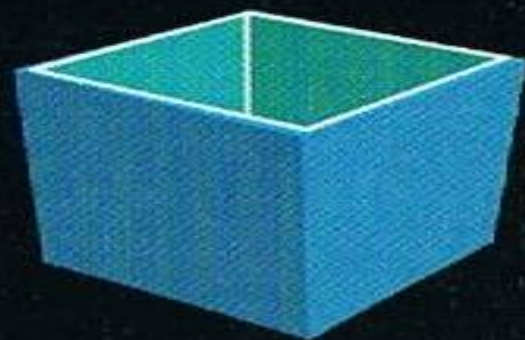
"C" Factor = 2



Bonded surfaces

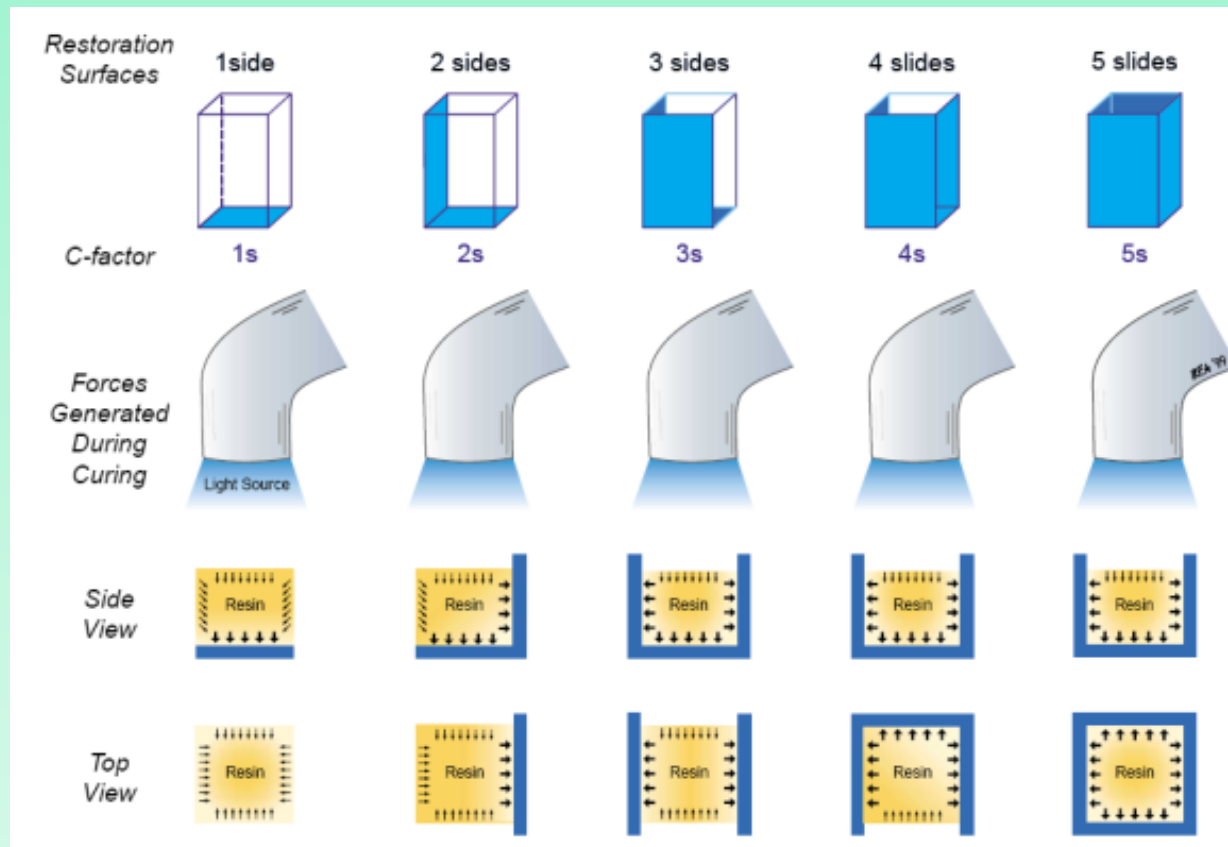
Unbonded surfaces

$$\frac{5}{1}$$



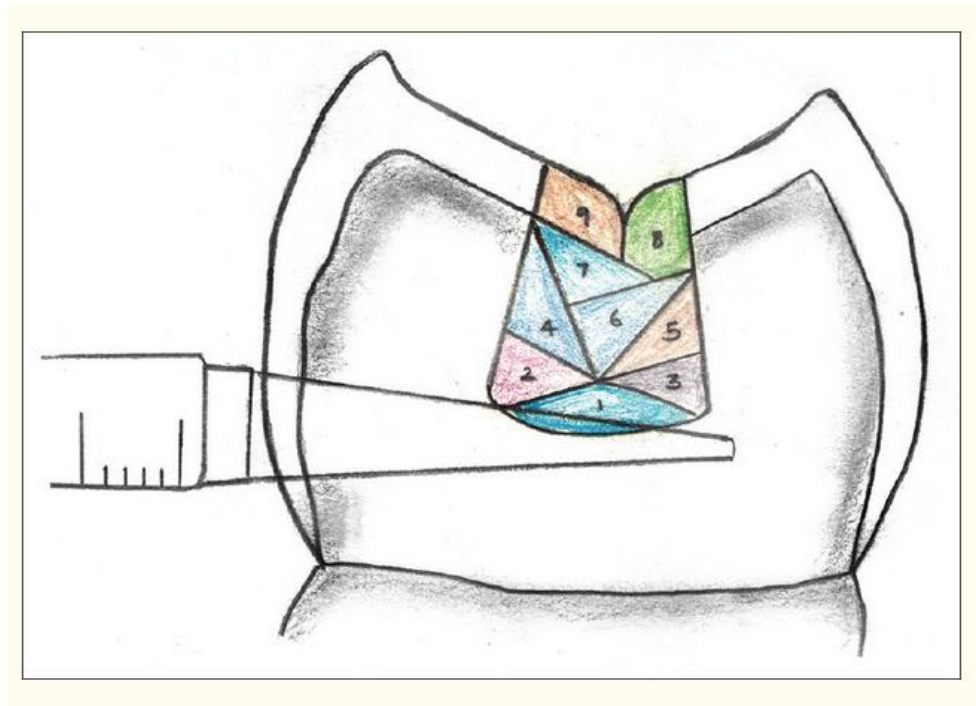
"C" Factor = 5

An increased c – value leads to a decreased flow capacity which causes a higher rate of shrinkage stress development.



Three-site technique

Polymerization via Buccal, Lingual, and occlusal directions to improve marginal adaptation



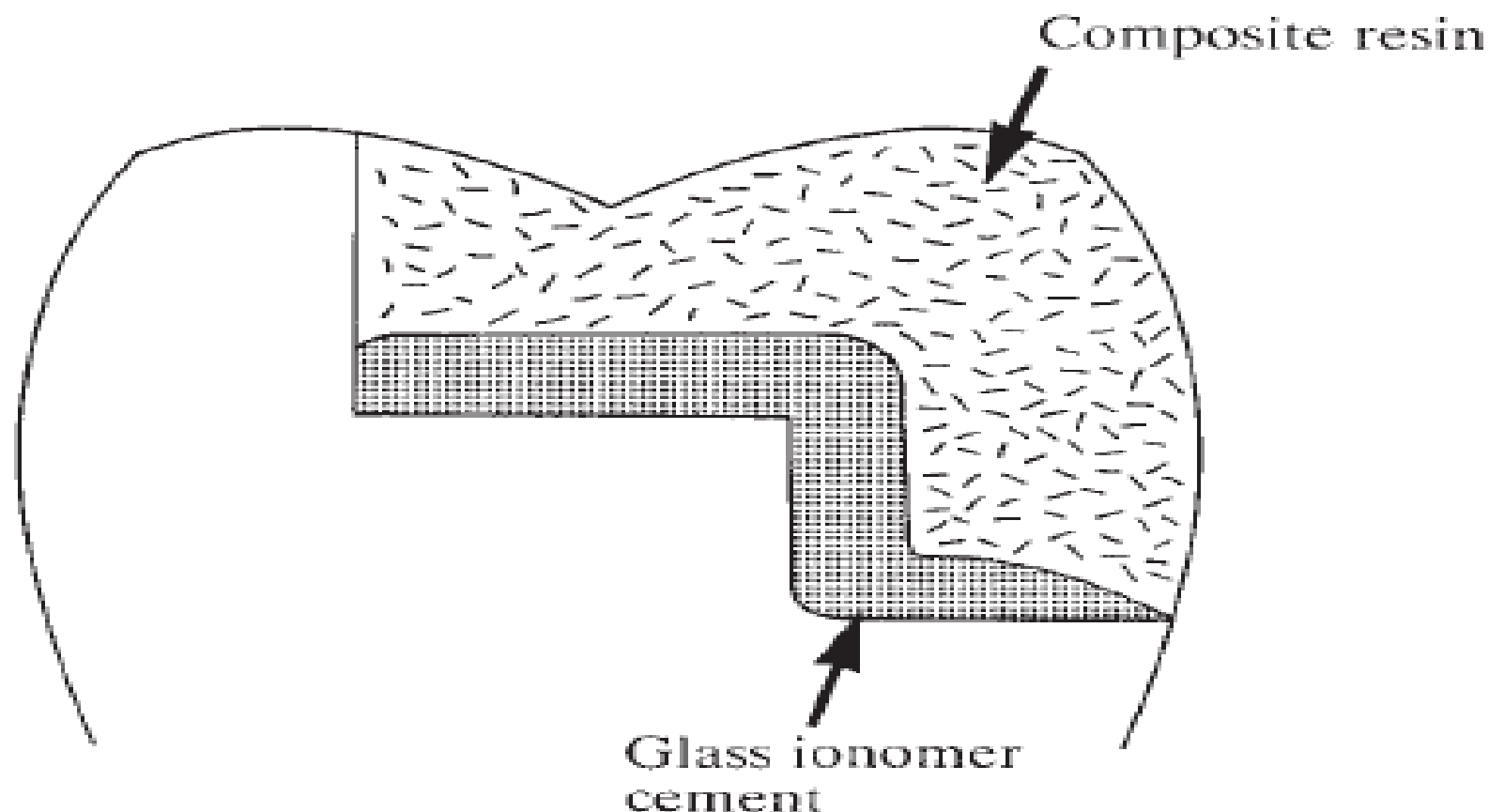
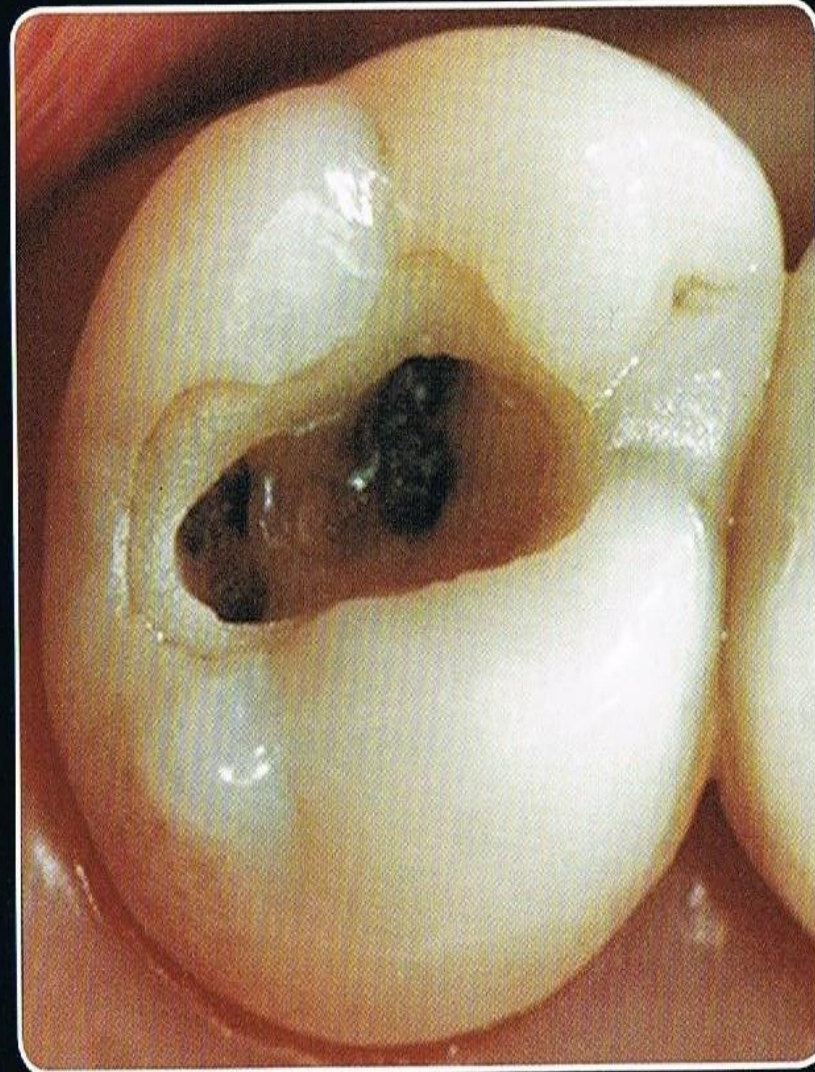
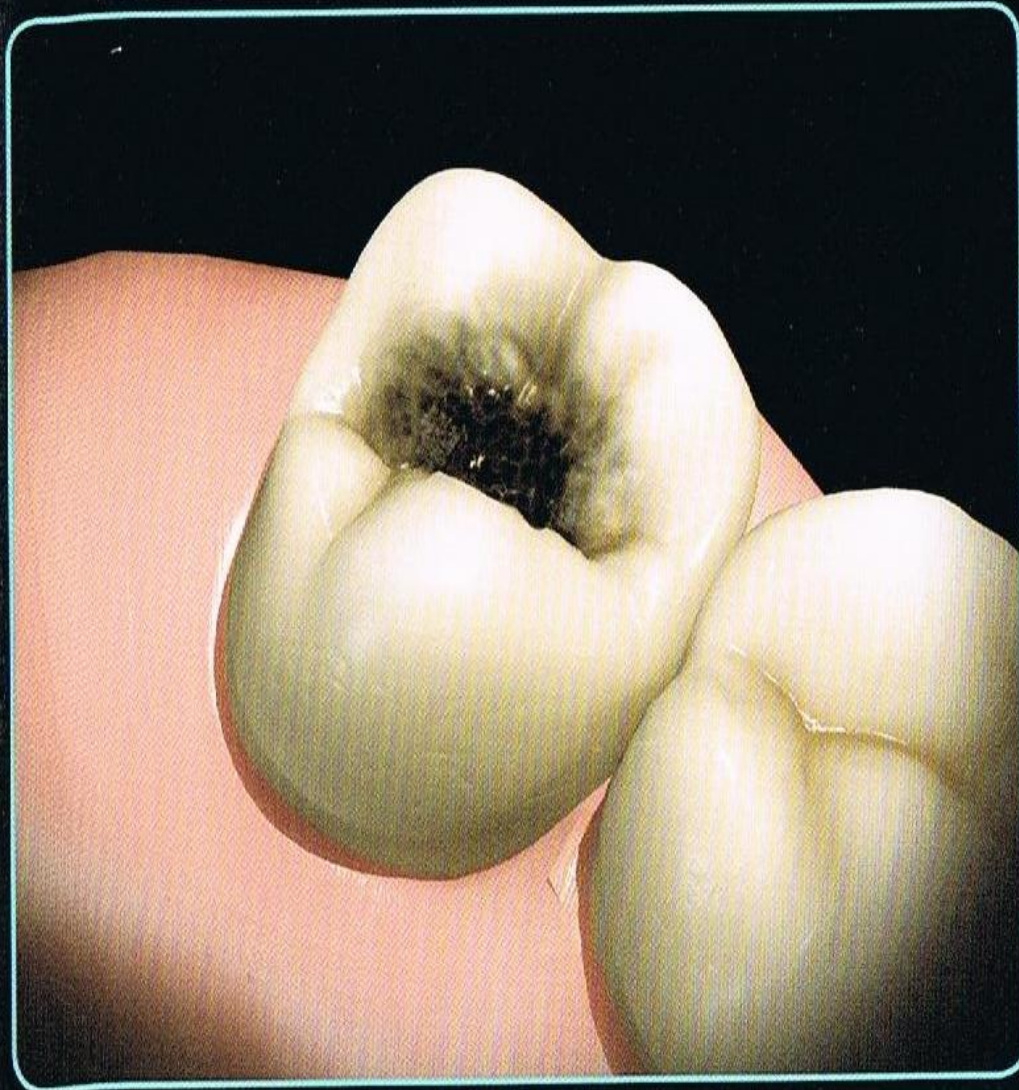
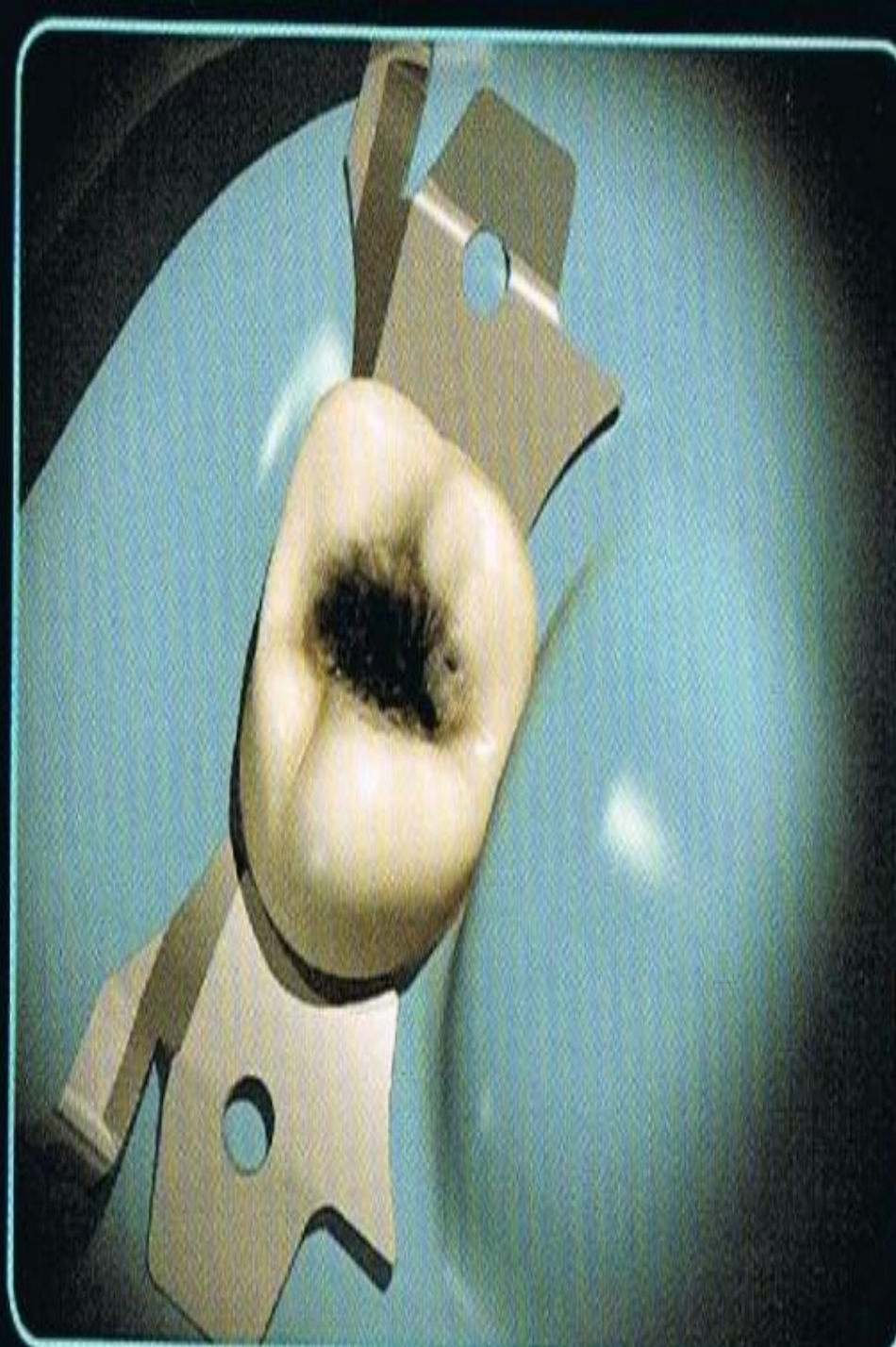
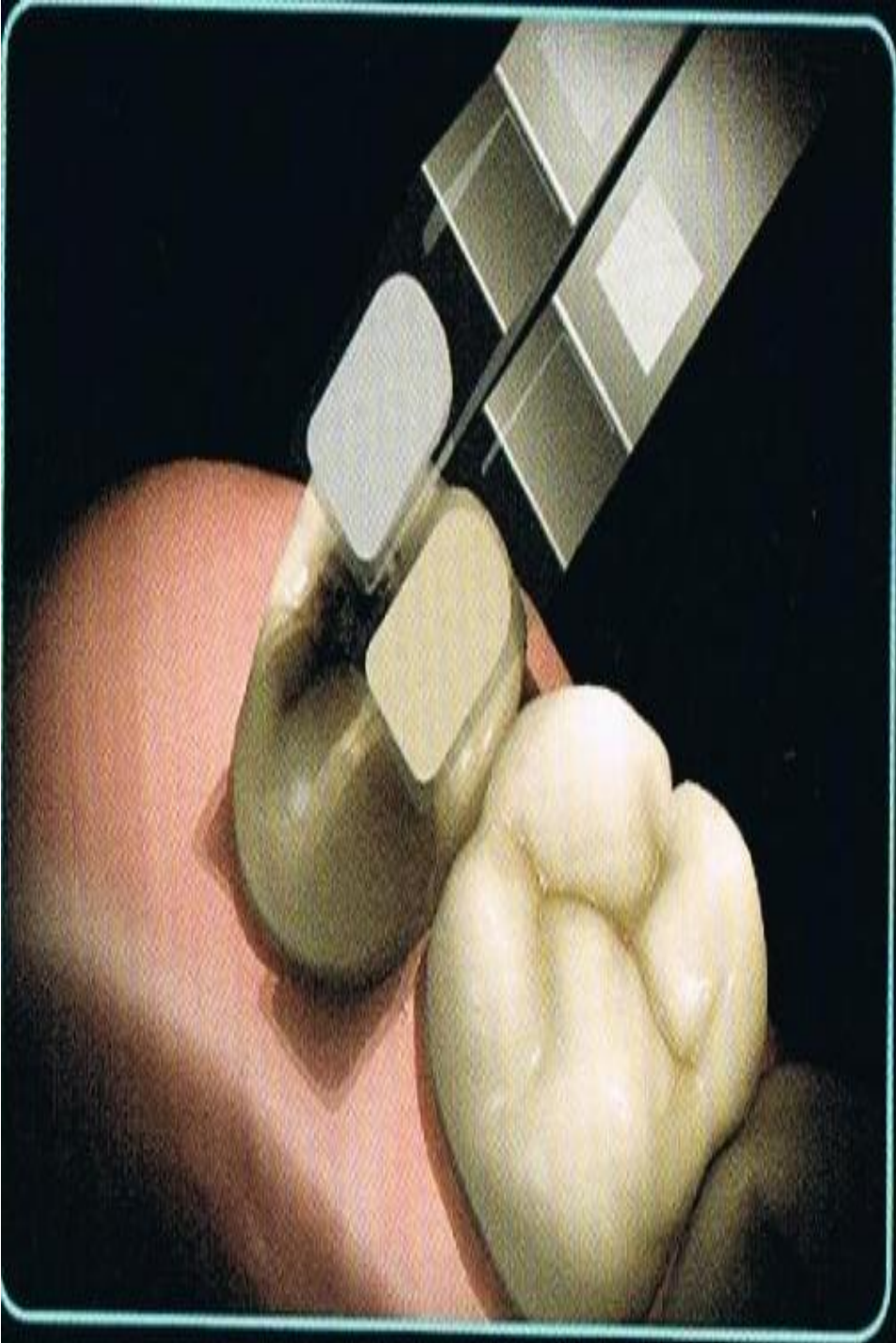
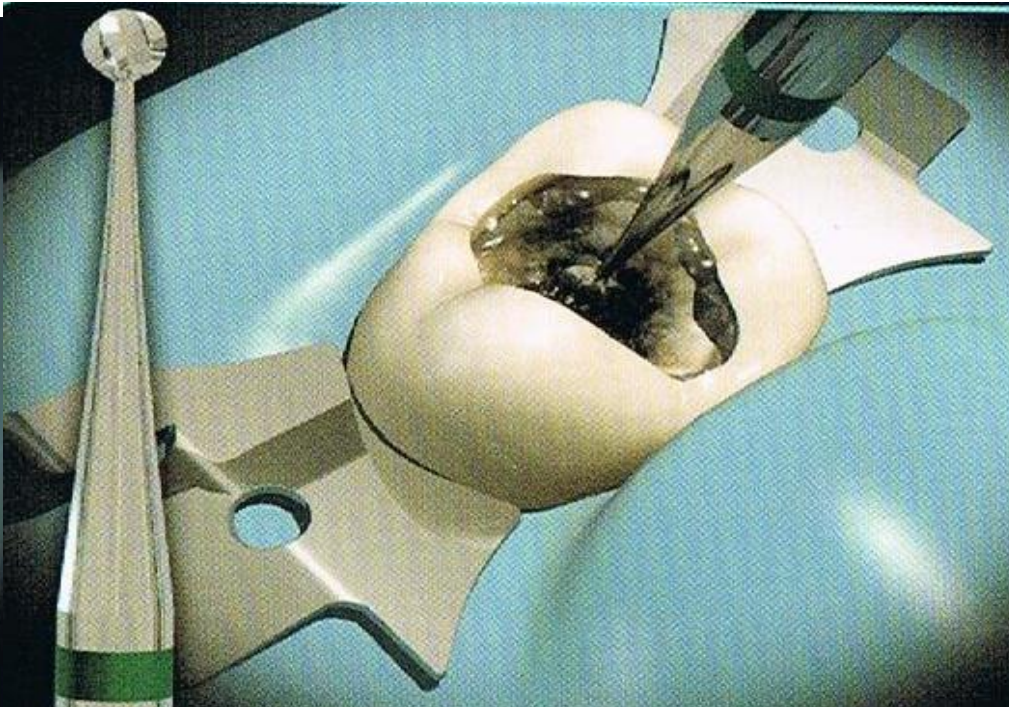
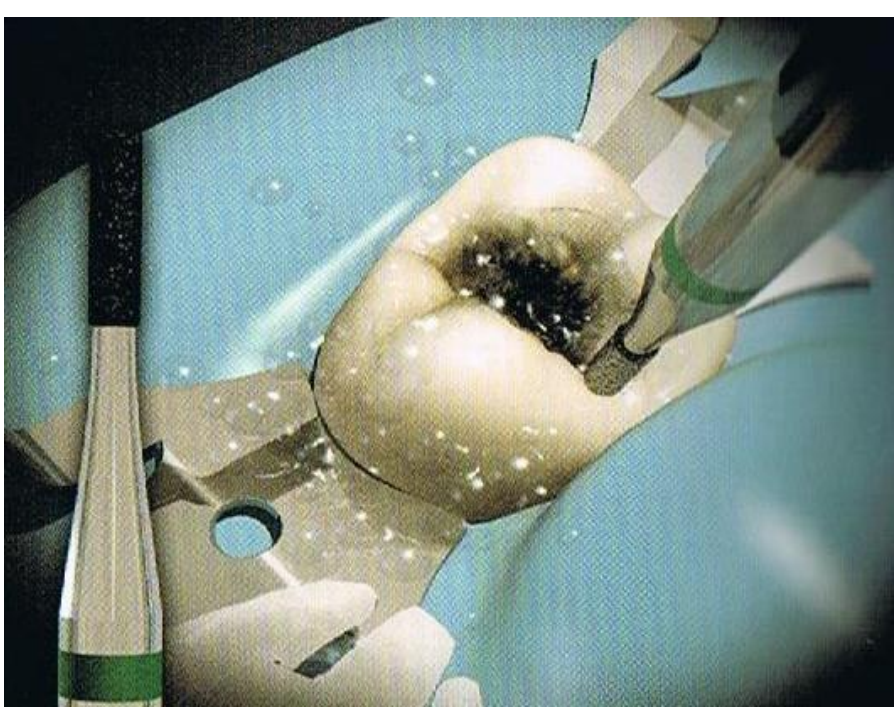


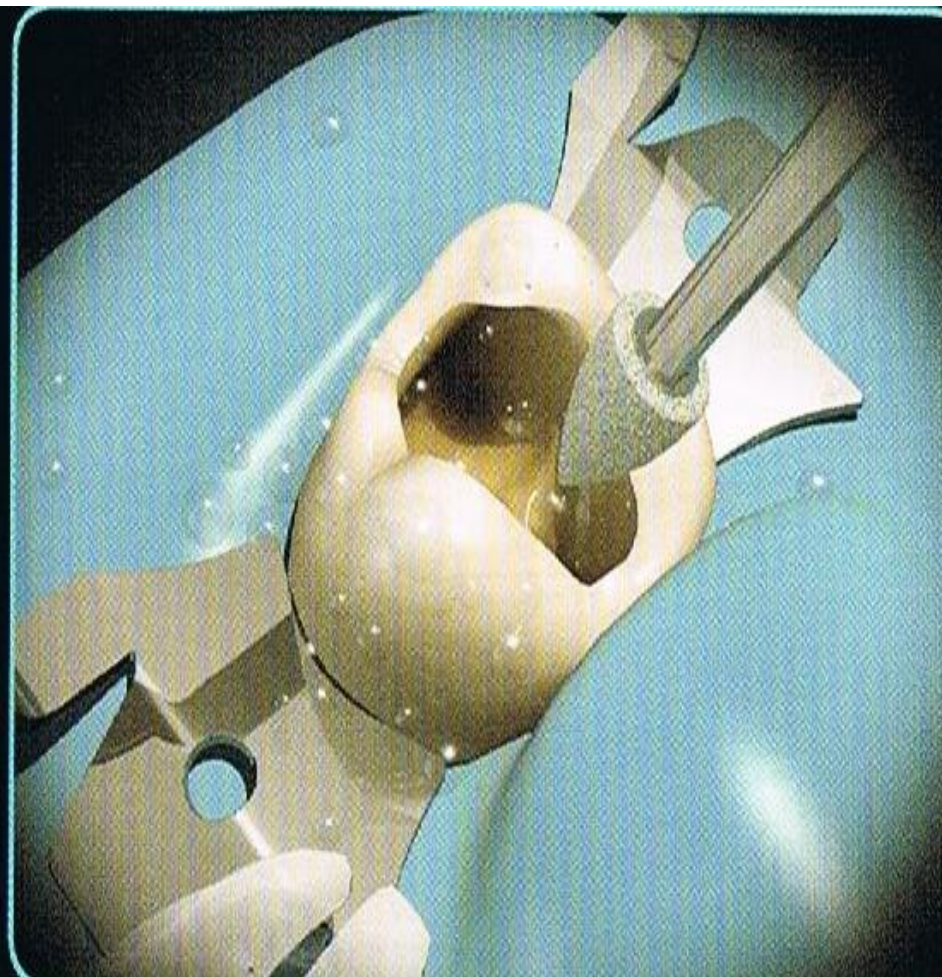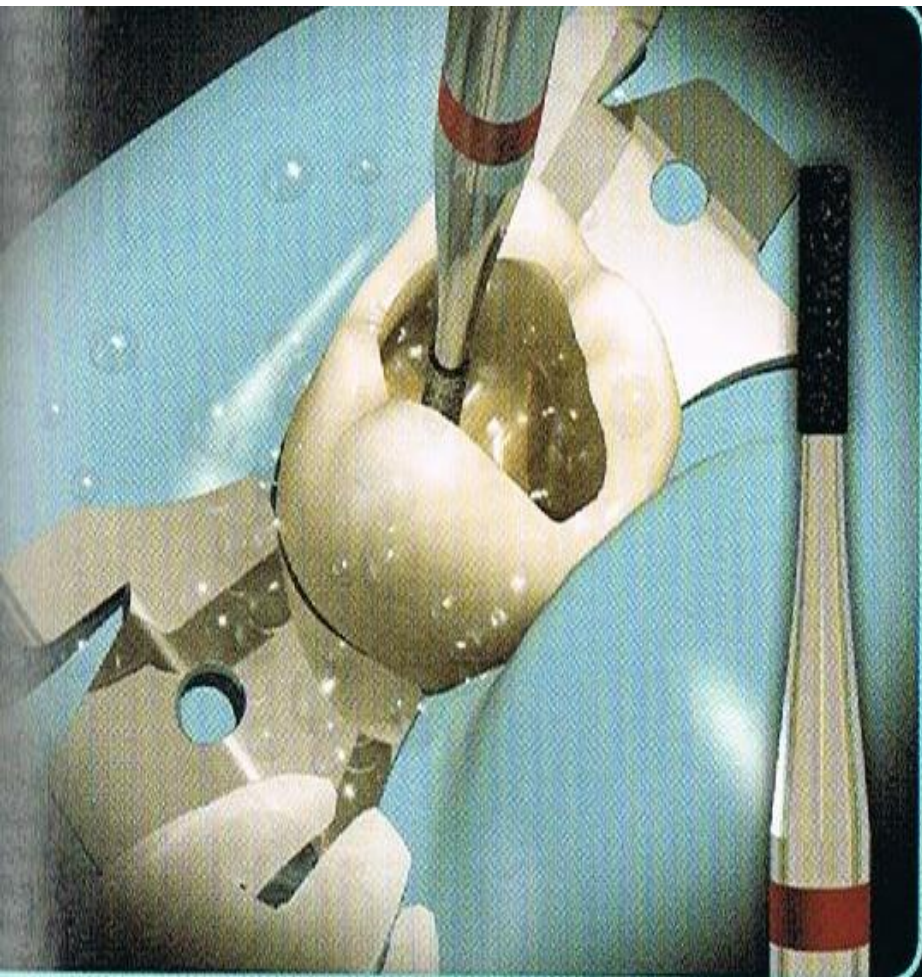
Fig. 24.9 Diagram illustrating the use of composite and glass ionomer cement for the restoration of a class II cavity – the sandwich technique. This combines the adhesive characteristics of glass ionomer cements with the better durability of composites.

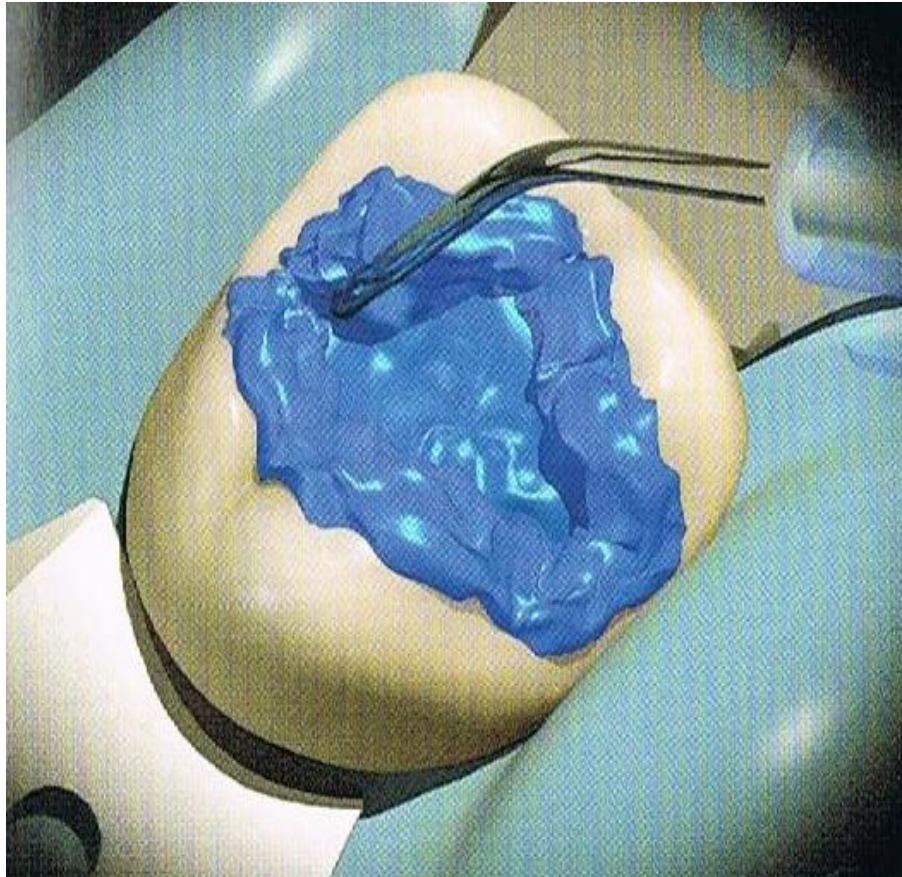
Presentation of clinical case of class I

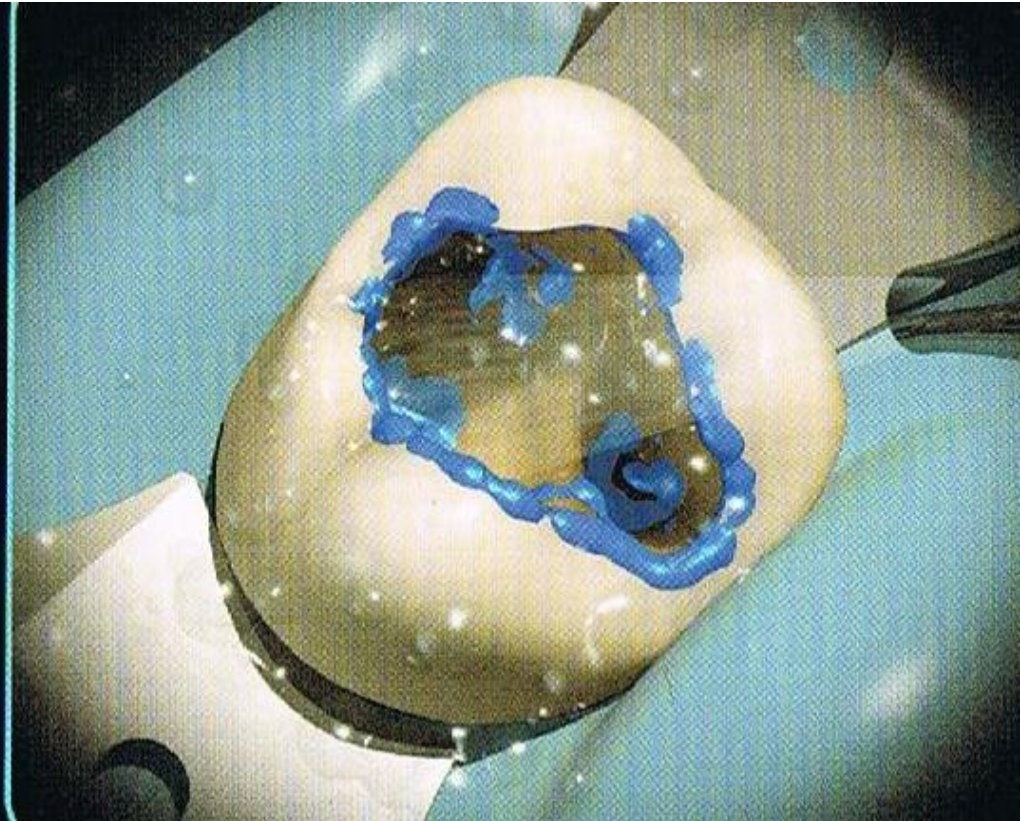
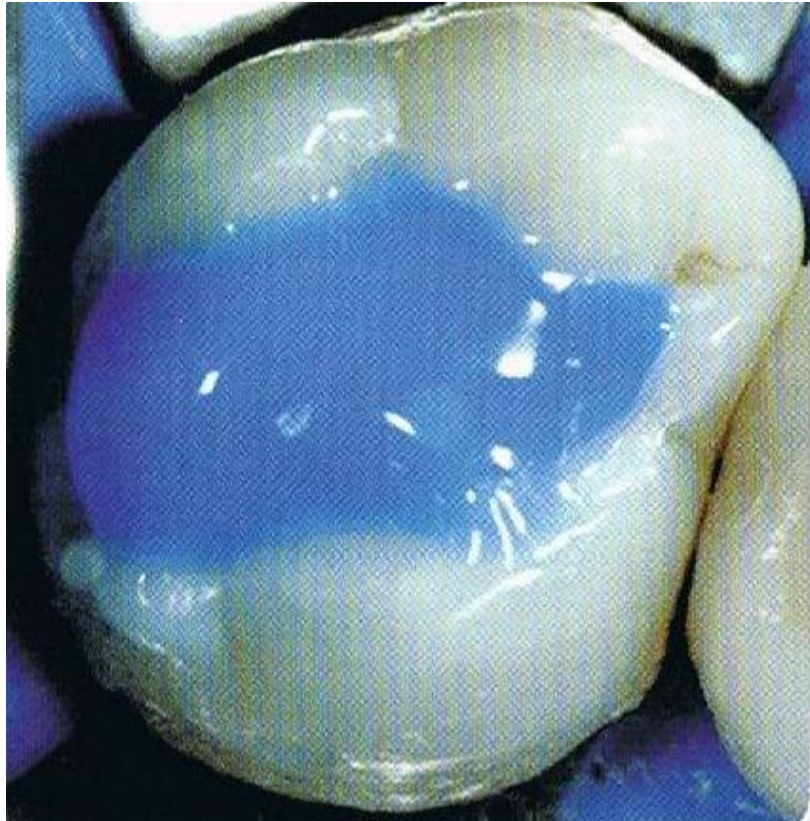


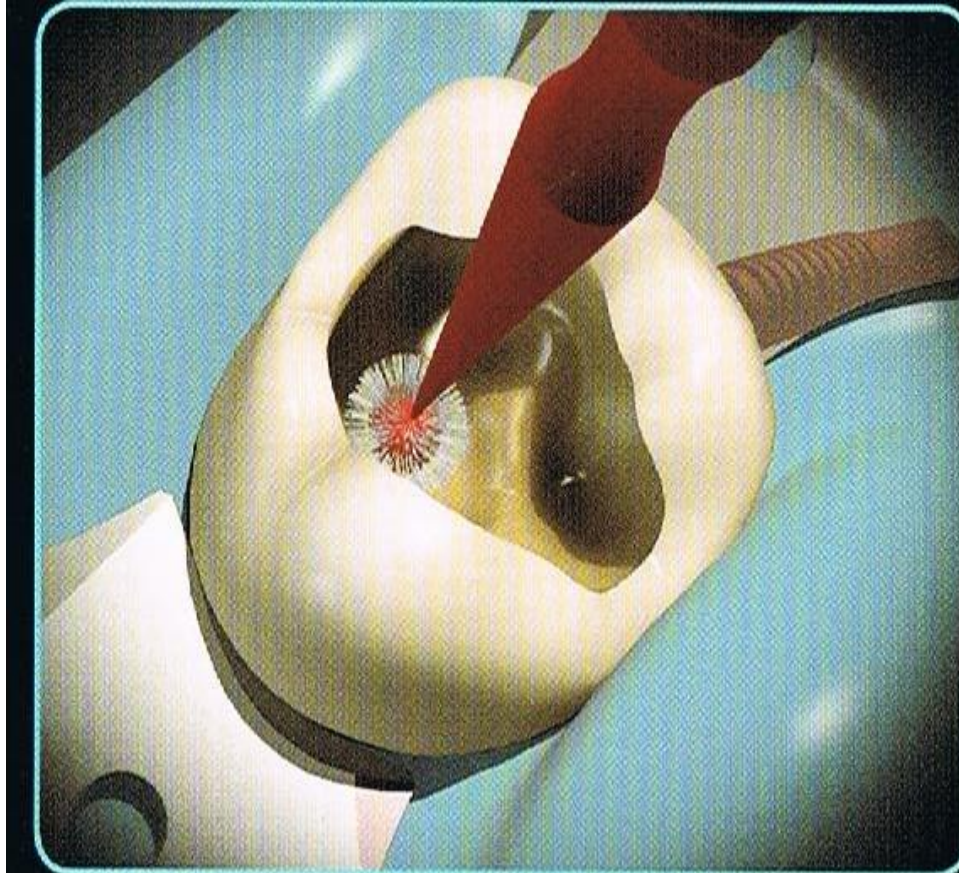







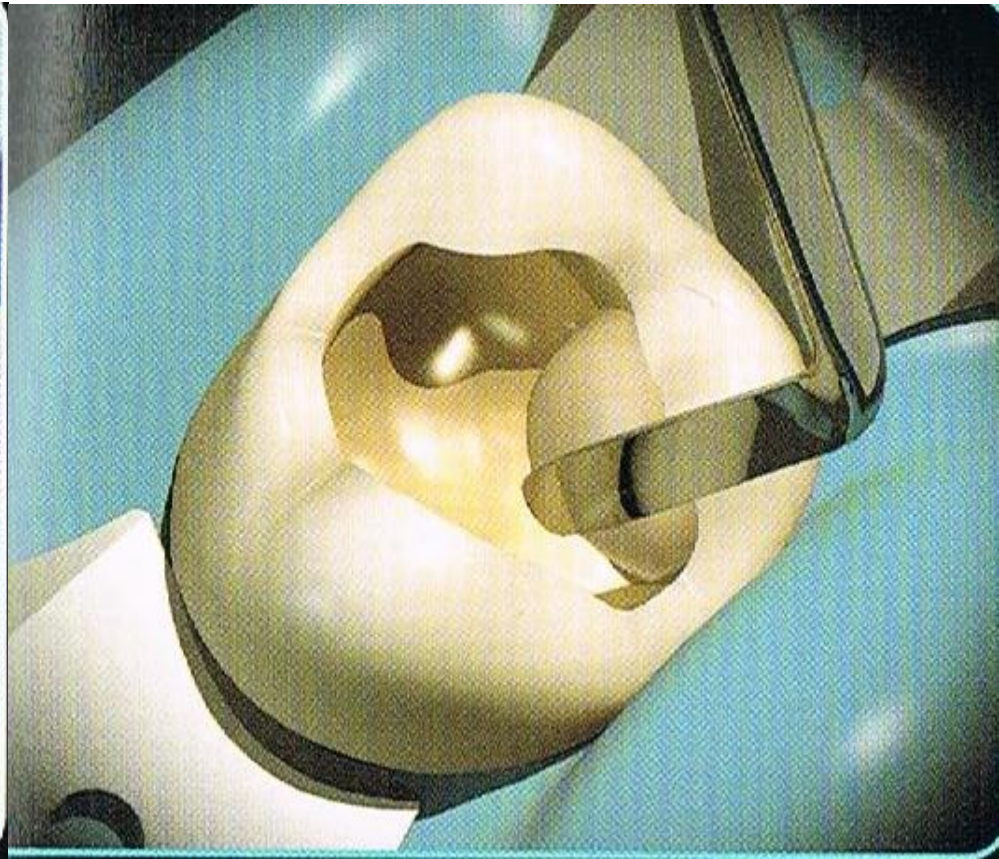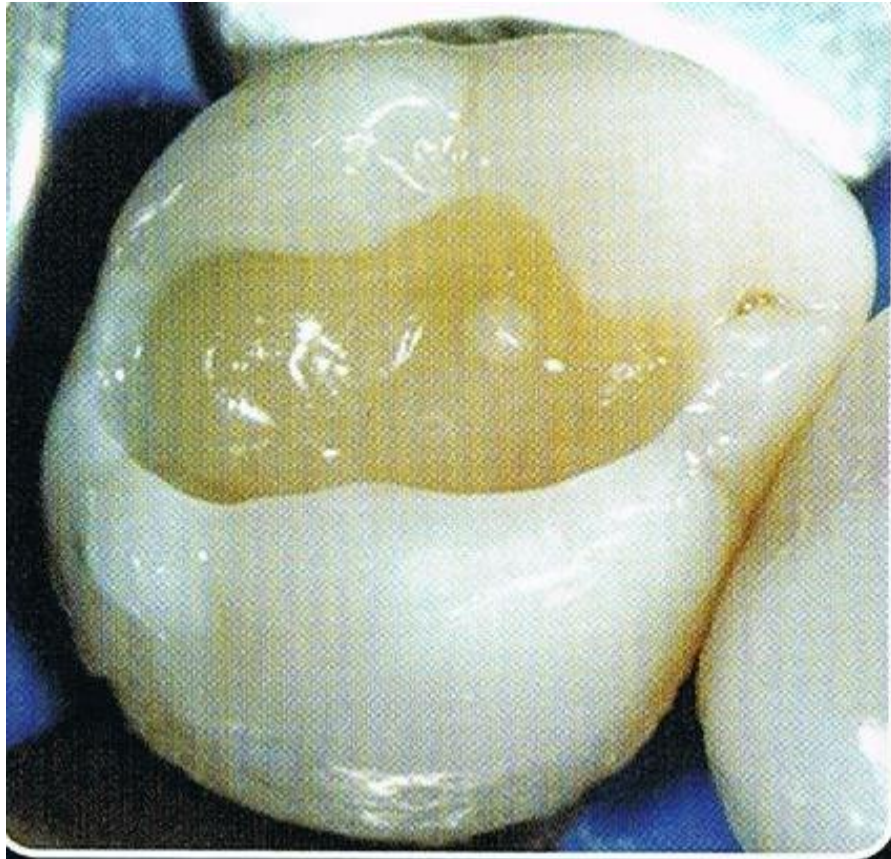


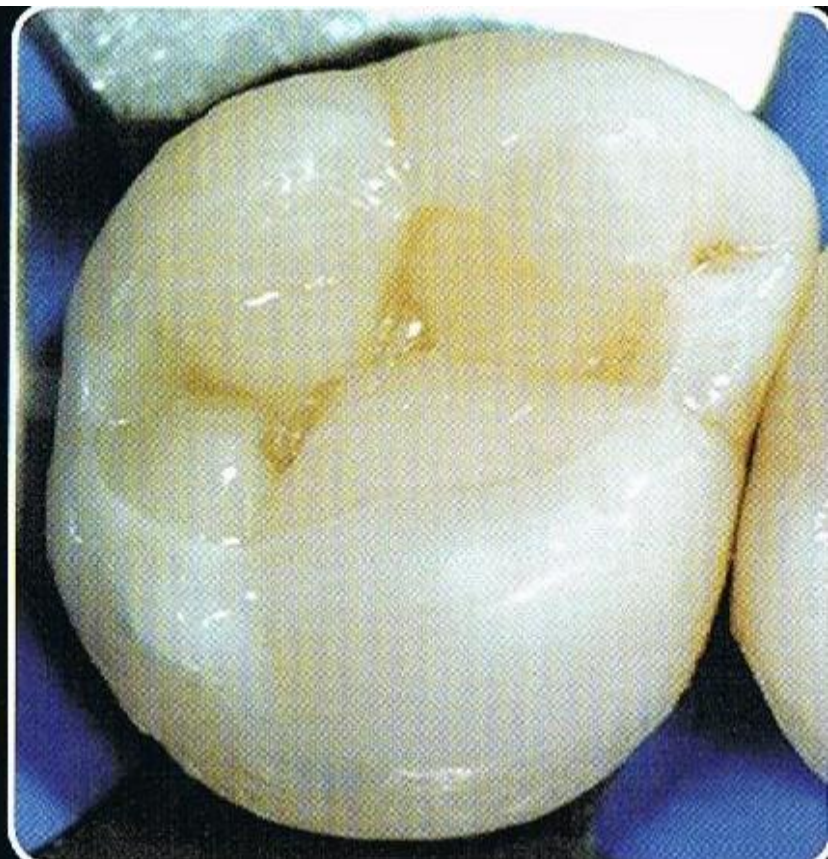
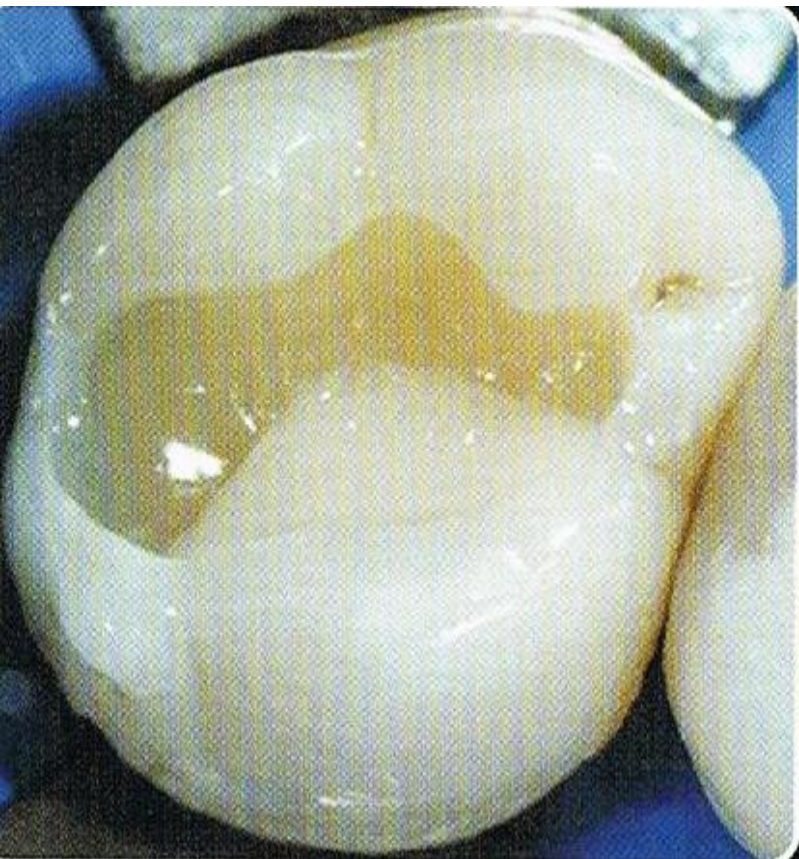

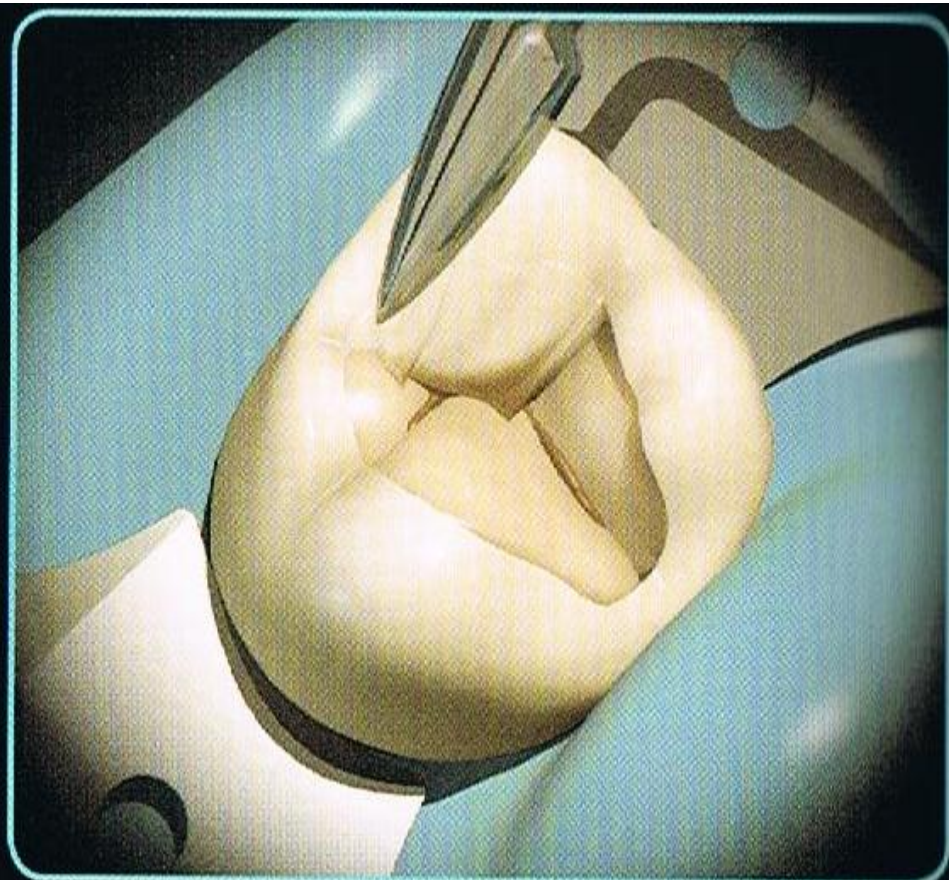
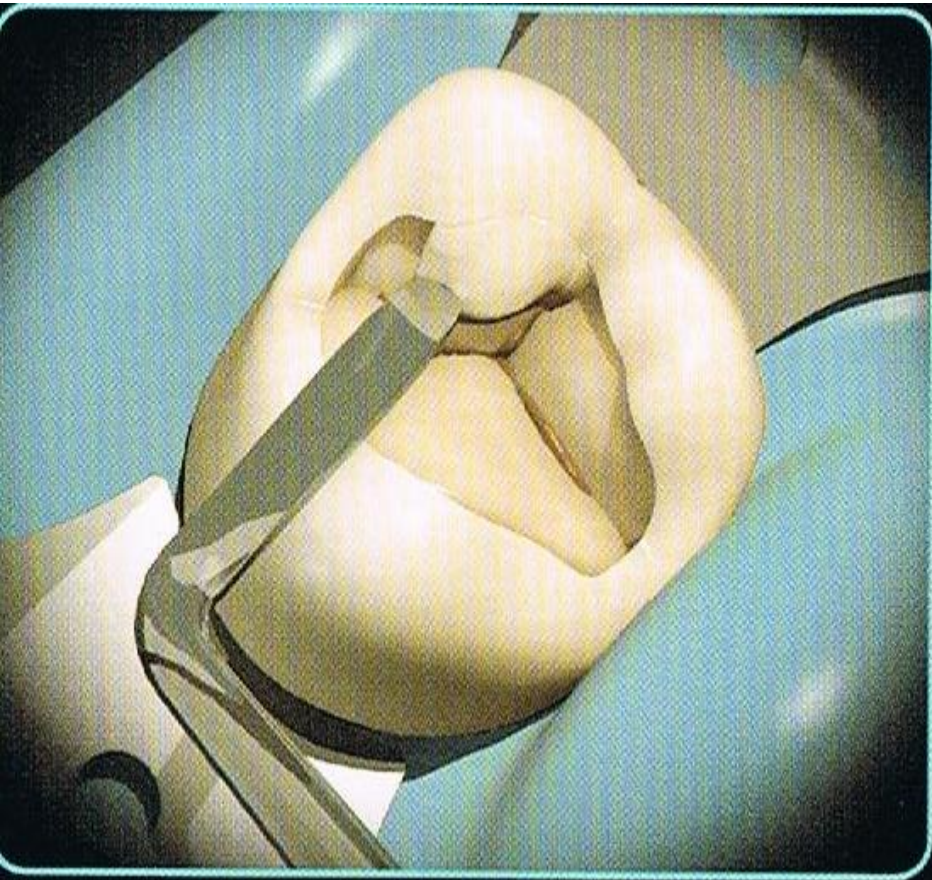


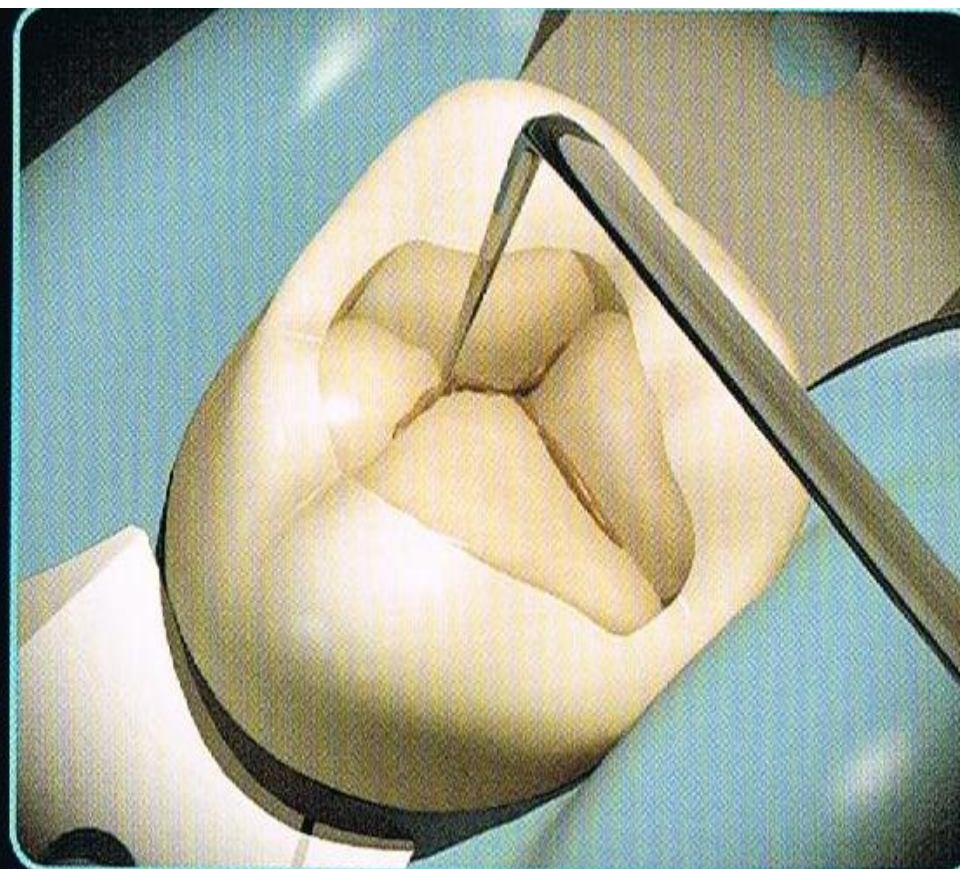
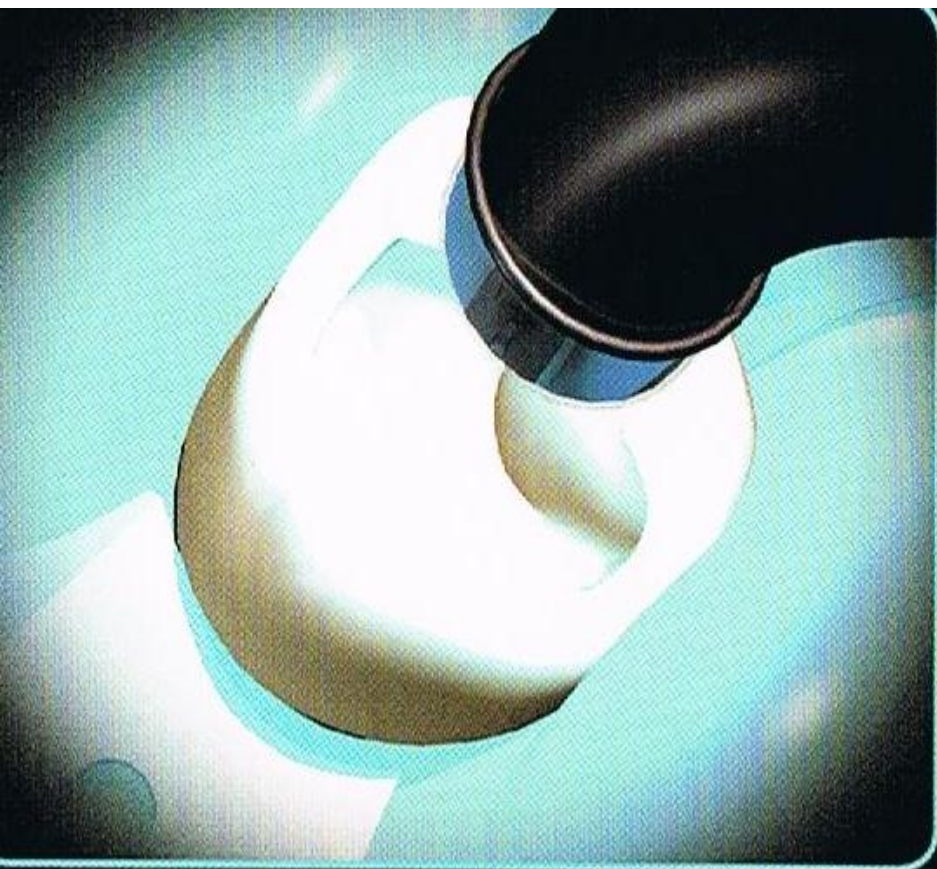



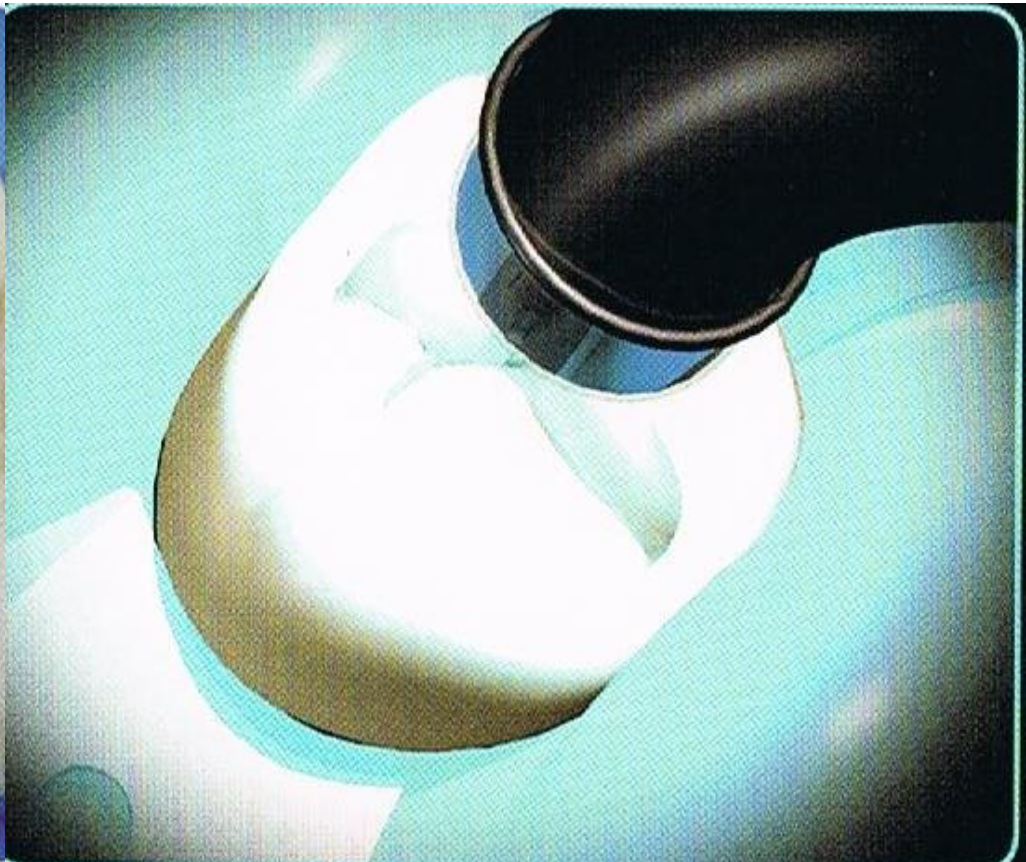
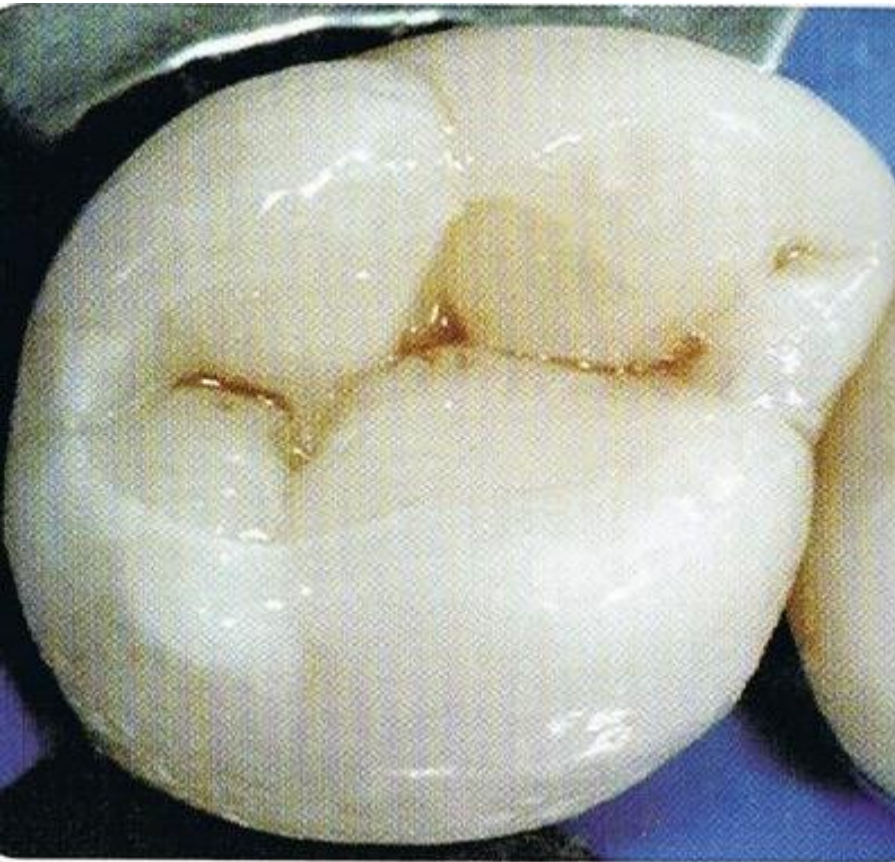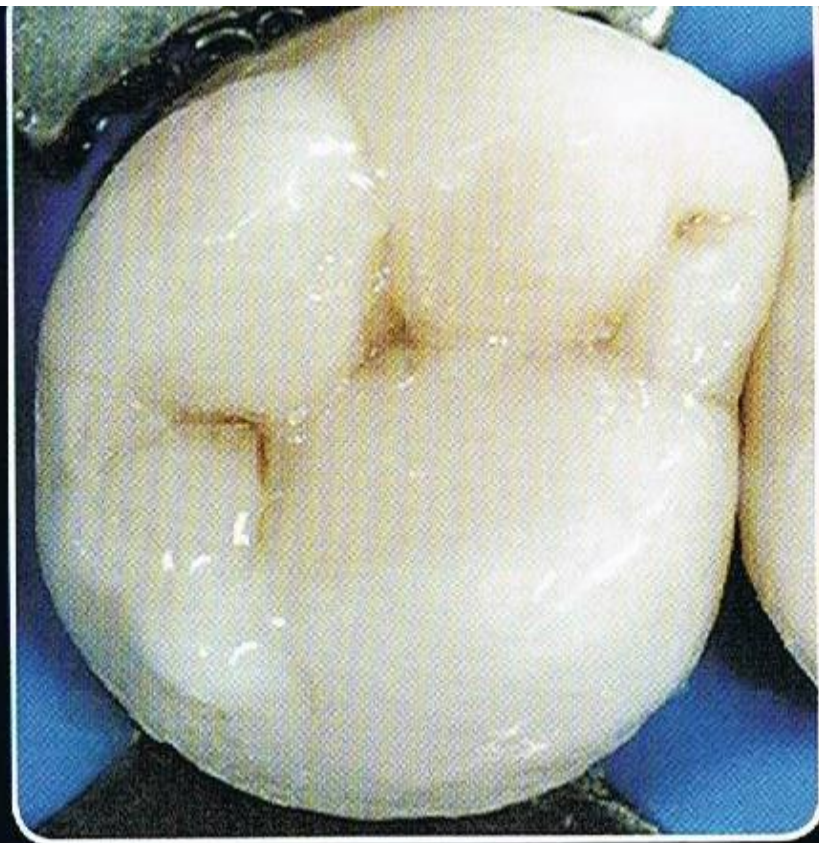
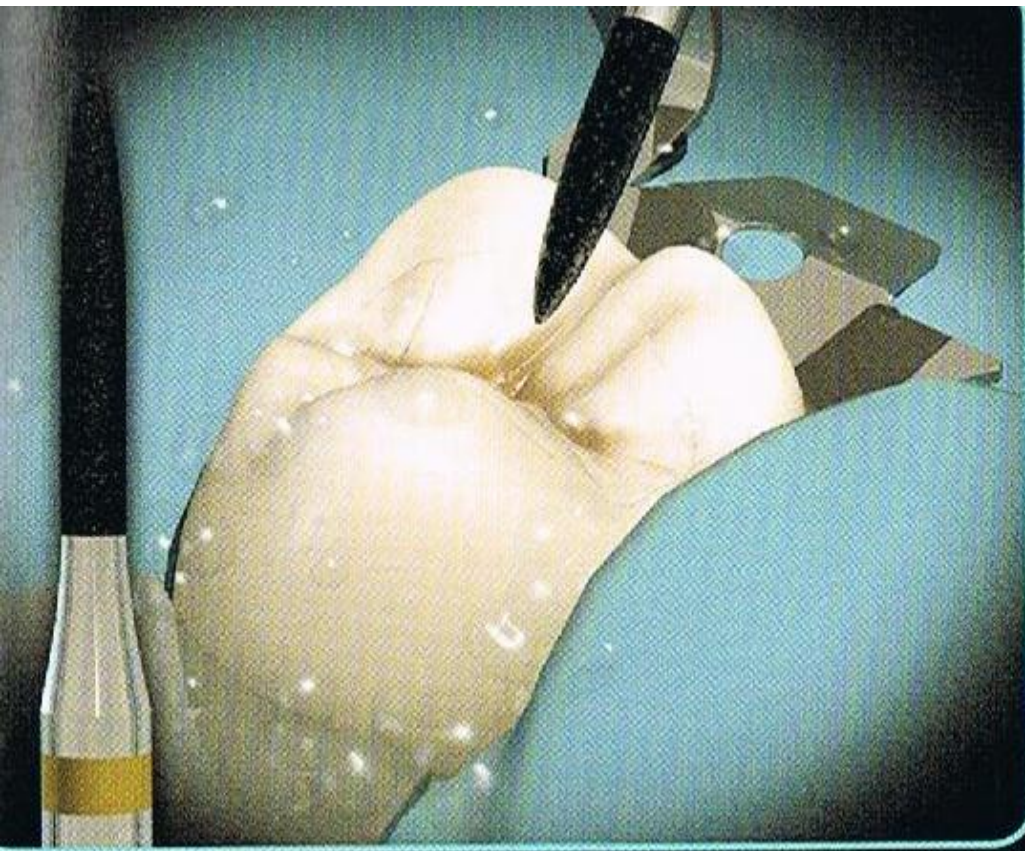




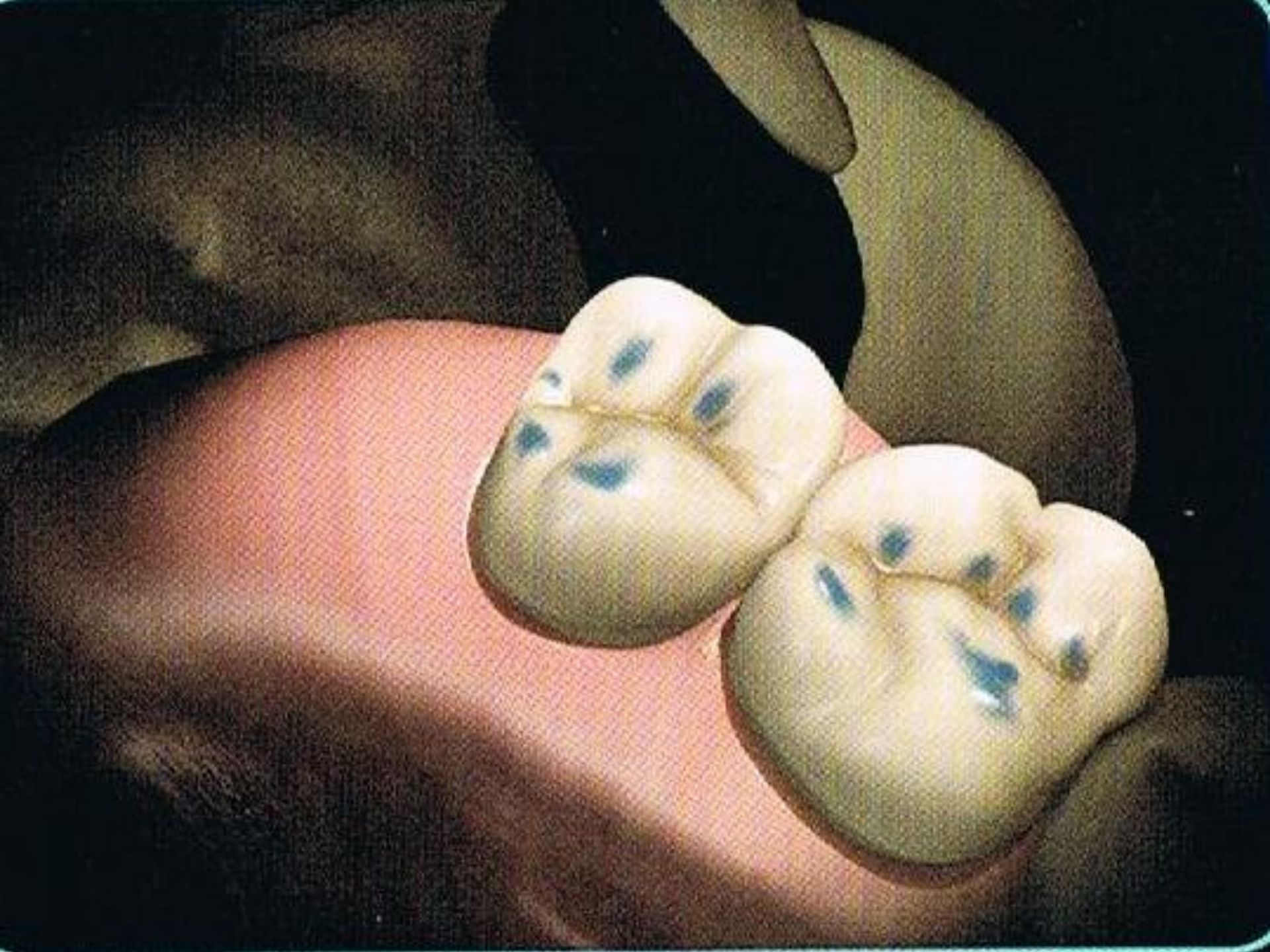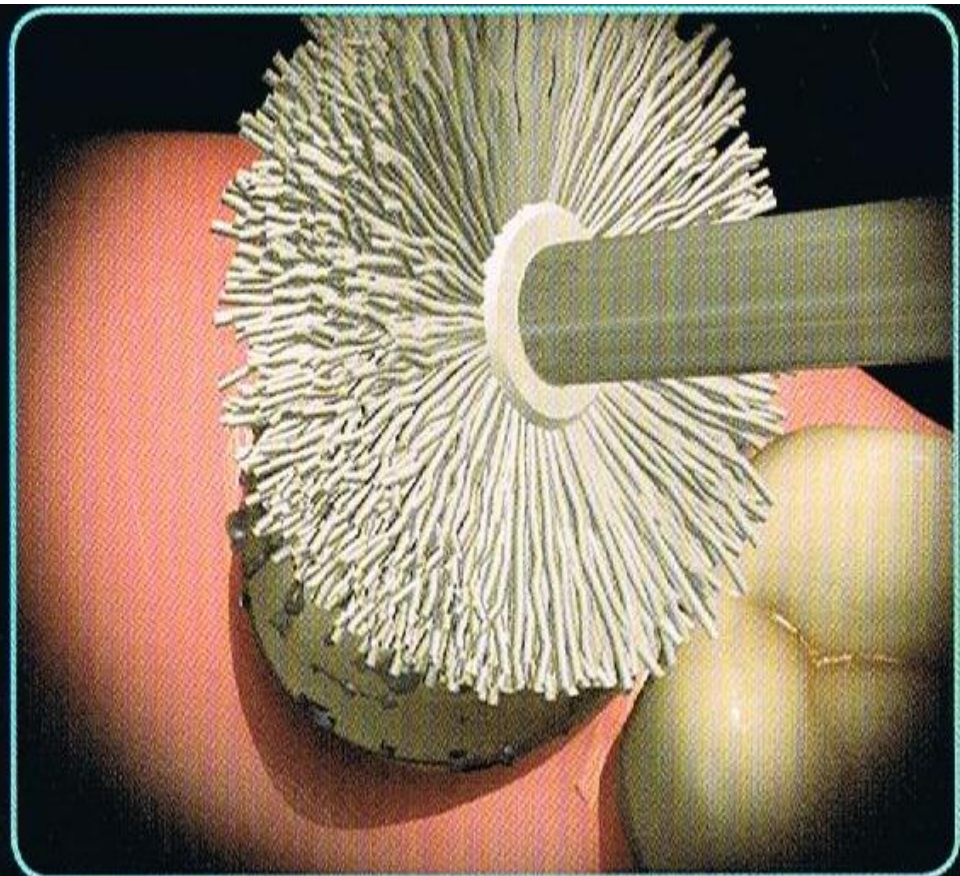
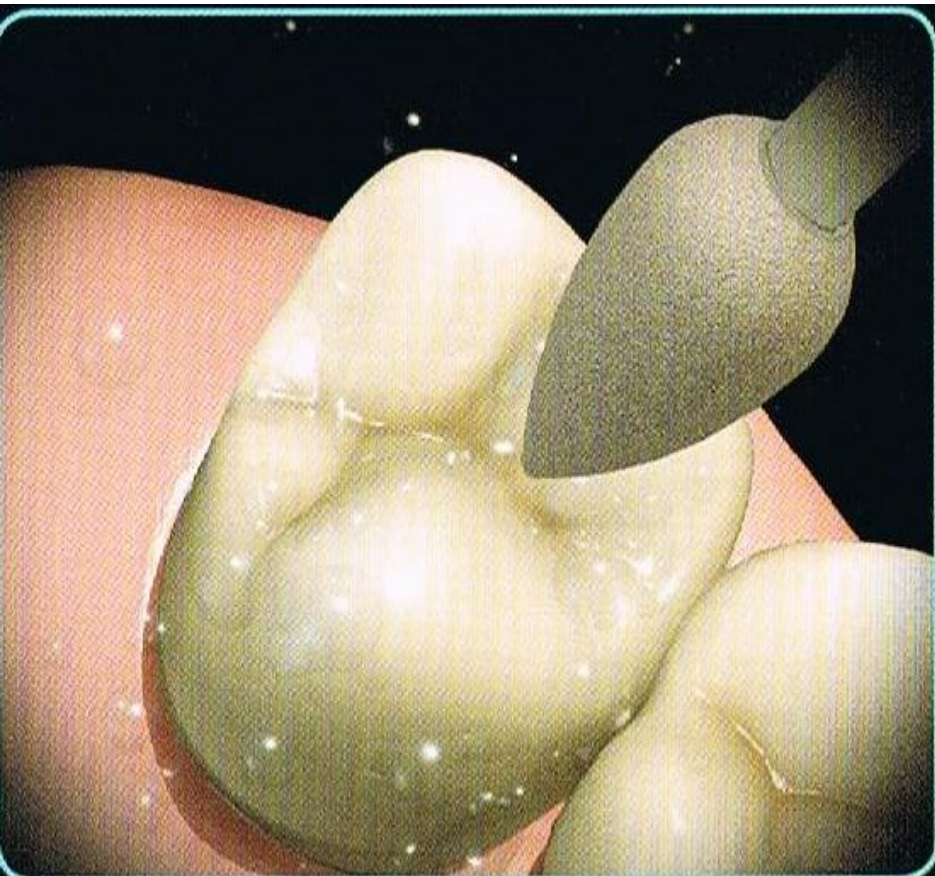


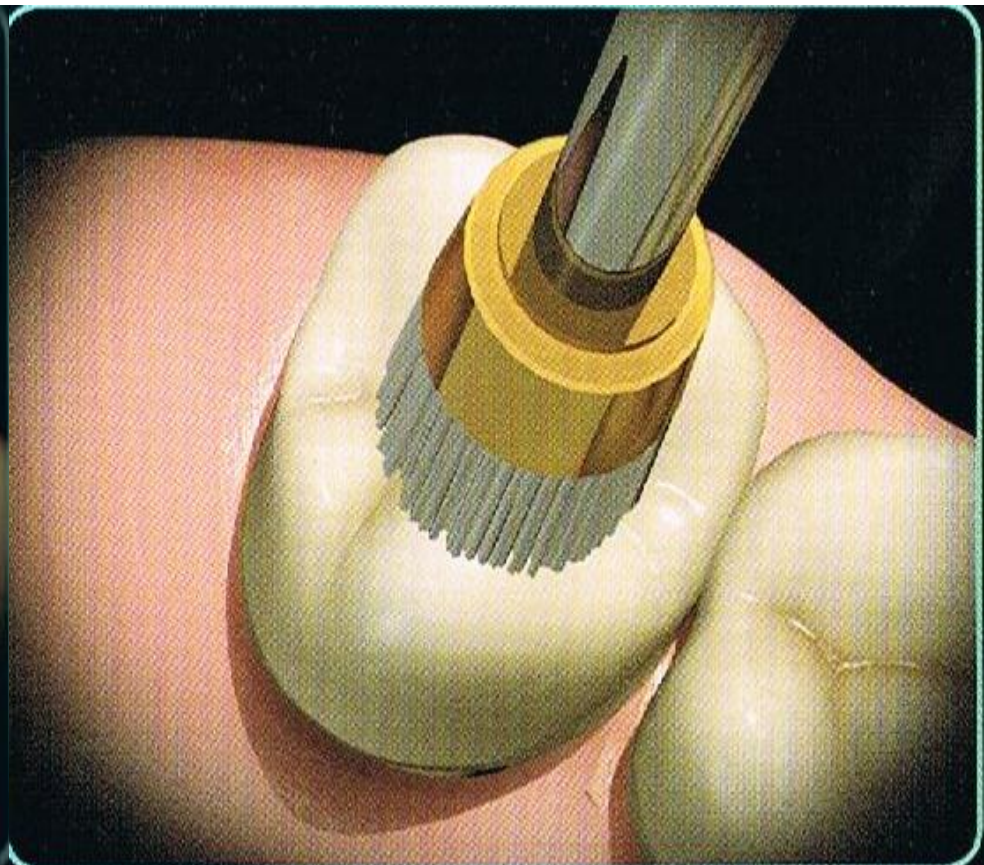


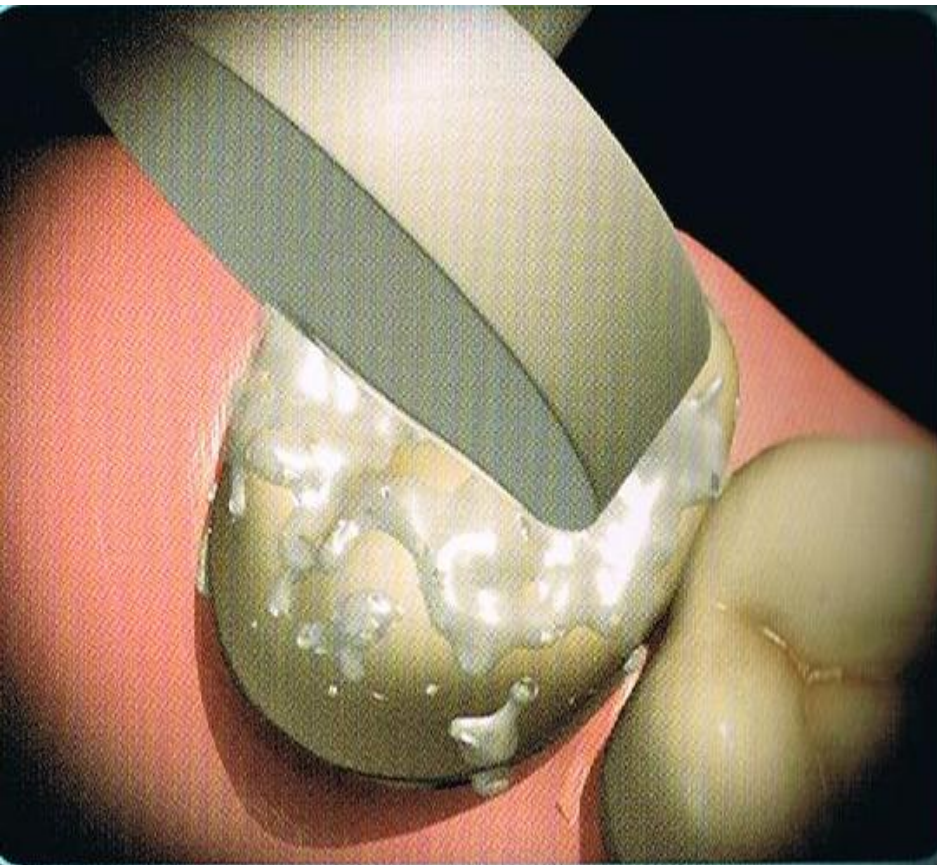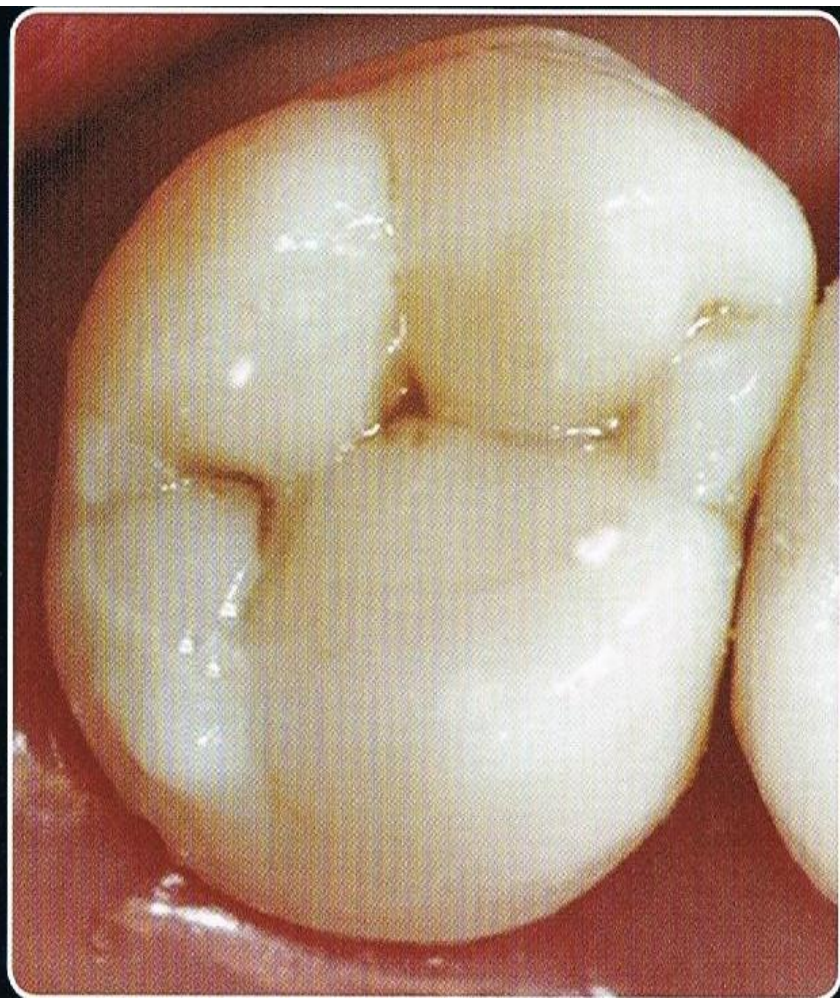
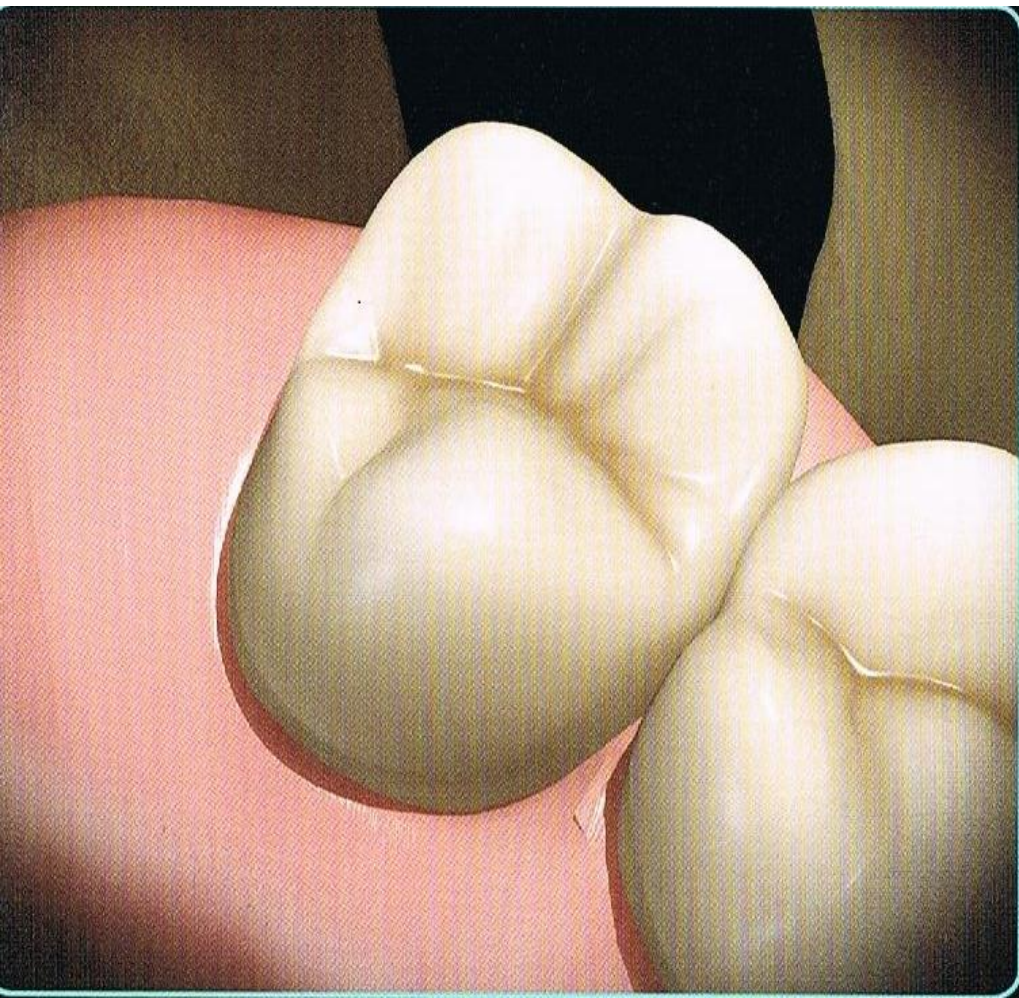












Thank you