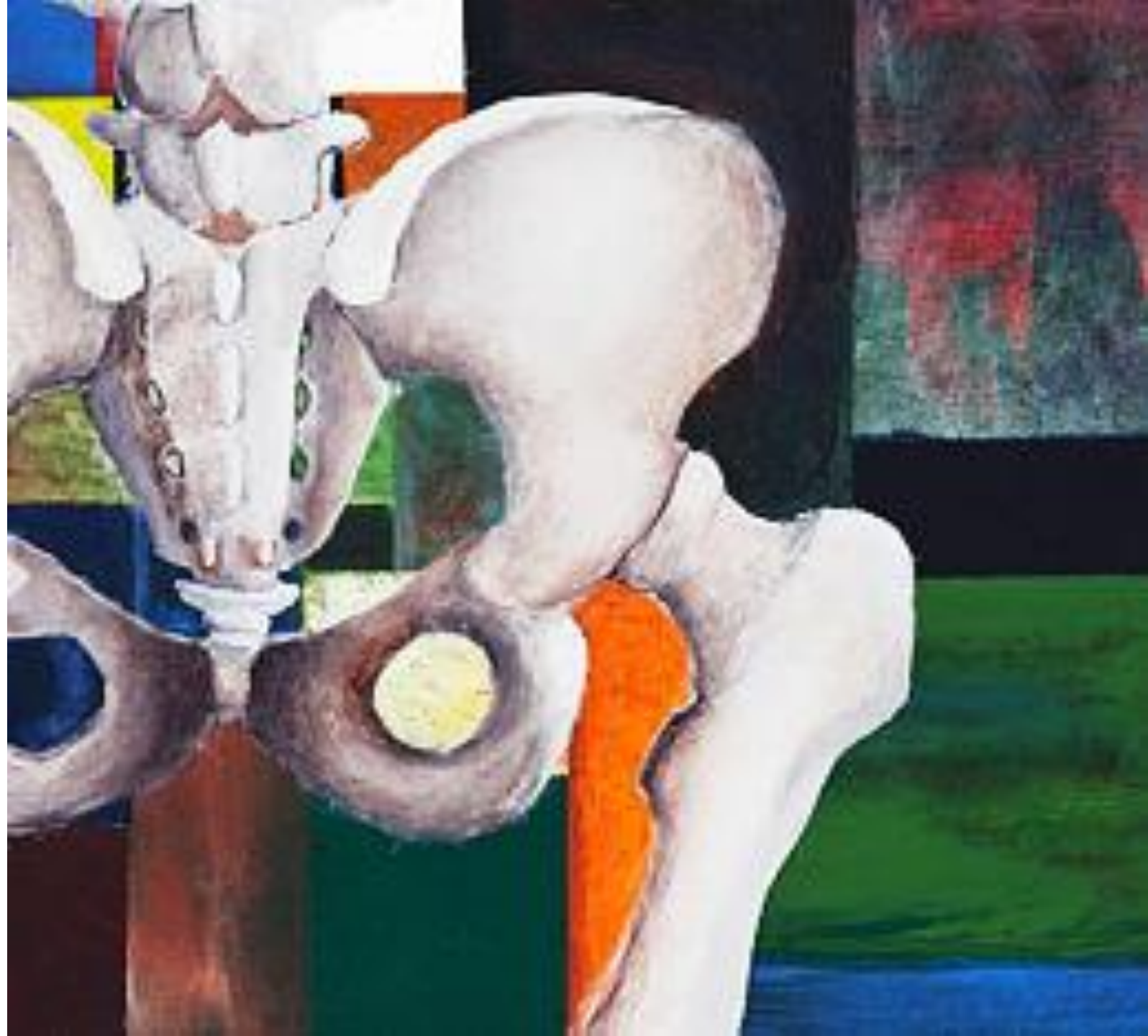

The Anatomy of the Pelvis

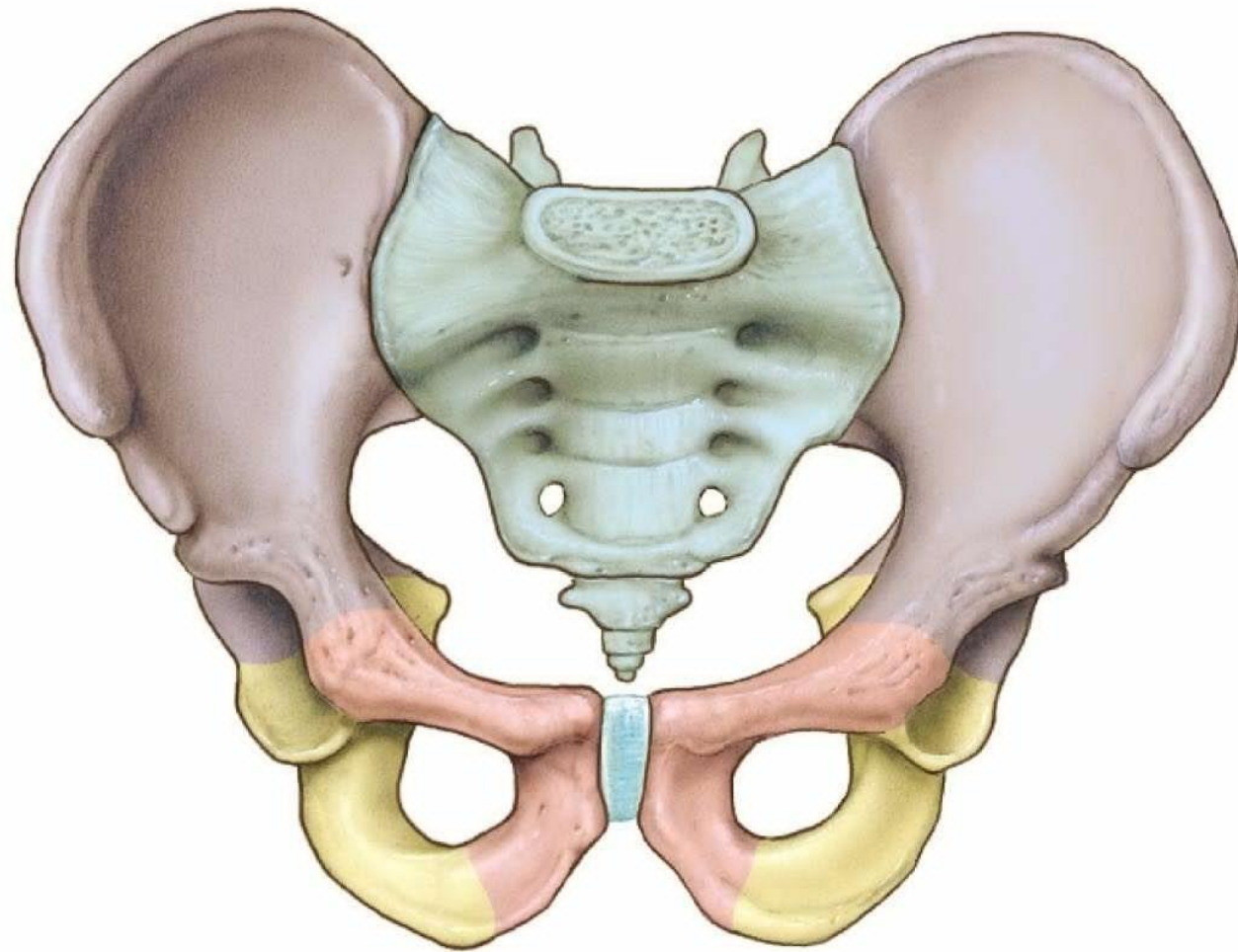
Dr Maan Al-Abbasi

PhD, MSc, MBChB, MD

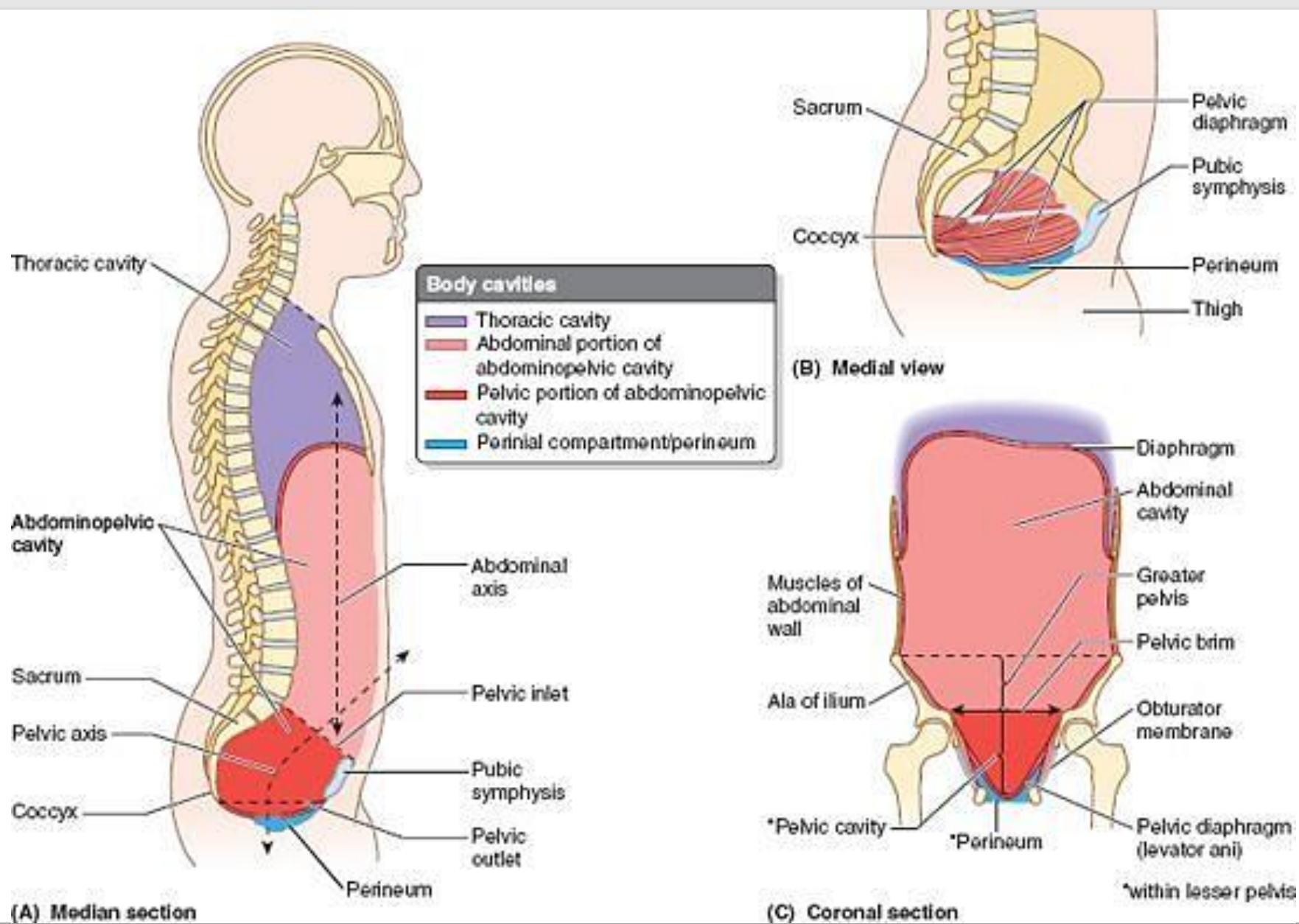


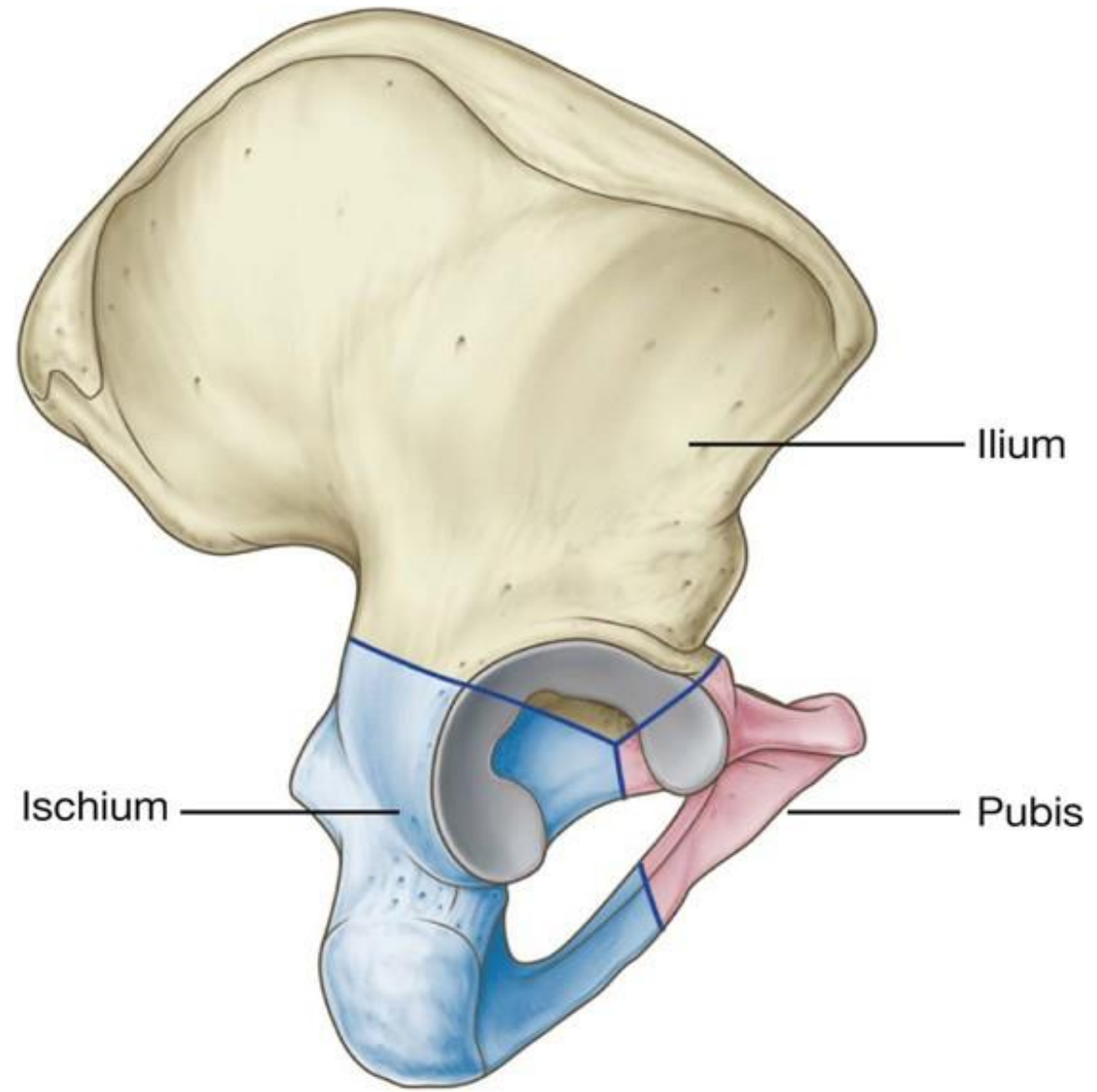
Learning Objectives

Define	The pelvis
Describe	The pelvic floor
Identify	The pelvic inlet and outlet
Describe	The bony Pelvis, pelvic joints and ligaments
Describe	The pelvic walls and floor



(a)



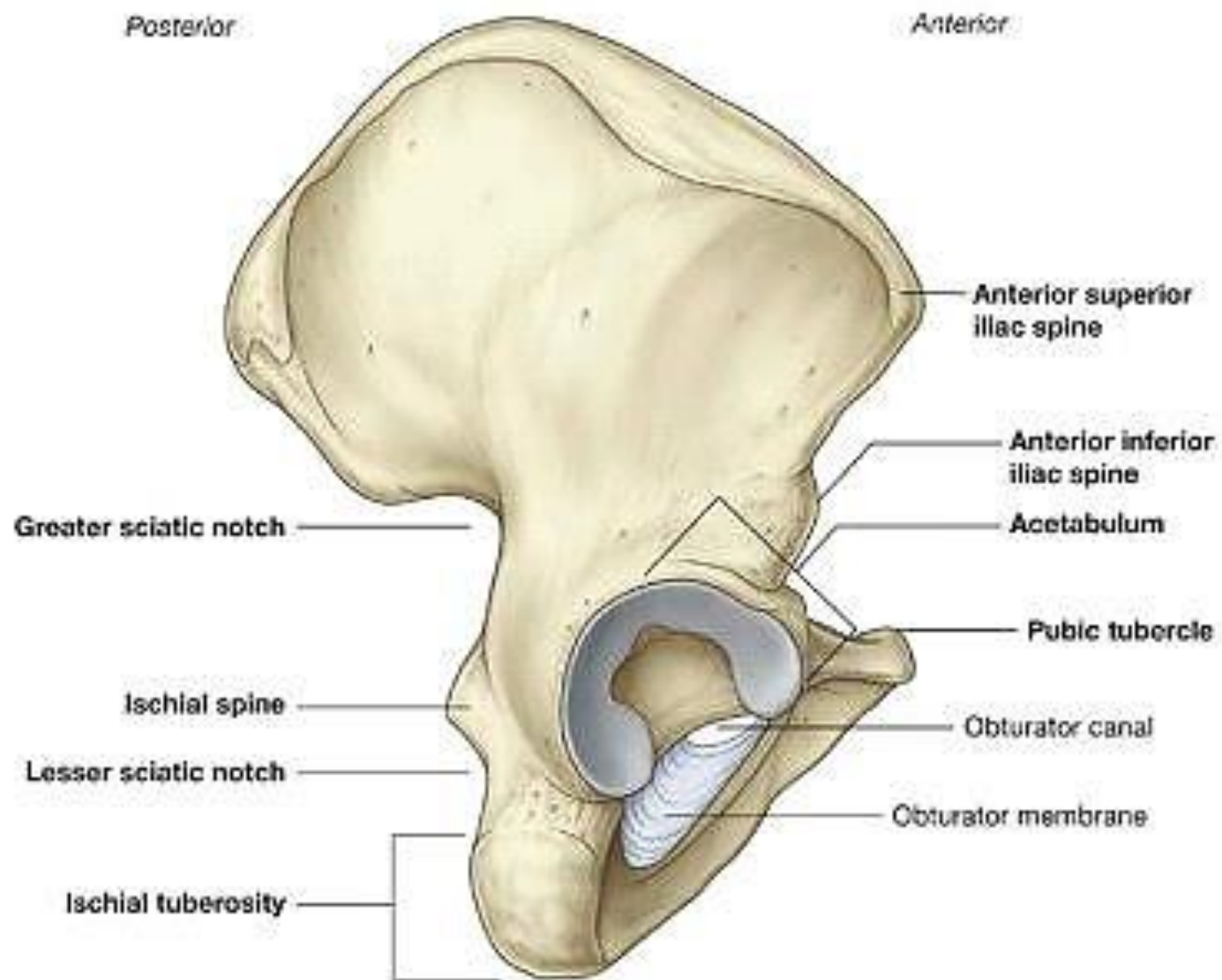


Ilium

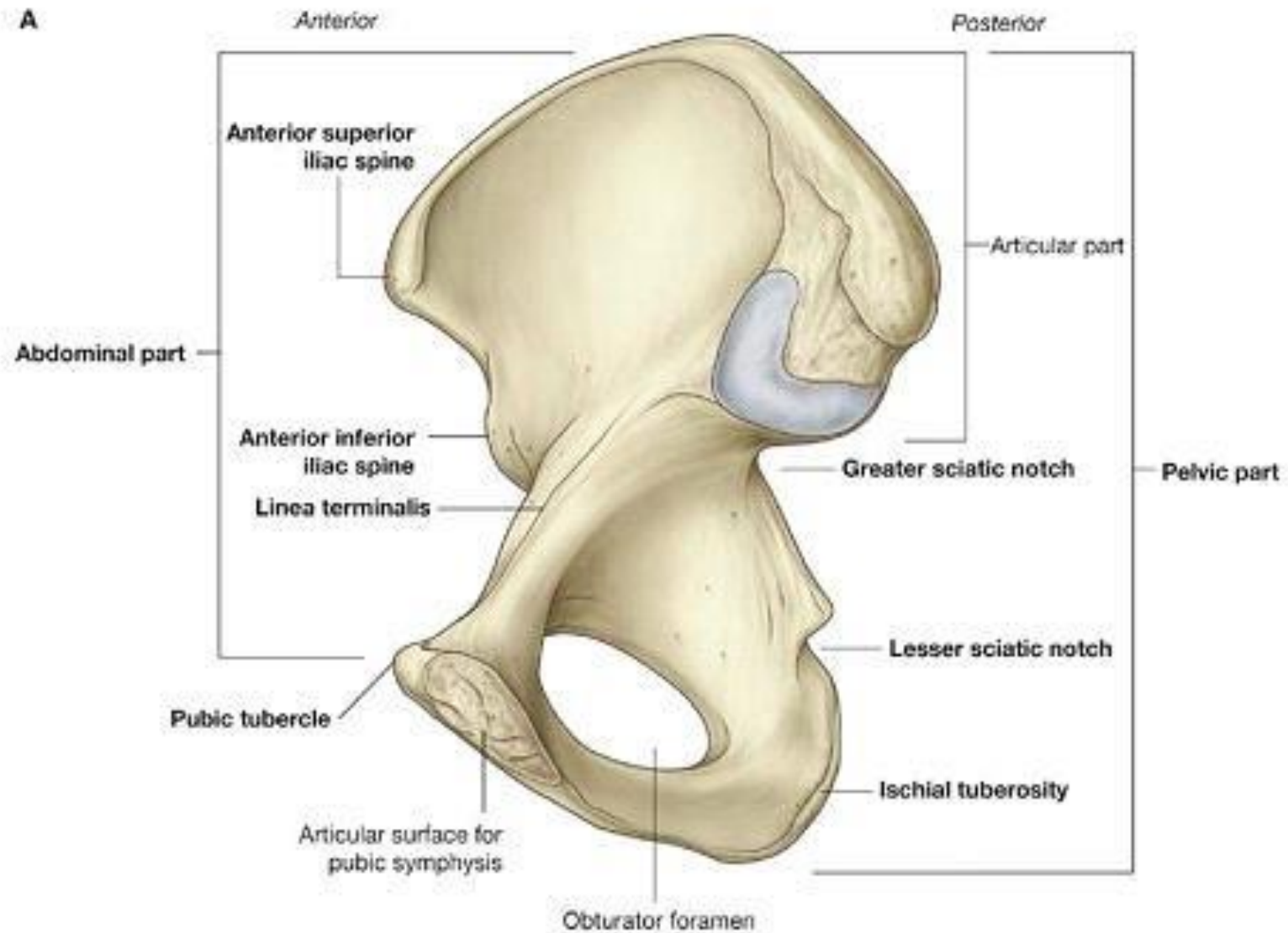
Ischium

Pubis

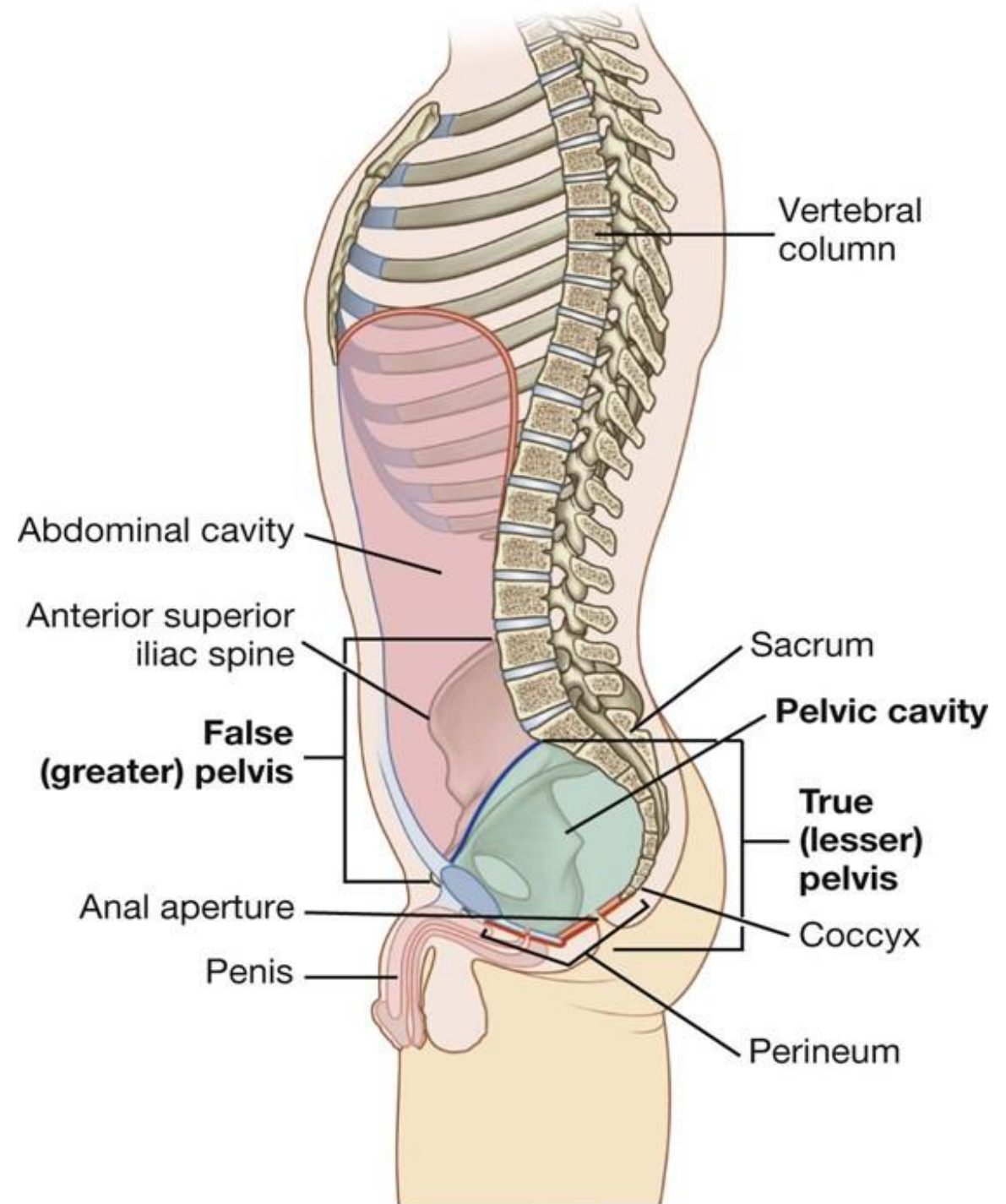
B



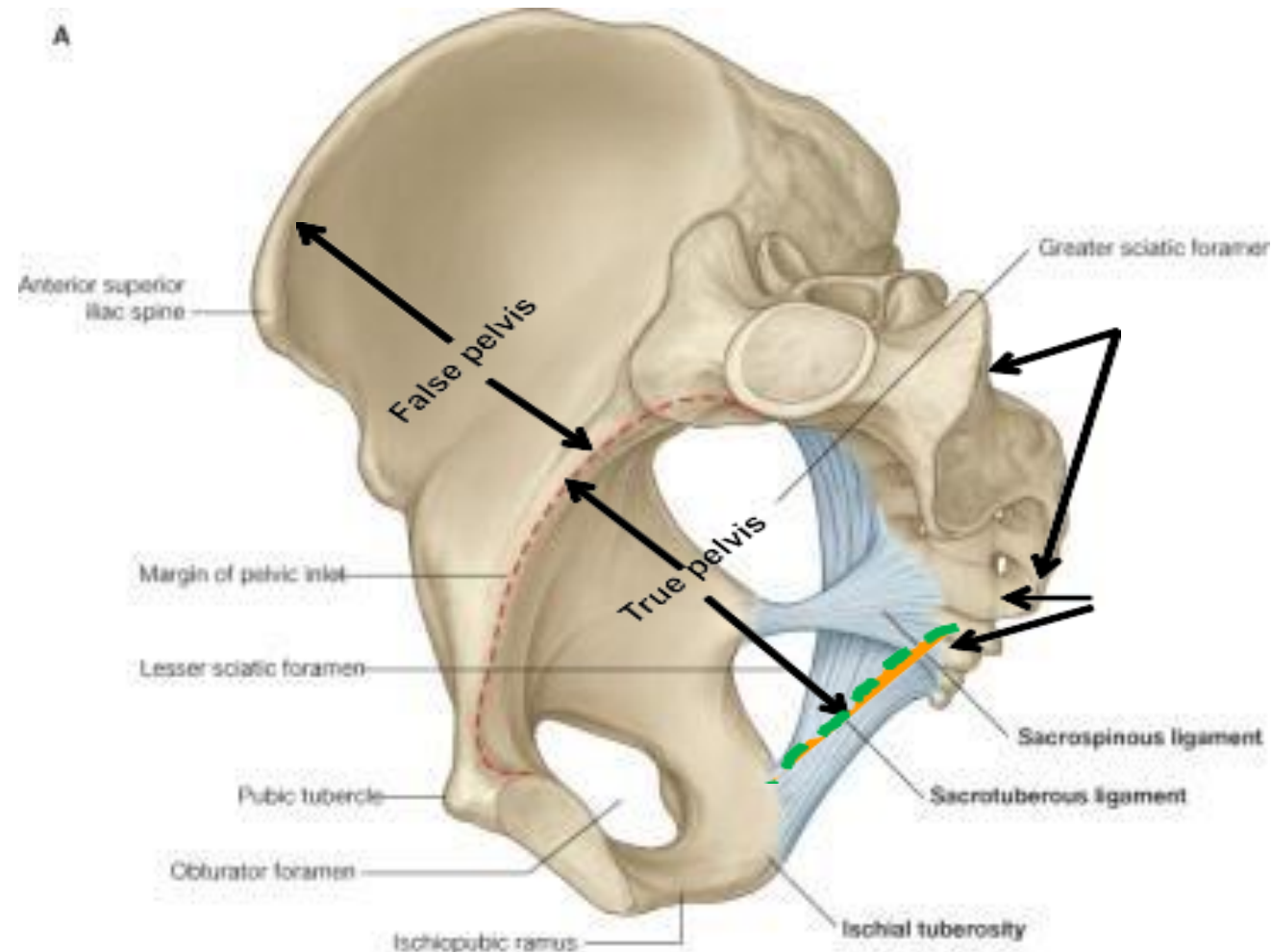
A



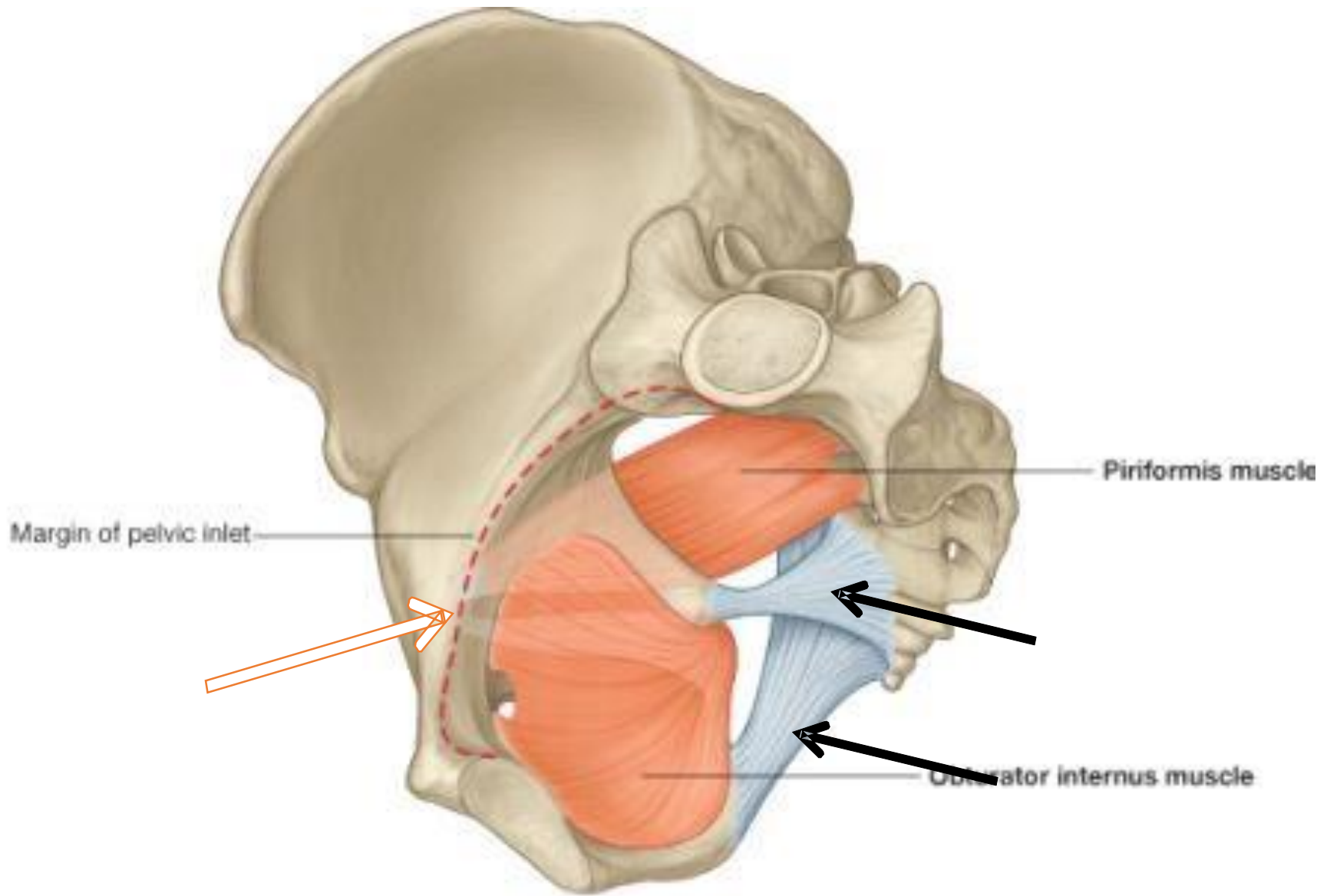
The bowl-shaped pelvic cavity enclosed by the true pelvis consists of the pelvic inlet, walls, and floor.

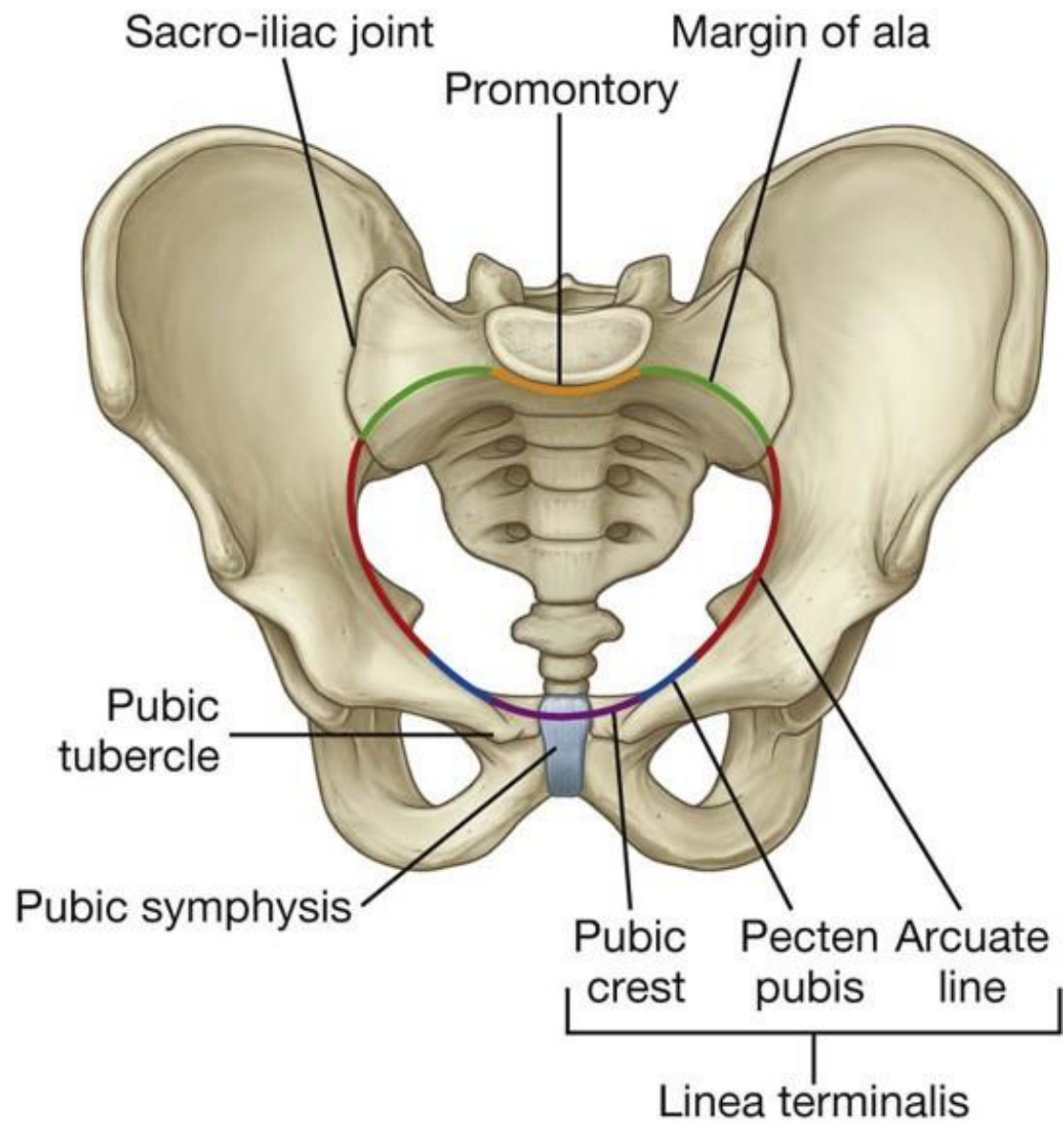


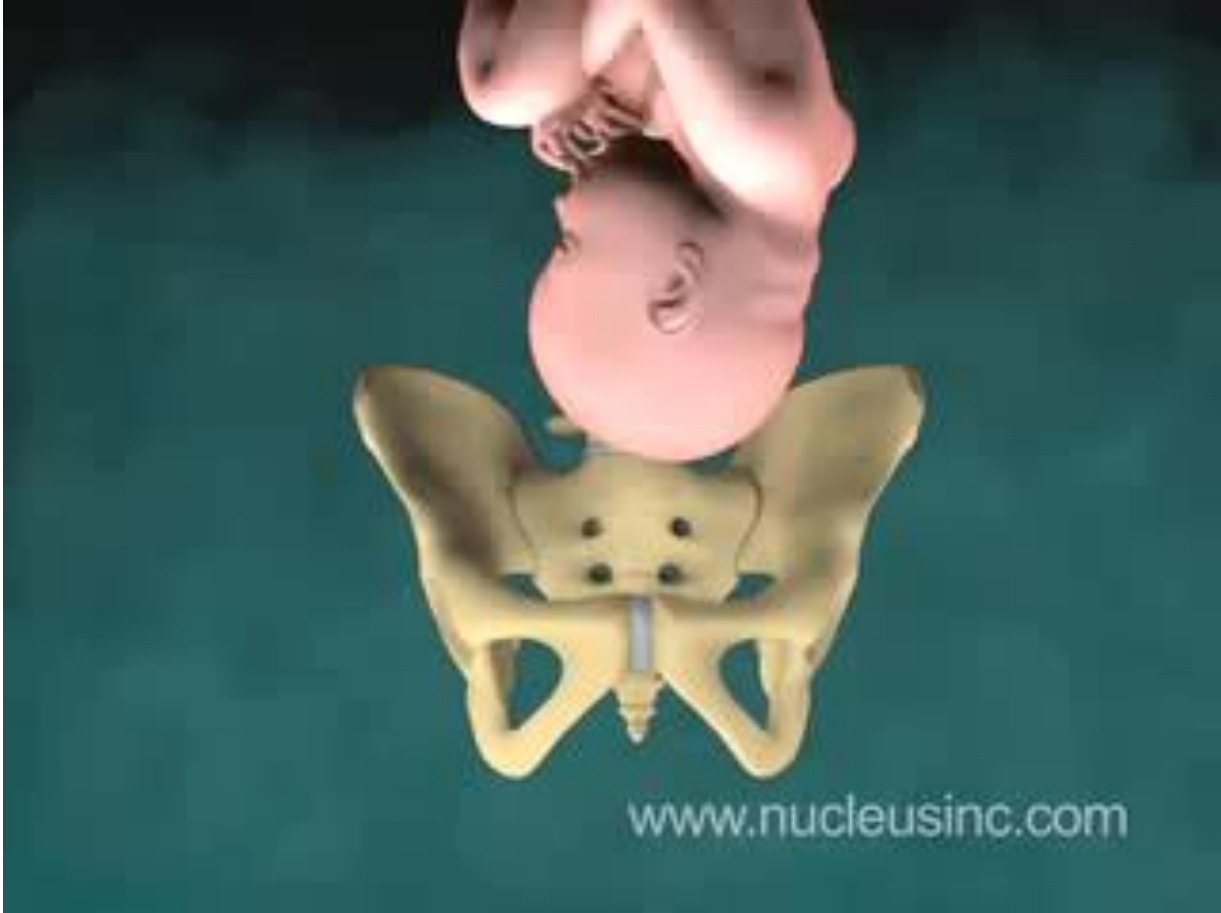
- Child during birth has to leave through pelvic inlet. Siatic notches are the curved parts of pelvis that are divided by the sacrospinous ligament.



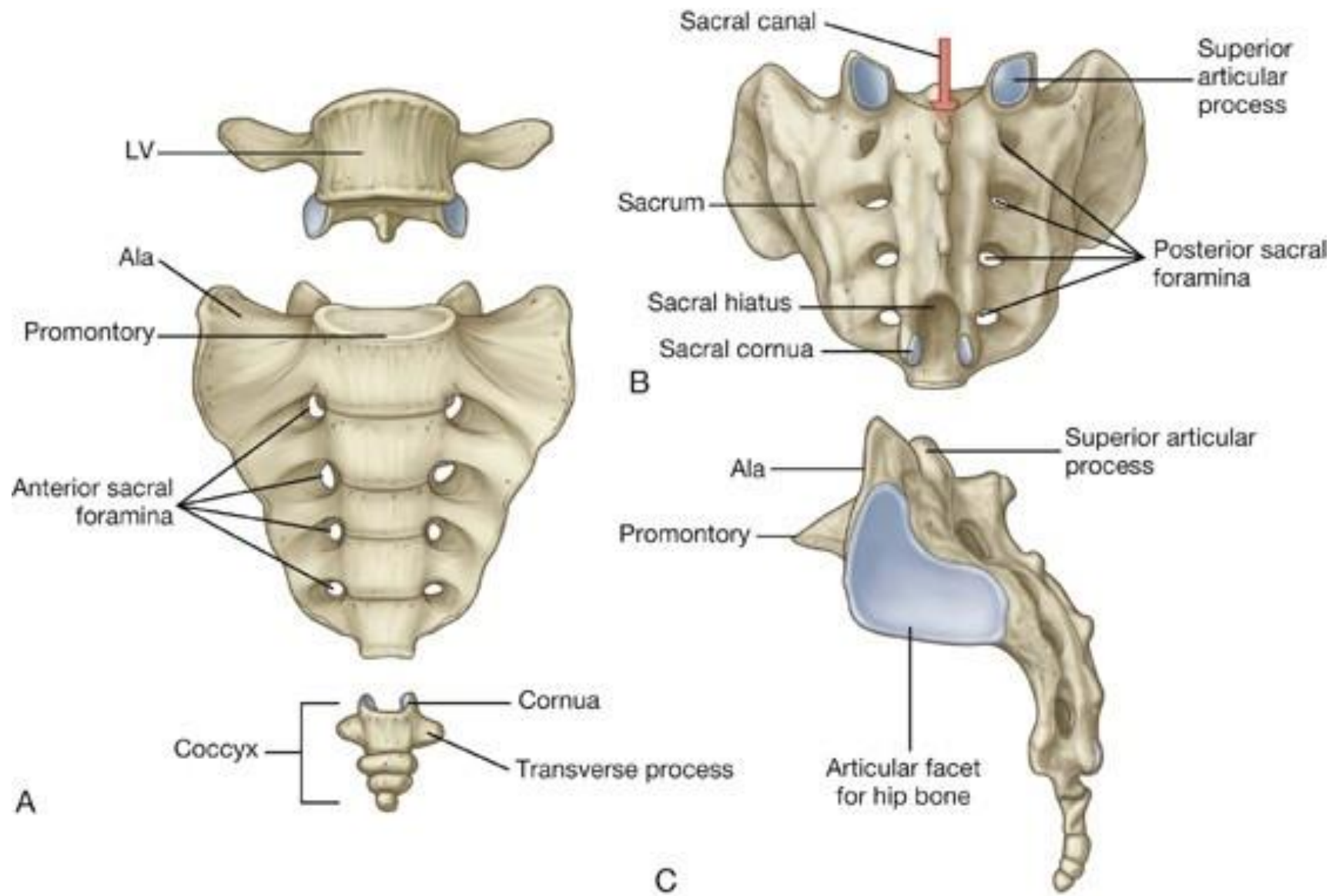
B







Joints & Ligaments



Anterior longitudinal ligament

Intervertebral foramen for L5 nerve

Zygapophysial joint

Intervertebral disc

For posterior sacro-iliac ligament

Promontory

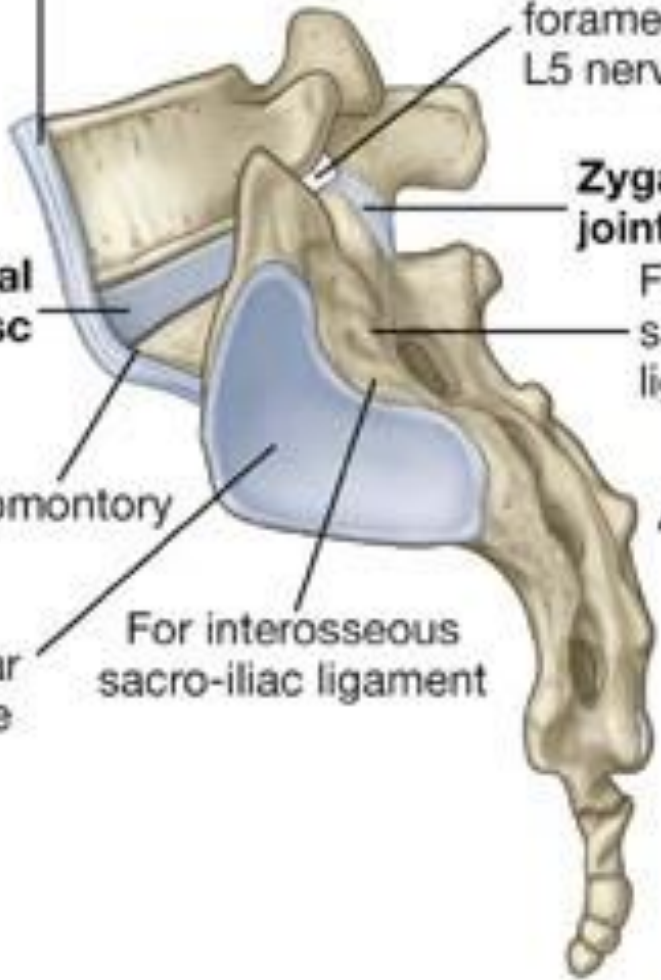For interosseous sacro-iliac ligament

Articular surface

Anterior sacro-iliac ligament

Intervertebral disc

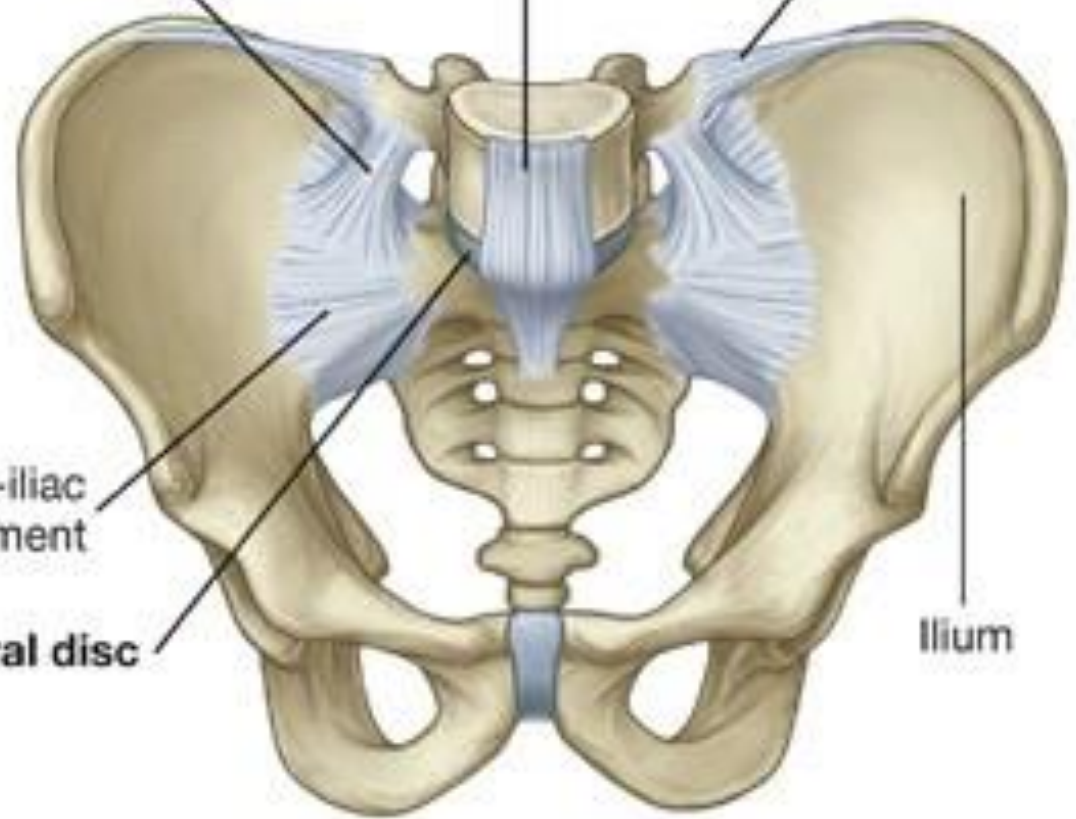
A



Lumbosacral ligament

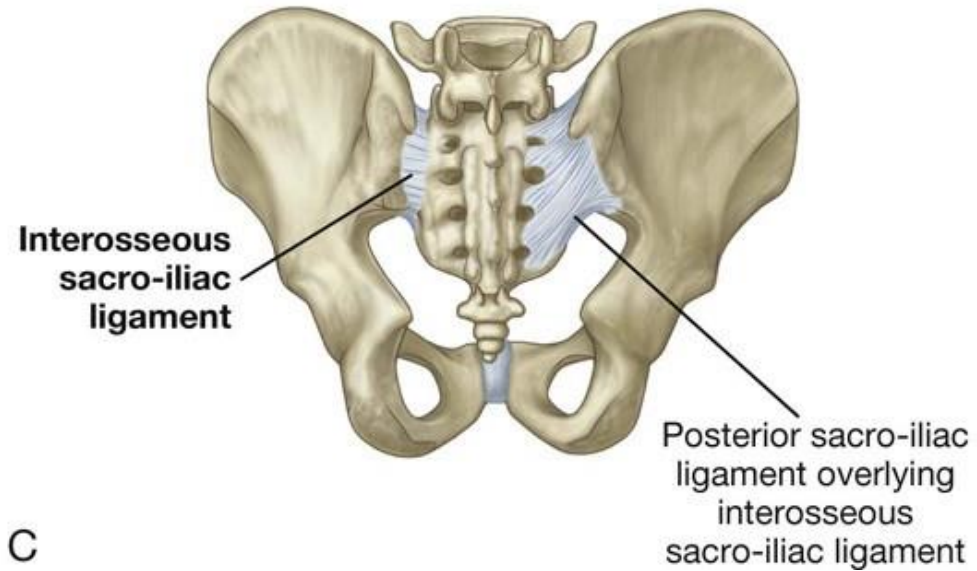
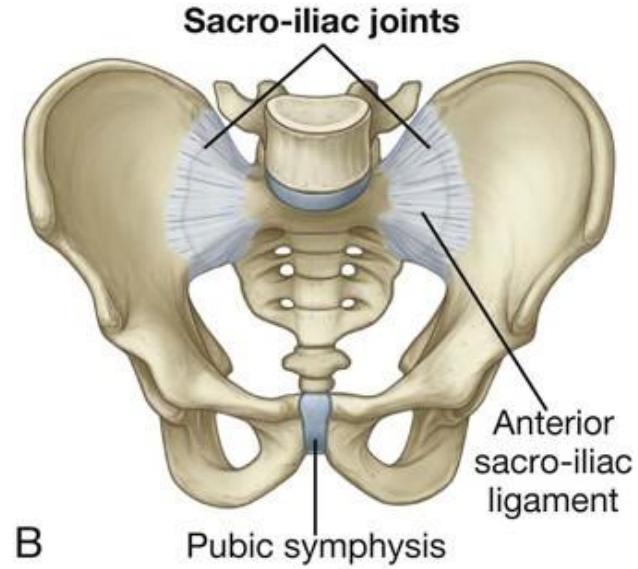
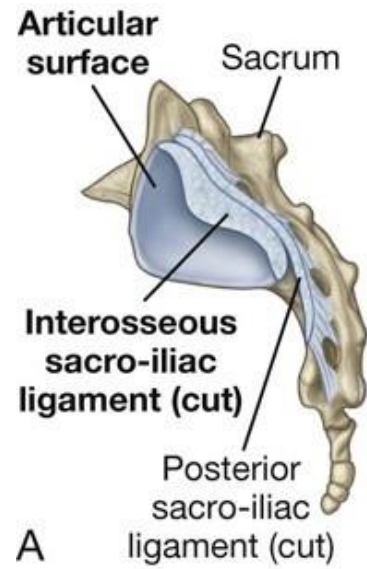
Anterior longitudinal ligament

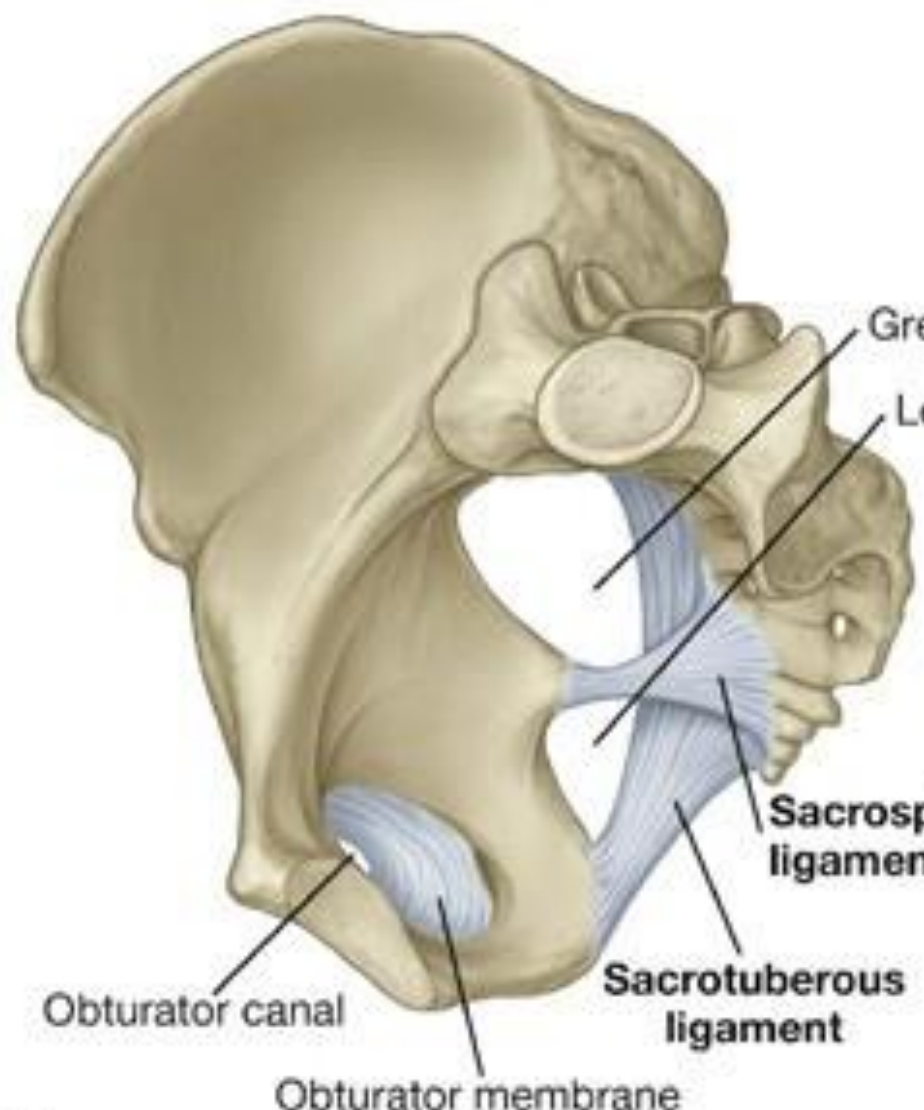
Iliolumbar ligament



B

Ilium





A

Greater sciatic foramen
 Lesser sciatic foramen

Sacrospinous ligament

Sacrotuberous ligament

Obturator canal

Obturator membrane

Ligaments prevent upward tilting of sacrum

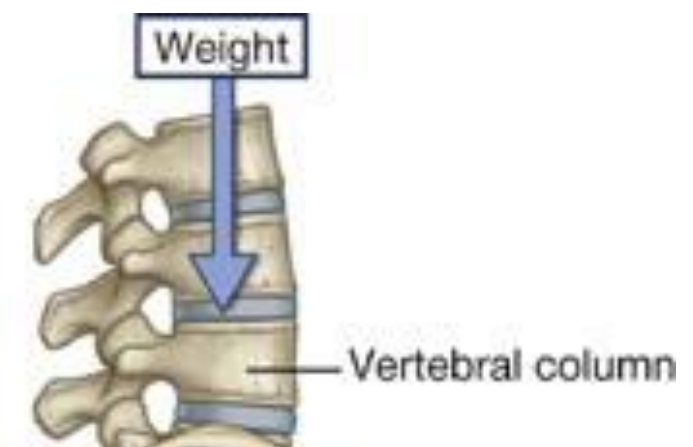B

Greater sciatic foramen

Sacrospinous ligament

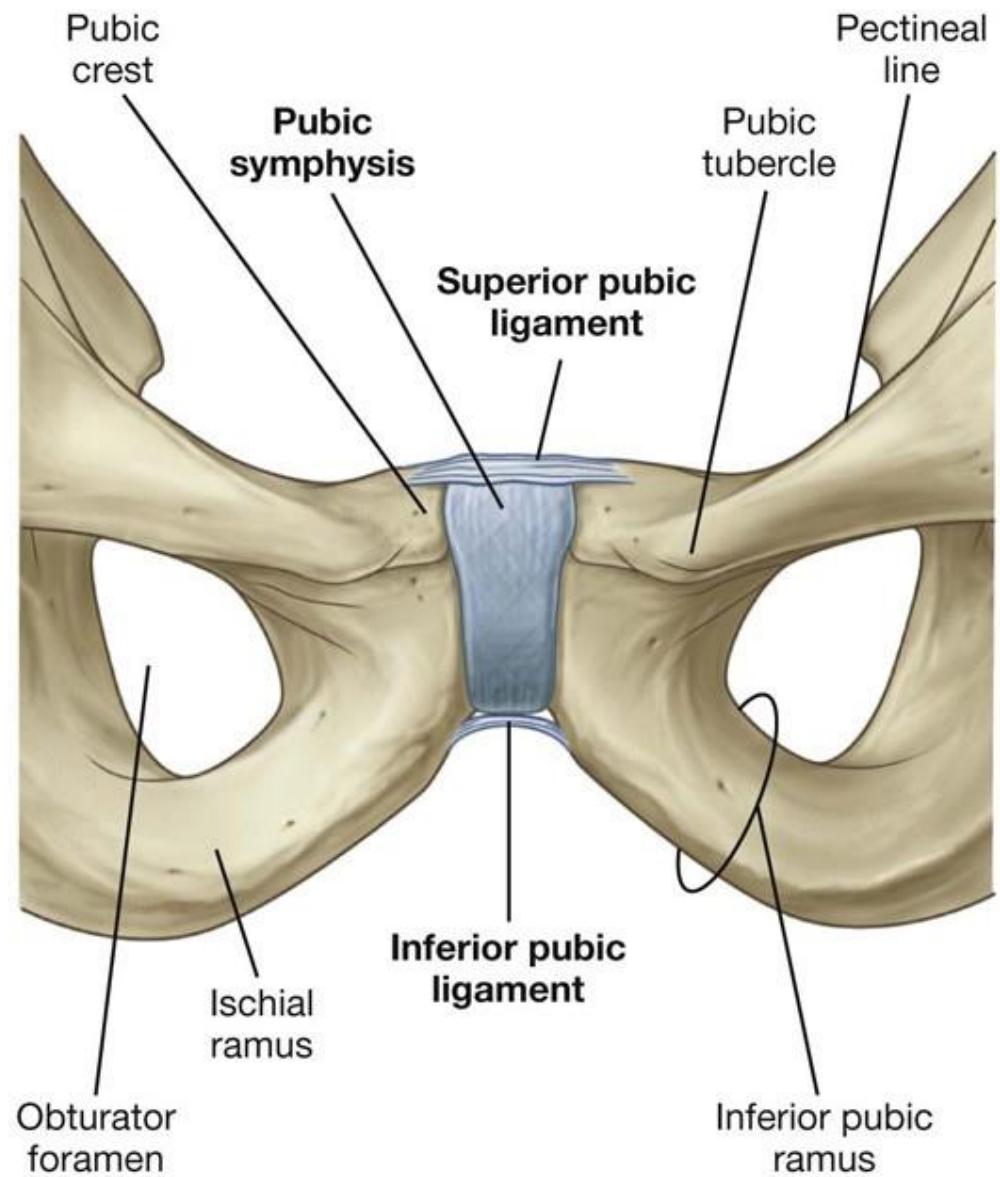
Sacrotuberous ligament

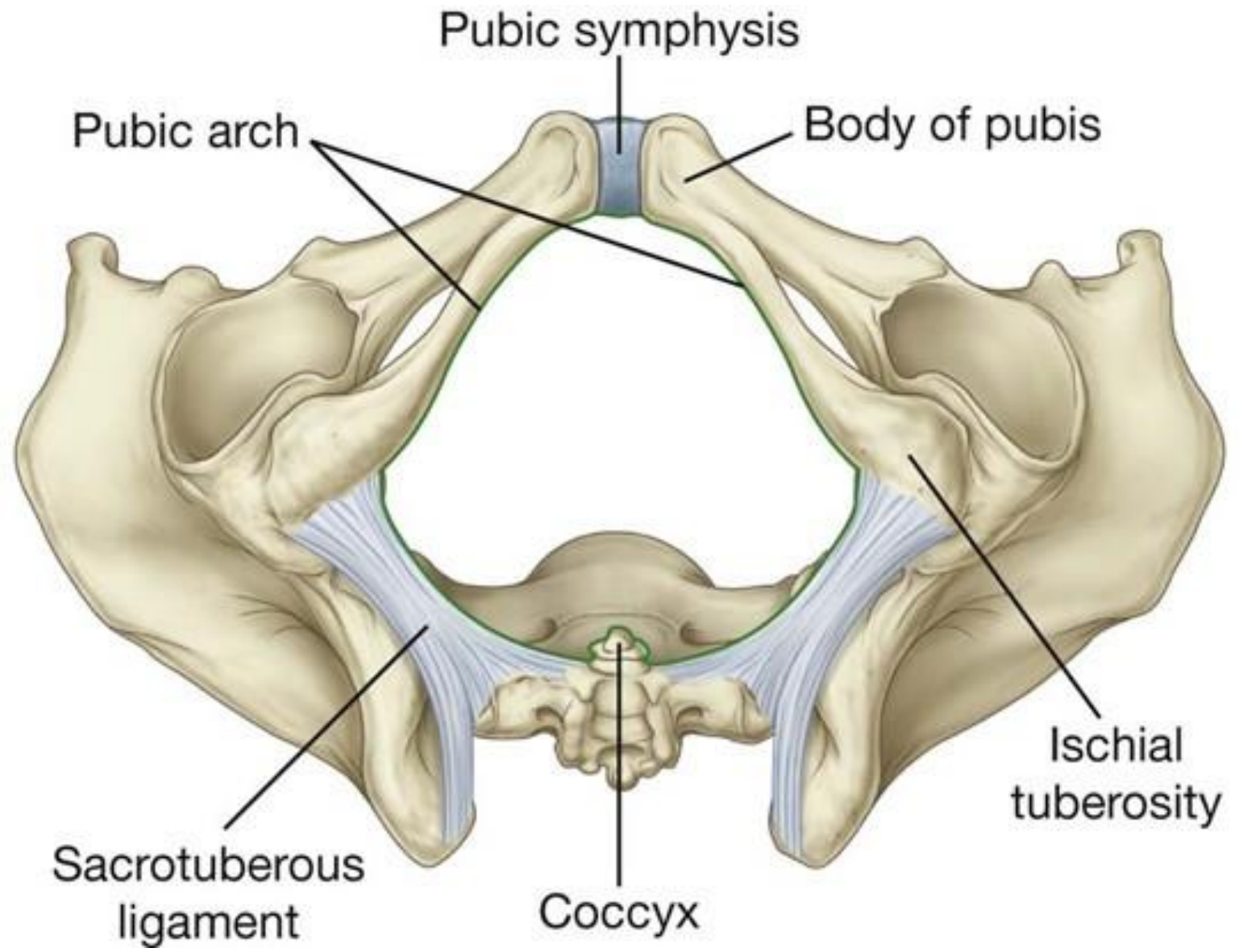
Lesser sciatic foramen



Vertebral column

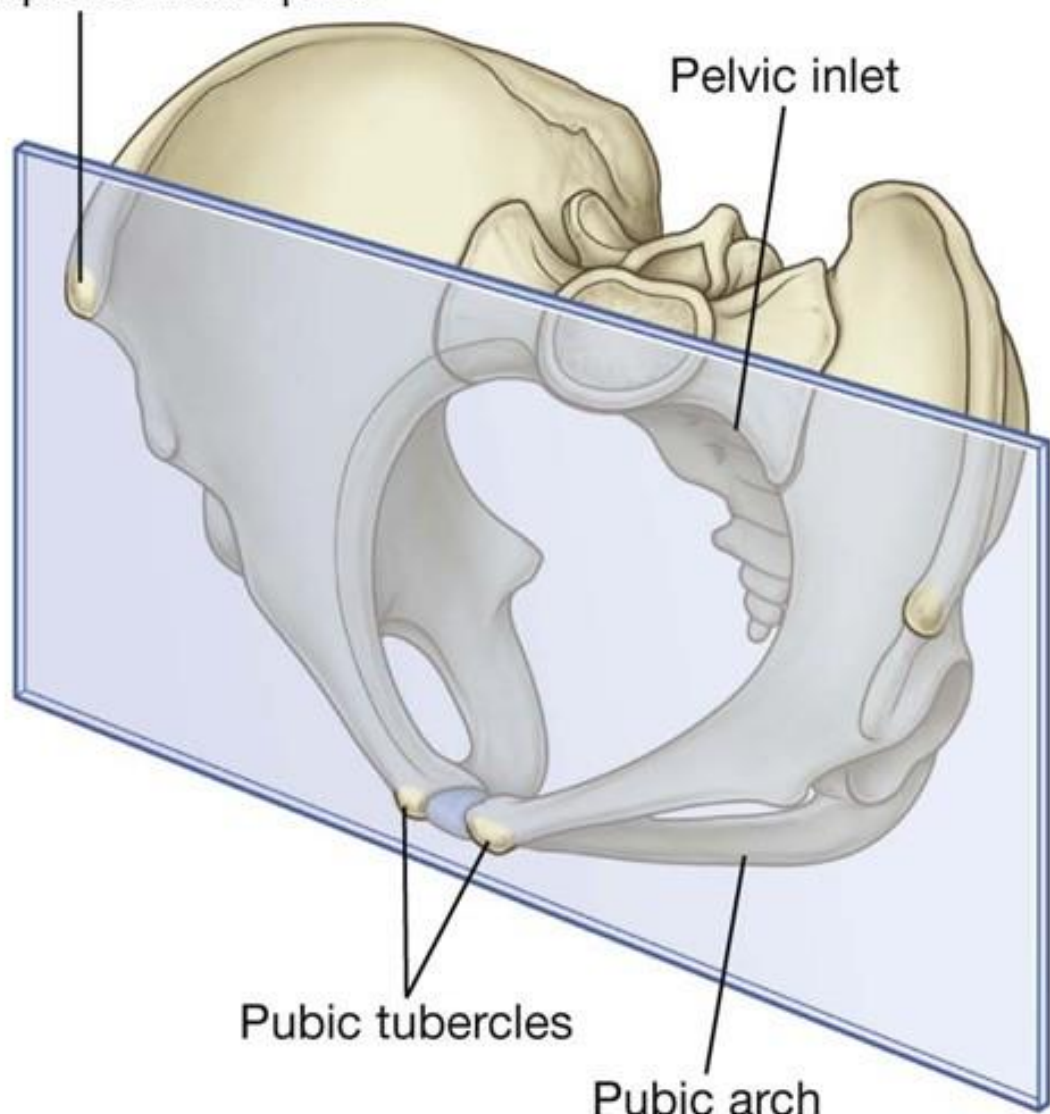
Obturator membrane





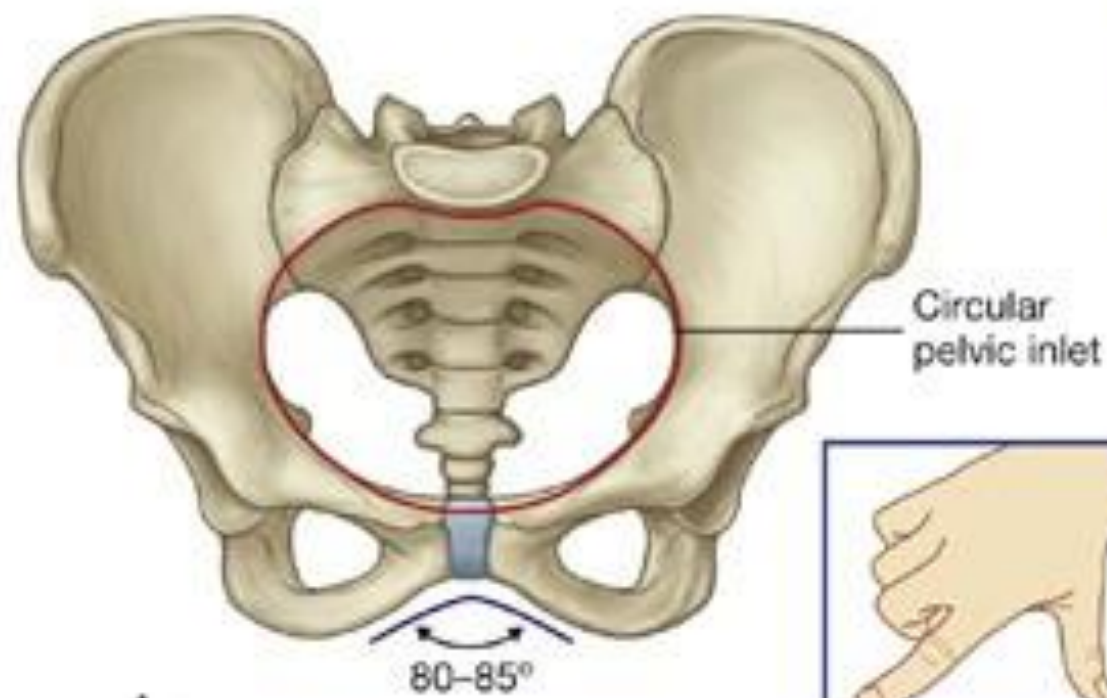
Anterior superior iliac spine

Pelvic inlet

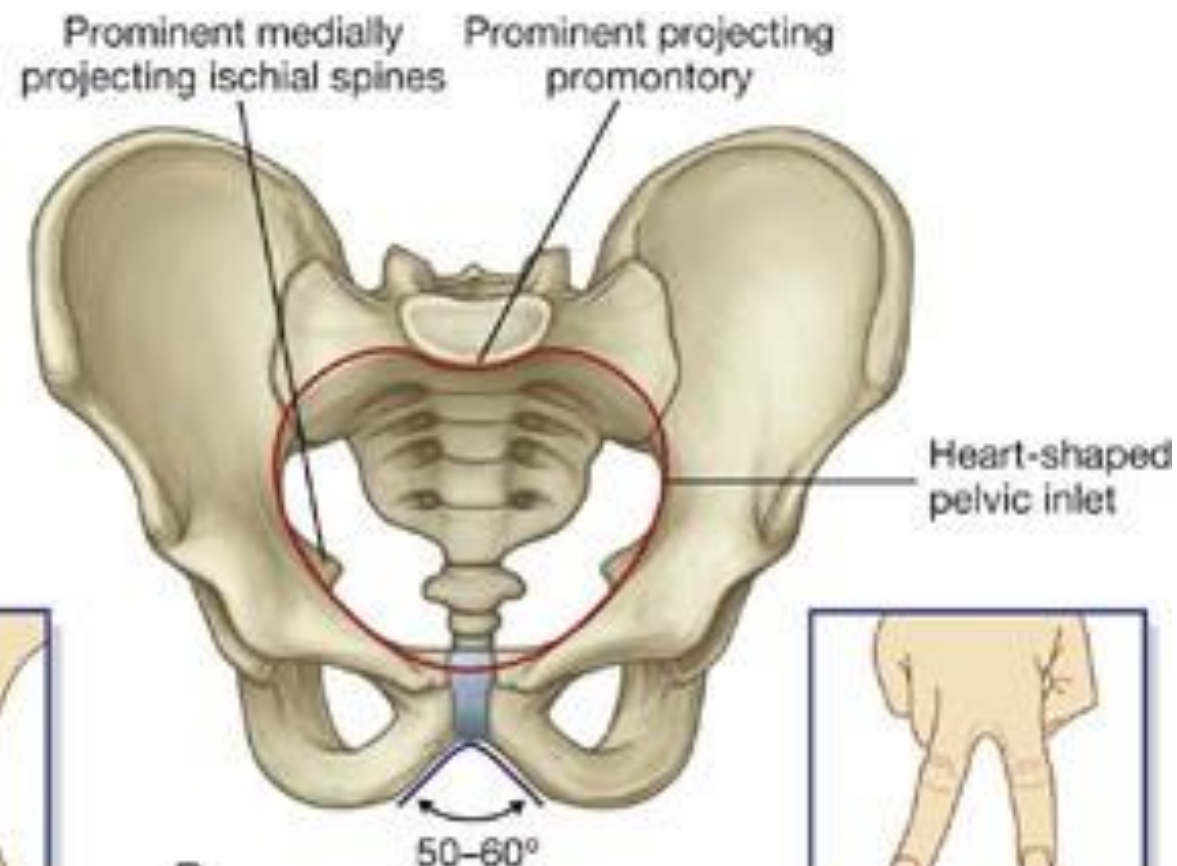


Pubic tubercles

Pubic arch

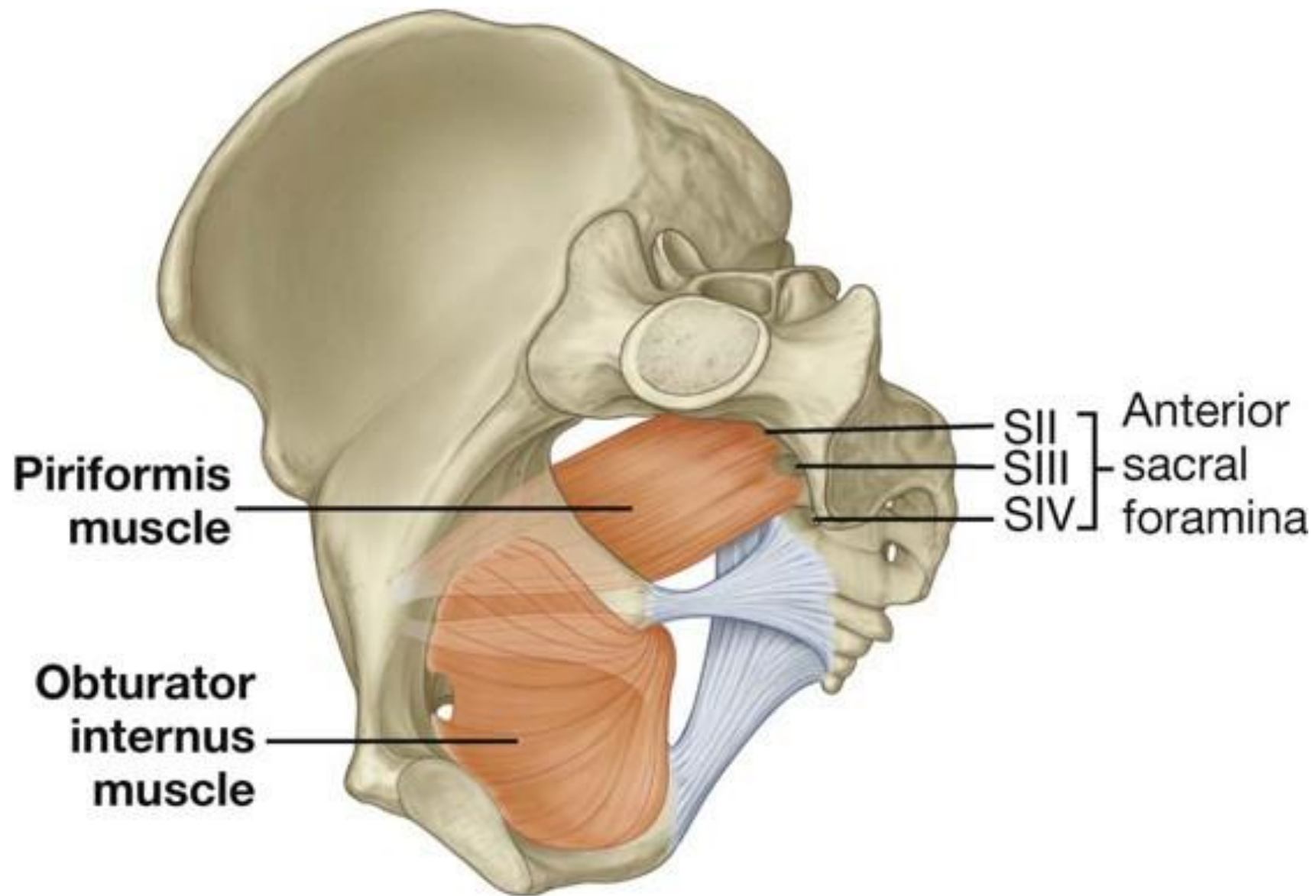


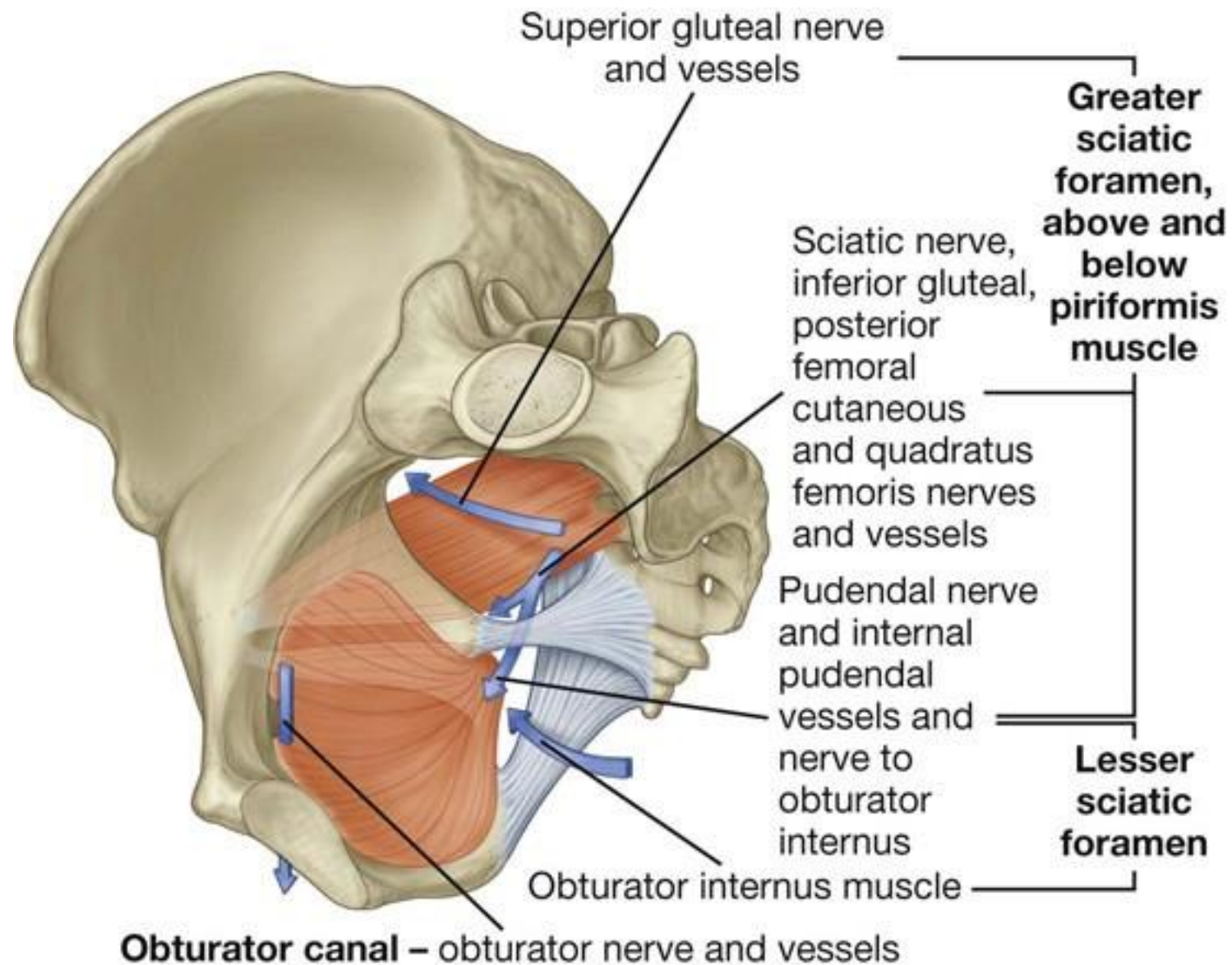
A

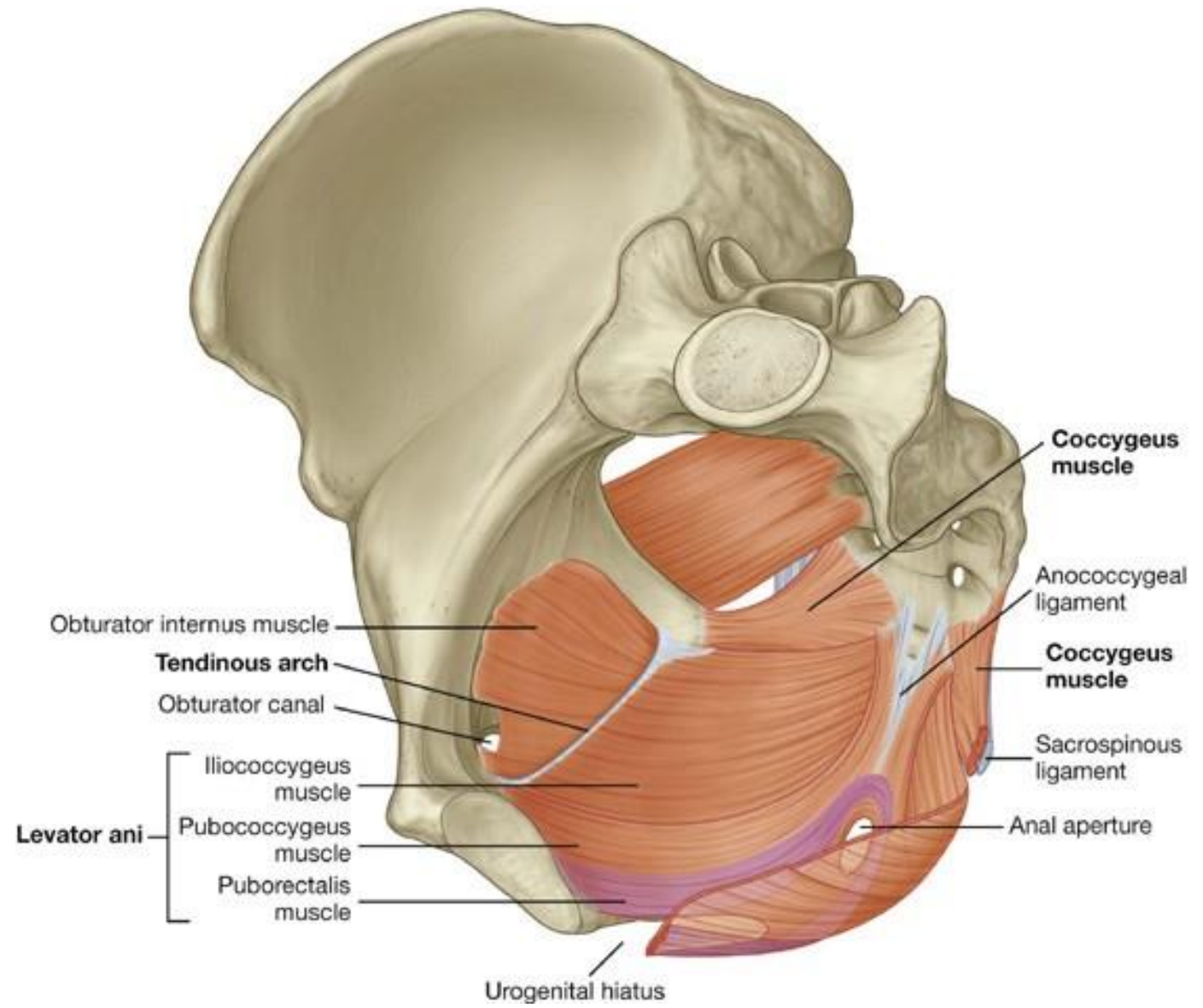


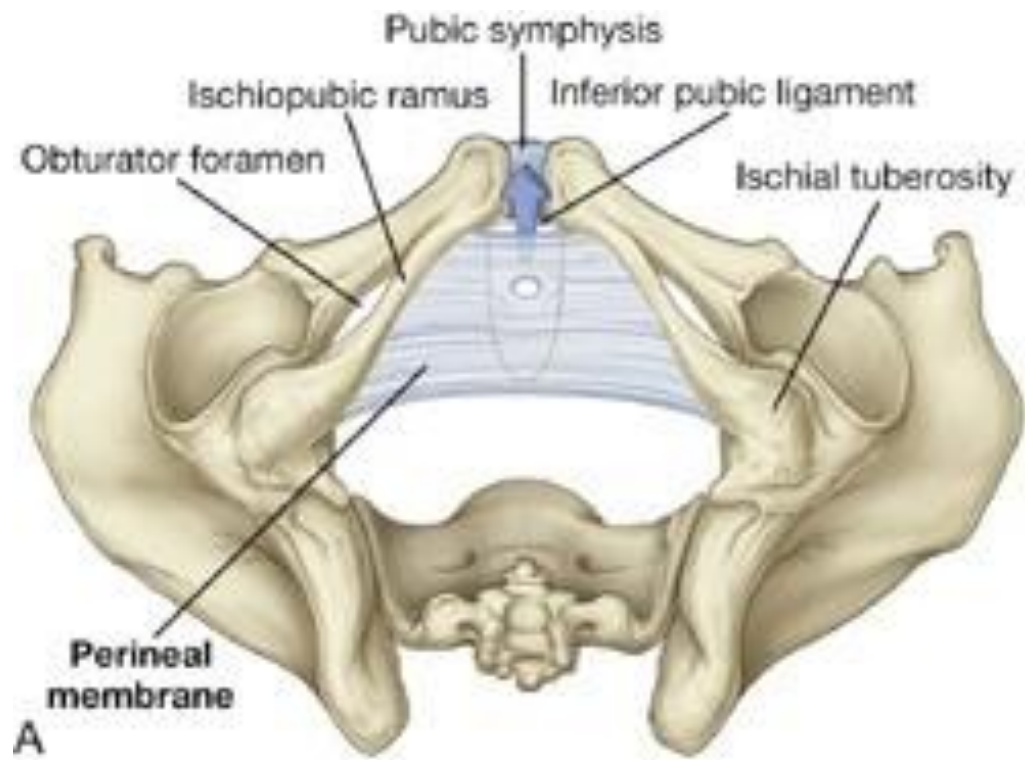
B

Muscles of the Pelvic Walls

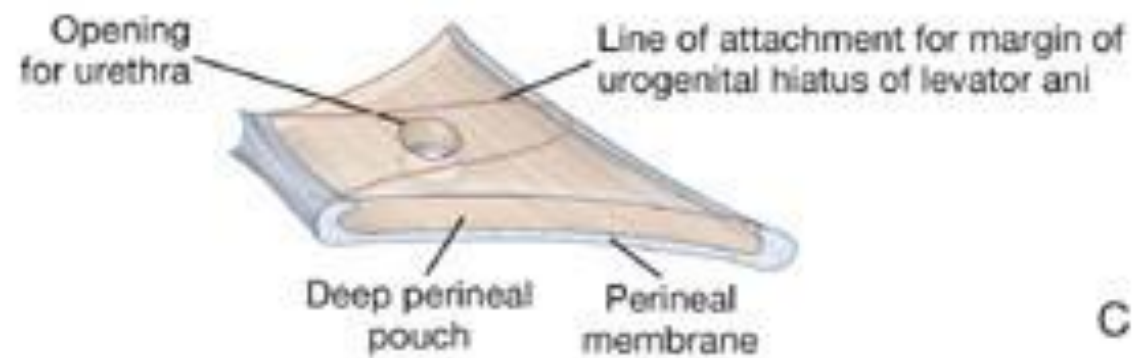




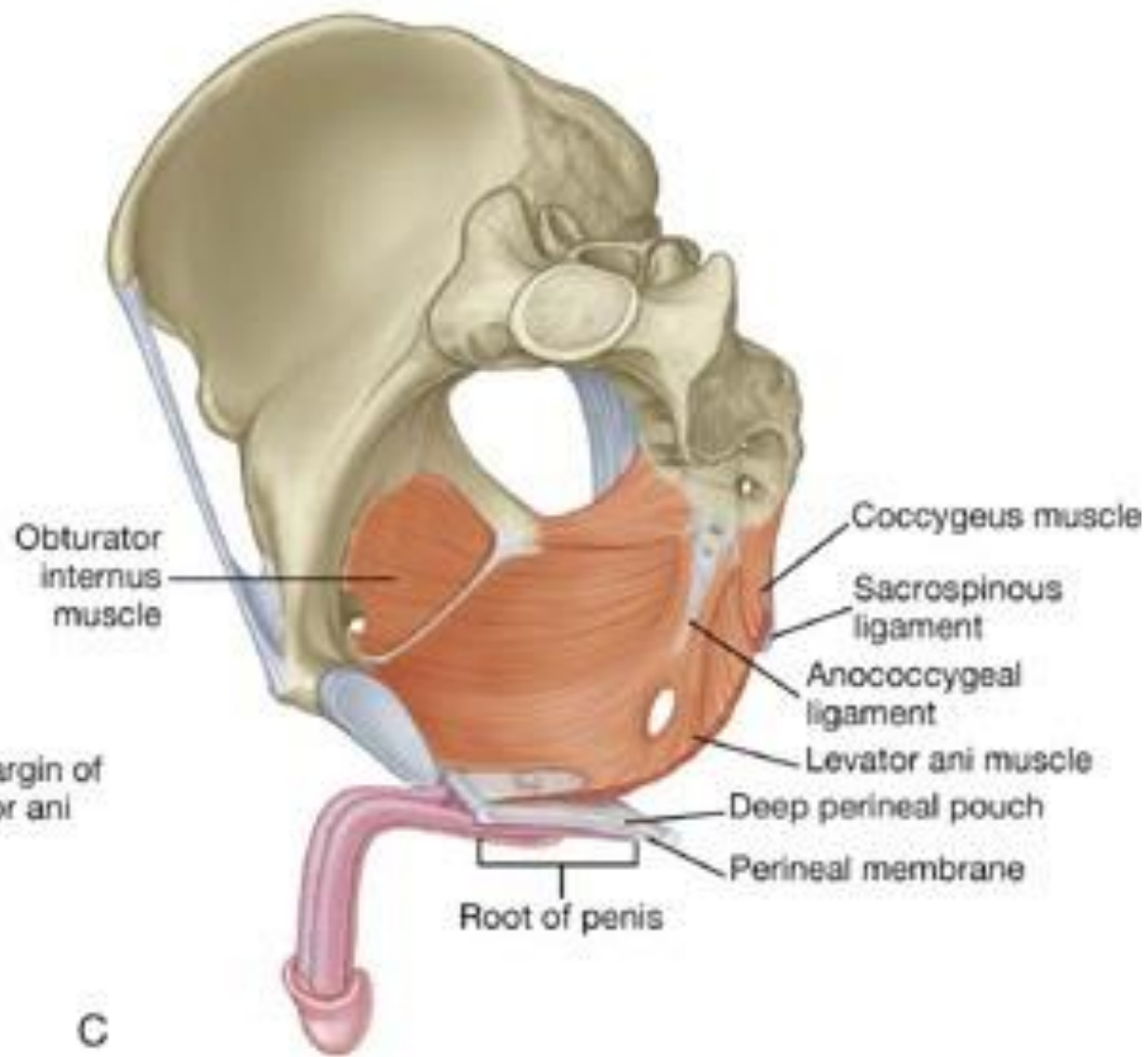




A

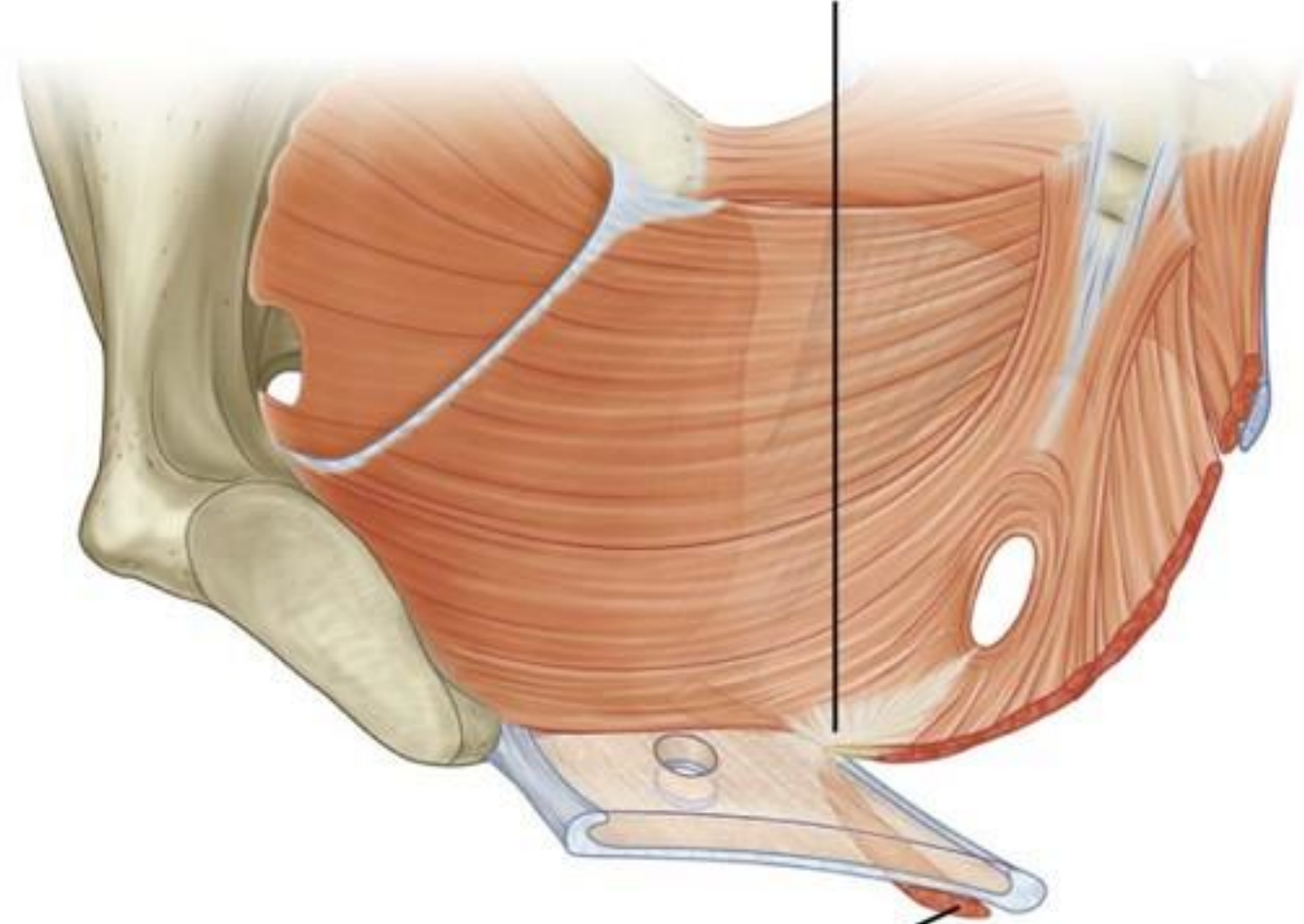


B

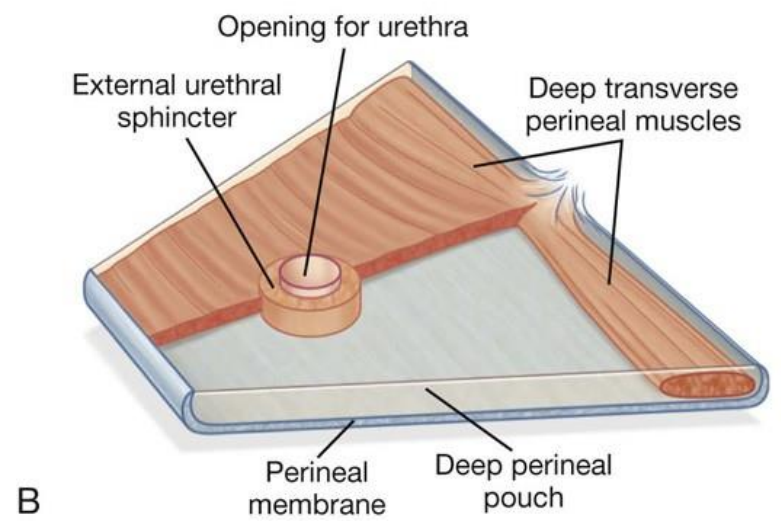
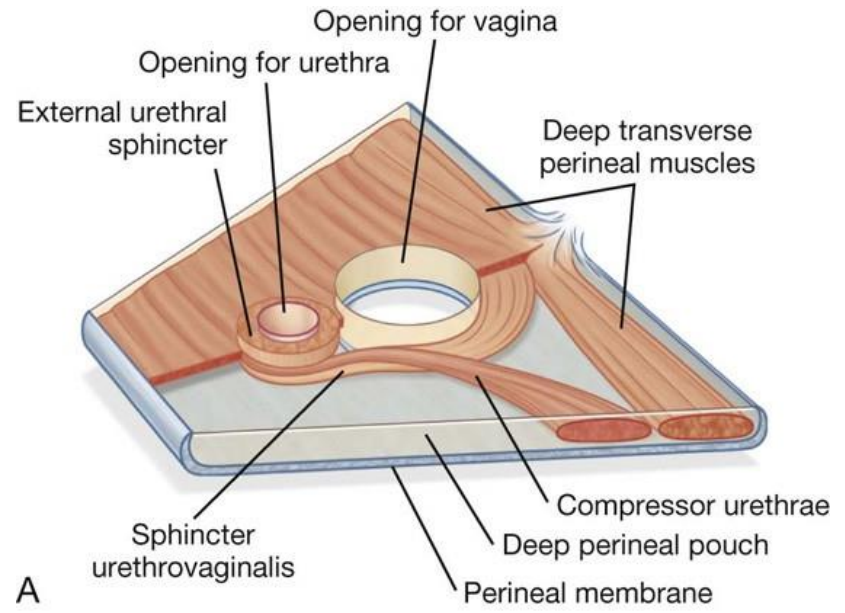


C

Perineal body



Superficial transverse perineal muscle



Tear of Perineum Levator Ani And Pelvic Fascia

Tear of Pubococcygeus The Main Part of The Levator Ani

During Childbirth

