Lymphoreticular system

Objectives:

At the end of this lecture you must:

1- Know The lymphoid organs and structure of lymph node.
2-Define lymphocytosis and its causes
3-Define glandular fever ,infectious mononucleosis regarding their causative agents, feature and diagnosis.
4-Define lymphadenitis and list its causes.
5- Define lymphopenia and its causes.
6-Define acute nonspecific lymphadenitis .
7-Describe chronic nonspecific lymphadenitis and list its patterns.

Lymphocytes are the immunologically competent cells that assist the phagocytes in defence of the body against infection and other foreign invasion.

◙ Lymphoid Organs:

-The *primary lymphoid organs*:
include the bone marrow and thymus ,where lymphocytes develop in the postnatal life .

- The *secondary lymphoid organs*
in which specific immune responses are generated,include the lymph nodes, spleen and lymphoid tissues of the alimentary and respiratory tracts.

Mucosa-associated lymphoid tissue (MALT) includes

(i) discrete lymphoid structures such as the appendix, Peyer's patches in the submucosa of the intestine and the tonsils and adenoids (collectively referred to as Waldeyer's ring) in the pharynx

(ii) lymphocytes in the submucosa of various organs.

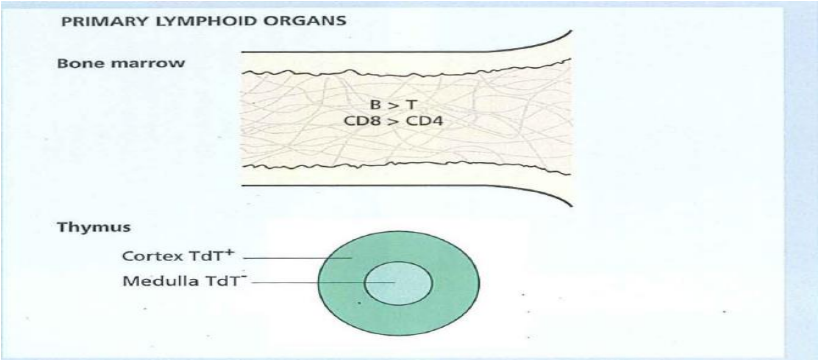

The structure of lymph node:

Lymph node is divided into:

1.<u>Cortex</u>: Within the cortex are primary follicles, which are

composed of B lymphocytes and follicular dendritic cells. On antigen exposure , proliferation and maturation of B cells cause the primary follicle to develop into a secondary follicle comprising a germinal centre surrounded by a mantle zone of small B lymphocytes. Outside the mantle zone some lymph node germinal centres have a marginal zone, also composed of B lymphocytes.

2.<u>paracortex :</u>T cells occupy the paracortex, which surrounds and underlies the primary and secondary follicles. The paracortex also has abundant dendritic cells.

3. **<u>medulla.</u>** In the centre of the lymph node ,it composed of medullary cords and sinuses. The medullary cords are occupied by B and T lymphocytes, plasma cells and macrophages.

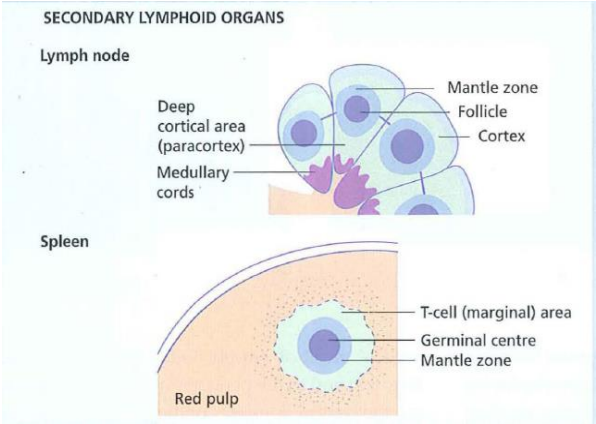

Normal lymphocyte counts is 1-3x10 ^{9}/l (20-40%)

***Lymphocytosis

an increased number of lymphcytes in the peripheral blood.

<u>Causes of lymphocytosis :</u>

1.Infections

<u>- Acute :</u> *infectious mononucleosis, rubella, pertussis,* mumps, infectious hepatitis, cytomegalovirus, HIV, herpes simplex or zoster

<u>- Chronic :</u> tuberculosis, toxoplasmosis, brucellosis, syphilis

2.Chronic lymphoid leukaenlias .

3.Acute lymphoblastic leukaemia

4.Non-Hodgkin's lymphoma (some)

***Glandular fever*:**
is a general term for a disease characterized by : fever, sore throat, lymphadenopathy and atypical lymphocytes in the blood.
It may be caused by ***primary infection with Epstein-Barr virus (EBV), cytomegalovirus, human immunodeficiency virus (HIV) or toxoplasma.***

EBV infection, otherwise known **as infectious mononucleosis,** is the **most common** cause.

◙ ***Infectious mononucleosis:***
-This is caused by primary infection with EBV.
-In most cases infection is *subclinical.*
The infection is characterized by :
(1) fever, sore throat, and generalized lymphadenitis;
(2) an increase of lymphocytes in blood, many of which have an atypical morphology;
(3) an antibody and T cell response to EBV.

A normal immune response is extremely important in controlling the proliferation of EBV-infected B cells (B lymphocytes have receptors for EBV) and spread of virus.
Early in the course of the infection, IgM, and, later, IgG, antibodies are formed against viral capsid antigens. The latter persist for life.

More important in the control of polyclonal B-cell proliferation are cytotoxic CD8+ T cells and NK cells. *Virus-specific cytotoxic T cells appear as atypical lymphocytes in the circulation, a finding that is characteristic of acute mononucleosis.*

The diagnosis depends on the following findings:
In increasing order of specificity:

(1) lymphocytosis with the characteristic atypical lymphocytes in the peripheral blood.
(2) a positive heterophil reaction (monospot test).
(3) a rising titer of antibodies specific for EBV antigens **.**

-In most patients, mononucleosis resolves within 4 to 6 weeks .
-Occasionally, one or more complications develop:-
Perhaps the most common of these is hepatic dysfunction,
Other complications involve the nervous system, kidneys, bone marrow, lungs, eyes, heart, and spleen.

◙ **lymphopenia : it is a reducd lymphocyte count**

occur in :
-severe bone marrow failure.
- corticosteroid and other immunosuppressive therapy.
- Hodgkin's disease.
-widespread irradiation.
-immunodeficiency syndromes, the most important of which is HIV infection .

Reactive Lymphadenitis:

Any immune response against foreign antigens is often associated with lymph node enlargement **(lymphadenopathy)** .

The infections that cause lymphadenitis are numerous and varied and may be acute or chronic.
In most instances, the **histologic appearance** of the nodes is entirely **nonspecific.**

Causes of Lymphadenopathy :

Localized	Generalized
local infection • pyogenic infection, e.g. pharyngitis, dental abscess, otitis media, • viral infection • cat scratch fever • lymphogranuloma venereum • tuberculosis ***lymphoma*** • Hodgkin's lymphoma • non-Hodgkin's lymphoma ***Carcinoma (secondary)***	***Infection*** • viral, e.g. infectious mononucleosis, measles, rubella, viral hepatitis, HIV • bacterial, e.g. syphilis, brucellosis,tuberculosis, *Salmonella,* • fungal, e.g. histoplasmosis • protozoal, e.g. toxoplasmosis ***Non-infectious inflammatory diseases***, e.g. sarcoidosis, rheumatoid arthritis, SlE, other connective tissue diseases, ***Malignant*** • leukaemias, especially ell, All • lymphoma: non-Hodgkin's lymphoma, Hodgkin's lymphoma ***Miscellaneous*** • reaction to drugs and chemicals, e.g. hydantoins, beryllium • hyperthyroidism

■*Acute Nonspecific Lymphadenitis:*

This form of lymphadenitis may be confined to a **local group** of nodes draining a focal infection, or be **generalized** in systemic bacterial or viral infections.

Morphology:

Macroscopically : inflamed nodes are swollen, gray-red and engorged,

Microscopically : there are **large germinal centers** containing numerous mitotic figures.

-When the cause is a pyogenic organism, a neutrophilic infiltrate is seen.

-With severe infections, there is necrosis and abscess formation.

The overlying skin is frequently red, and sometimes penetration of the skin can produce draining sinuses.

-With control of the infection, the lymph nodes can revert to their ***normal appearance*** or, if damaged by the immune response, undergo ***scarring.***

■*Chronic Nonspecific Lymphadenitis :*

This condition can assume one of three patterns, depending on the causative agent: **follicular hyperplasia, paracortical hyperplasia, or sinus histiocytosis**.

●Morphology:

1-Follicular Hyperplasia There is **follicular (or germinal center) reaction.** The cells in the reactive follicles include the activated B cells, scattered phagocytic macrophages containing nuclear debris and follicular dendritic cells.

Causes : rheumatoid arthritis, toxoplasmosis, and the early stages of HIV infection.

2- Paracortical Hyperplasia

This pattern is characterized by reactive changes within the **T-cell regions** of the lymph node . It is encountered in **viral infections** (such as EBV), following certain **vaccinations** (e.g., smallpox), and in immune reactions induced by certain **drugs** (especially phenytoin).

3-**Sinus Histiocytosis:**

This reactive pattern is characterized by distention and prominence of the lymphatic sinusoids, owing to a marked **hypertrophy of lining endothelial cells** and an infiltrate of **macrophages** (histiocytes).

Sinus histiocytosis is often encountered in lymph nodes draining cancers (may represent an immune response to the tumor or its products).

Cat scratch disease

A **self-limited lymphadenitis** caused by the bacterium ***Bartonella henselae*.**
-It is primarily a disease of childhood; 90% of the patients are younger than 18 years of age.
-It presents as **regional lymphadenopathy**, appears approximately 2 weeks after a feline scratch or a splinter or thorn injury,most frequently in the axilla and neck.
A raised, inflammatory nodule or vesicle, is sometimes visible at the site of skin injury
In most patients the lymph node enlargement regresses over the next 2 to 4 months. Rarely, patients develop encephalitis, thrombocytopenia.., or osteomyelitis

Morphology of Cat scratch disease

S**arcoid-like granuloma s**, these then undergo central necrosis associated with the accumulation of neutrophils forming **irregular stellate necrotizing granulomas** .

The end

Lymphoreticular system

The spleen

Objectives: At the end of the lecture you must:

1-The function of the spleen .
2-Causes of splenomegaly and of massive splenomegaly.
3-Describe features of hypersplenism.
4-Define hyposplenism and list its causes.
5-Define and classify lymphoma.
6-DescribeHodgkin lymphoma.
7-Describe Reed Sternberg cells.
8 – Describe the WHO classification of Hodgkin lymphoma.

The spleen has an important and unique role in the function of the haemopoietic and immune system.

Extramedullary haemopoiesis
The spleen is an important site of haemopoiesis *in utero* and retains the ability to reactivate this process after birth.
This can occur as a compensatory erythroblastic hyperplasia in severe anaemia, such as chronic haemolysis , megaloblastic anaemia and thalassaemia major, or myelofi brosis or malignant disorders in the bone marrow.

The spleen lies under the left costal margin, has a normal weight of 150-250 g and a length of between 5 and 13 cm. It is normally not palpable but becomes palpable when the size is increased to over 14 cm.

Causes of splenomegaly
Splenomegaly is a frequent and important clinical sign.
Leukaemia and lymphomas, myeloproliferative disorders, haemolytic anaemias, glandular fever and portal hypertension account for most cases in Western countries.

The parasitic tropical infections in tropical countries: malaria leishmaniasis and schistosomiasis.

<u>Causes of massive splenomegaly:</u>
1- Chronic myeloid leukaemia
2- Malignant lymphoma

3-Primary myelofibrosis
4-Thalassaemia major or intermedia
5- leishmaniasis and schistosomiasis
6- Gaucher’ s disease

Hypersplenism:

Hypersplenism is a clinical syndrome that can be seen in any form of splenomegaly (it does not imply a specifi c causal mechanism). It is characterized
by:
o Enlargement of the spleen;
o Reduction of at least one cell line in the blood in the presence of normal bone marrow function .
o Evidence of increased release of premature cells, such as reticulocytes or immature platelets, from the
bone marrow into the blood.

Normally, only approximately 5% (30-70 mL) of the total red cell mass is present in the spleen and up to half of the total marginating neutrophil pool and 30% of the platelet mass may be located there.
As the spleen enlarges, the proportion of haemopoietic cells within the organ increases such that up to 40% of the red cell mass, and 90% of platelets , may be pooled in an enlarged spleen.

Hyposplenism

Hyposplenism (excluding that induced by medical or surgical intervention) occurs in a wide range of conditions, such as sickle cell disease, gluten - induced enteropathy (coeliac syndrome) and dermatitis herpetiformis, Crohn ’ s disease, ulcerative colitis and essential thrombocythaemia.
Congenital absence of the spleen is rare and may be associated with organ transposition and with severe malformations of the heart and lungs.
In old age, there is a rapid decrease in the weight of the spleen, together with increasing atherosclerotic vascular obstruction and fibrosis.
Patients with functional hyposplenism have impaired immunity to blood - borne bacterial and protozoal infections, and persistent thrombocytosis.

Lymphomas

<u>Lymphomas</u> are a group of diseases caused by malignant lymphocytes *(T,B,or NK)* that accumulate in lymph nodes and cause the characteristic clinical features of lymphadenopathy .

- Although having different characteristics from their normal counterparts, the neoplastic cells of many lymphomas have the features of lymphoid cells at a particular stage of differentiation

<u>Lymphomas arise as a result of a series of mutations in a single lymphoid cell.</u>

The major subdivision of lymphomas is into **Hodgkin's lymphoma** and **non-Hodgkin's lymphoma** and this is based on the histological presence of ***<u>Reed-Sternberg (RS) cells in Hodgkin's lymphom</u>***

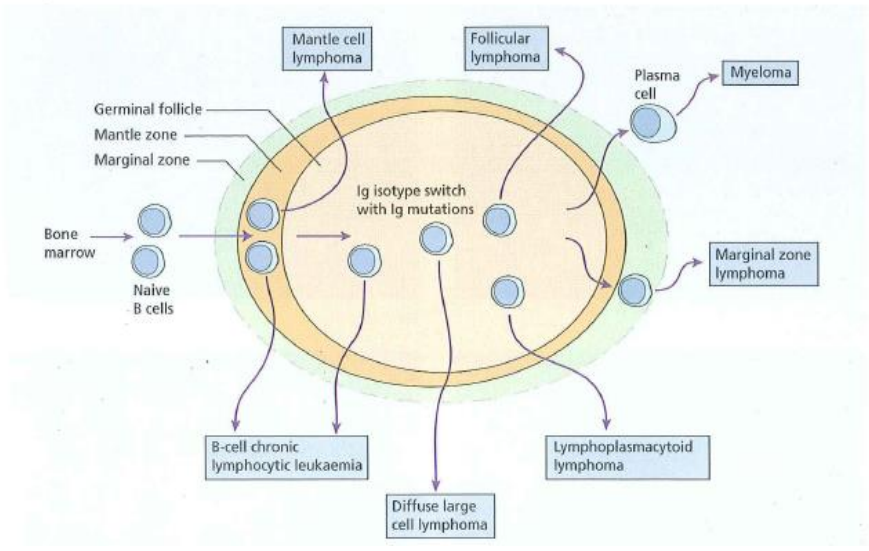

<u>Hodgkin's Lymphoma:</u>

Hodgkin lymphoma include distinctive group of neoplasms that arise almost invariably in a single lymph node or chain of lymph nodes and spread characteristically in a stepwise fashion to the anatomically contiguous nodes.

***<u>Morphology</u>*:**

■ **It is *characterized morphologically by the presence of distinctive neoplastic giant cells called Reed-Sternberg (RS) cells,* which are mixed with reactive, nonmalignant inflammatory cells.**

, ■**Molecular studies have shown that it is a tumor *o f B-cell origin***

,
The disease can present at any age but is rare in children and has a peak incidence in young adults.

There is an almost 2 : 1 male predominance

The usual clinical presentation is with painless asymmetrical lymphadenopathy –most commonly in the neck. Typically the disease is localized initially to a single peripheral lymph node region and its subsequent progression is by contiguity within the lymphatic system.

Constitutional symptoms of fever ,weight loss & sweating are prominent in patients with **widespread disease**.

Alcohol-induced pain in the areas where disease is present occurs in some patients.

Diagnosis and histological classification:
The diagnosis is made by histological examination of an ***excised lymph node.***

-*The histologic diagnosis of Hodgkin lymphoma rests on the definitive identification of **Reed-Sterberg cells or their variants** in the appropriate background of reactive cells.*

Morphology of Reed –Sternberg cells :
The Reed-Sternberg (RS) cell is a large cell with an enlarged multilobated nucleus, prominent nucleoli, and abundant, usually slightly eosinophilic, cytoplasm. Particularly characteristic are cells with two mirror-image nuclei or nuclear lobes, each containing a large (inclusion-like) acidophilic nucleolus surrounded by a distinctive clear zone; together they give an owl-eye appearance. The nuclear membrane is distinct.

■Blood tests may show anaemia , neutrophilia , eosinophilia & raised erythrocyte sedimentation rate (ESR) or lactate dehydrogenase(LDH).

WHO classification of Hodgkin's lymphoma.

-***Nodular lymphocyte - predominant Hodgkin lymphoma***

-***Classical Hodgkin lymphoma***

1. Nodular sclerosis classical Hodgkin lymphoma
2. Mixed- cellularity classical Hodgkin lymphoma
3. Lymphocyte- rich classical Hodgkin lymphoma
4. Lymphocyte- depleted classical Hodgkin lymphoma .

The "classic" RS cells are **common** in the **mixed-cellularity** subtype, uncommon in the nodular sclerosis subtype, and **rare** in the **lymphocyte-predominance** subtype .

◙Nodular sclerosis classical Hodgkin lymphoma

-The most common form**.**

- It is equally frequent in men and women**.**

- Most of the patients are adolescents or young adults**.**

- The overall prognosis is excellent**.**

Morphology :

A variant of the RS cell, the lacunar cell . This cell is large and has a single multilobate nucleus with multiple small nucleoli and an abundant, pale-staining cytoplasm.

-In formalin-fixed tissue, the cytoplasm often retracts, giving rise to the appearance of cells lying in empty spaces, or lacunae .

There are varying proportions of lymphocytes, eosinophils, histiocytes .

- Classic RS cells are infrequent.

-There are collagen bands that divide the lymphoid tissue into circumscribed nodules.

◙ Mixed- cellularity classical Hodgkin lymphoma:

- Patients older than the age of 50 year.

-Male predominance.

- Classic RS cells are plentiful within cellular infiltrate of small lymphocytes, eosinophils, plasma cells, and benign histiocytes.

- More patients with mixed cellularity have disseminated disease and systemic manifestations

◙Lymphocyte-Predominance Hodgkin Lymphoma: -

This subgroup, comprising about 5% of Hodgkin lymphoma.

-It is characterized by a large number of small resting lymphocytes admixed with a variable number of benign histiocytes.

Eosinophils, neutrophils, and plasma cells, are scanty or absent, and classic RS cells are extremely difficult to find.

- Lymphohistiocytic (L&H) variant RS cells that have a delicate multilobed, puffy nucleus that has been likened in appearance to popcorn ("popcorn cell").

■ In all forms, involvement of the spleen, liver, bone marrow, and other organs may appear in the course of the disease.

Lymphoreticular system

Objectives:
1-Define Non-Hodgkin's lymphomas
2-Describe cell of origin of Non-Hodgkin's lymphomas .
3- Clinical features of non-Hodgkin's lymphomas:
4- List the Clinical Differences Between Hodgkin and Non-Hodgkin Lymphomas
5-Know how to diagnose lymphoma.
6- Describe Specific subtypes of non-Hodgkin's lymphoma:
7- Describe the Clinical Staging of Hodgkin and Non-Hodgkin Lymphomas (Ann Arbor Classification)

Non-Hodgkin's lymphomas

These are a large group of clonal lymphoid tumours, about 85 % are of B cell origin and 15% of T or NK(natural killer) cell origin.
They are characterized by an irregular pattern of spread and a significant proportion of patients develop extranodal disease.

The non-Hodgkin's lymphomas are a diverse group of diseases and vary from highly proliferative and rapidly fatal diseases to some of the most indolent and well-tolerated malignancies.

Cell of origin:

- **B-cell lymphomas tend to mimic normal B cells at different stages of development .**
- **T-cell lymphomas resemble precursor T cells in bone marrow or thymus ,or peripheral mature T cells.**

ClassificationThe lymphomas are classified within a group of mature B-cell and T-cell neoplasm

WHO classification of mature lymphoid neoplasms

Mature B-cell neoplasms
Chronic lymphocytic leukaemia/small lymphocytic lymphoma
B-cell prolymphocytic leukaemia
Splenic B-cell marginal zone lymphoma
Hairy cell leukaemia
Splenic lymphoma/leukaemia unclassifiable
  Splenic diffuse red pulp small B-cell lymphoma
  Hairy cell leukaemia variant
Lymphoplasmacytic lymphoma/Waldenström macroglobulinaemia
Heavy chain diseases
Plasma cell myeloma
Solitary plasmacytoma of bone
Extraosseous plasmacytoma
Extranodal marginal zone lymphoma of mucosa-associated lymphoid tissue (MALT lymphoma)
Nodal marginal zone lymphoma
  Paediatric nodal marginal zone lymphoma
Follicular lymphoma
  Paediatric follicular lymphoma
Primary cutaneous follicle centre lymphoma
Mantle cell lymphoma
Diffuse large B-cell lymphoma (DLBCL), not otherwise specified
  T-cell/histiocyte-rich large B-cell lymphoma
  Primary DLBCL of the CNS
  Primary cutaneous DLBCL, leg type
  EBV-positive DLBCL of the elderly
DLBCL associated with chronic inflammation
Lymphomatoid granulomatosis
Primary mediastinal (thymic) large B-cell lymphoma
Intravascular large B-cell lymphoma
ALK-positive large B-cell lymphoma
Plasmablastic lymphoma
Large B-cell lymphomas arising in HHV8-associated multicentric Castleman disease
Primary effusion lymphoma
Burkitt lymphoma
B-cell lymphoma, unclassifiable, with features intermediate between DLBCL and Burkitt lymphoma
B-cell lymphoma, unclassifiable, with features intermediate between DLBCL and classical Hodgkin lymphoma

Mature T-cell and NK-cell neoplasms
T-cell prolymphocytic leukaemia
T-cell large granular lymphocytic leukaemia
Chronic lymphoproliferative disorder of NK cells
Aggressive NK-cell leukaemia
Systemic EBV-positive T-cell lymphoproliferative disease of childhood
Hydroa vacciniforme-like lymphoma
Adult T-cell leukaemia/lymphoma
Extranodal NK/T-cell lymphoma, nasal type
Enteropathy-asociated T-cell lymphoma
Hepatosplenic T-cell lymphoma
Subcutaneous panniculitis-like T-cell lymphoma
Mycosis fungoides
Sézary syndrome
Primary cutaneous CD30-positive T-cell lymphoproliferative disorders
  Lymphomatoid papulosis
  Primary cutaneous anaplastic large-cell lymphoma
Primary cutaneous γδ T-cell lymphoma
Primary cutaneous CD8-positive aggressive epidermotropic cytotoxic T-cell lymphoma
Primary cutaneous CD4-positive small/medium T-cell lymphoma
Peripheral T-cell lymphoma, unspecified
Angioimmunoblastic T-cell lymphoma
Anaplastic large-cell lymphoma, ALK positive
Anaplastic large-cell lymphoma, ALK negative

Hodgkin lymphoma
Nodular lymphocyte predominant Hodgkin lymphoma
Classical Hodgkin lymphoma
  Nodular sclerosis classical Hodgkin lymphoma
  Lymphocyte-rich classical Hodgkin lymphoma
  Mixed cellularity classical Hodgkin lymphoma
  Lymphocyte-depleted classical Hodgkin lymphoma

Non-Hodgkin's lymphoma

For many years clinicians have subdivided lymphomas into low and high-grade disease.

-In general terms, the **low grade disorders** are relatively indolent, respond well to chemotherapy but are very difficult to cure whereas **high-grade lymphomas** are aggressive and need urgent treatment but are often curable.

--Low grade lymphoma: e.g.
Follicularr lymphoma , mantle cell lymphoma .

---_**High Grade Lymphoma** : e. g.
Diffuse Large B-Cell Lymphoma ,Burkitt's lymphoma

Clinical features of non-Hodgkin's lymphomas:

*1.**Superficial lymphadenopathy***: asymmetric painless enlargement of lymph nodes in one or more peripheral lymph node regions.
2. ***Constitutional symptoms*** Fever, night sweats and weight loss occur less frequently than in Hodgkin's disease.
3. ***Oropharyngeal*** *involvement*.
4. ***Features due*** *to* Anaemia, neutropenia or thrombocytopenia.
5.***organs*** **involvement** ,the liver and spleen are often enlarged.
The gastrointestinal tract is the most commonly involved extranodal site after the bone marrow.
Also Skin, brain, testis or thyroid can be involved

Clinical Differences Between Hodgkin and Non-Hodgkin Lymphomas:	
Hodgkin Lymphoma	**Non-Hodgkin Lymphoma**
1. More often localized to a single axial group of nodes (cervical, mediastinal, para-aortic	1.More frequent involvement of multiple peripheral nodes
2. Orderly spread by contiguity	2.Noncontiguous spread
3. Mesenteric nodes and Waldeyer ring rarely involved	3.Mesenteric nodes and Waldeyer ring commonly involved
4.Extranodal involvement uncommon	4.Extranodal involvement common

Investigations

--Histology

..Lymph node biopsy is the definitive investigation.
..Immunophenotypic and genetic analysis.
..A fine needle aspiration may be performed to exclude another

---**Laboratory investigations:**

1. In advanced disease with marrow involvement ,there may be anaemia,neutropenia or thrombocytopenia.
2. Lymphoma cells may be found in the peripheral blood in some patients.
3. Trephine biopsy of marrow to see if there is bone marrow involvement .
4.increase LDH and uric acid.
5. Immunoglobulin electrophoresis may reveal a paraprotein

Specific subtypes of non-Hodgkin's lymphoma:

Follicular lymphoma:

- 25% of adult lymphomas .

-Follicular lymphoma occurs predominantly in older persons (rarely before age 20 years) and affects males and females equally.
-It usually presents as *painless lymphadenopathy,* which is frequently generalized.
-It is associated with the t(14,18) translocation in the great majority of cases.
Involvement of visceral sites is uncommon.
-Bone marrow involvement is frequent.
-The tumor cells resemble normal follicular center B cells.-
-The natural history is prolonged (median survival, 7-9 years), but *follicular lymphoma is not easily curable,* a feature that is common to most of the **indolent lymphoid malignancies**

♦ Mantle cell lymphoma:

It usually presents with advanced disease involving lymph nodes, bone marrow, and extranodal sites such as the gut.
Highly associated with a t(11,14) translocation that results in over-expression of cyclin D1.

Diffuse Large B-Cell Lymphoma :

Heterogeneous group of mature B cell tumors that share a similar large-cell morphology and aggressive clinical behavior.
Highly associated with rearrangements or mutations of *BCL6* gene.

***♦Burkitt's lymphoma*:**

-It is one of the most highly proliferative subtypes of any tumours.
-It occurs in endemic or sporadic forms.
-It is associated with t (8,14).
---Endemic (African) Burkitt's lymphoma is seen in areas with

Typically, the patient, usually a child, presents with massive lymphadenopathy of the jaw which is initially very responsive to chemotherapy although long-term cure is uncommon
-Sporadic cases may occur elsewhere in the world.

◙**T-cell lymphoma** are less common include:
mycosis fungoides , peripheral T-cell lymphoma and anaplastic large cell lymphoma , enteropathy –associated T-cell lymphomas, and others.

Clinical Staging of Hodgkin and Non-Hodgkin Lymphomas (Ann Arbor Classification)*

Stage I	Involvement of a single lymph node region (I) or involvement of a single extralymphatic organ or tissue (I_E)
Stage II	Involvement of two or more lymph node regions on the same side of the diaphragm alone (II) or with involvement of limited contiguous extralymphatic organs or tissue (II_E)
Stage III	Involvement of lymph node regions on both sides of the diaphragm (III), which may include the spleen (III_S), limited contiguous extralymphatic organ or site (III_E), or both (III_{ES})
Stage IV	Multiple or disseminated foci of involvement of one or more extralymphatic organs or tissues with or without lymphatic involvement

--All stages are further divided on the basis of the absence (A) or presence (B) of the following systemic symptoms: significant fever, night sweats, unexplained loss of more than 10% of normal body weight.