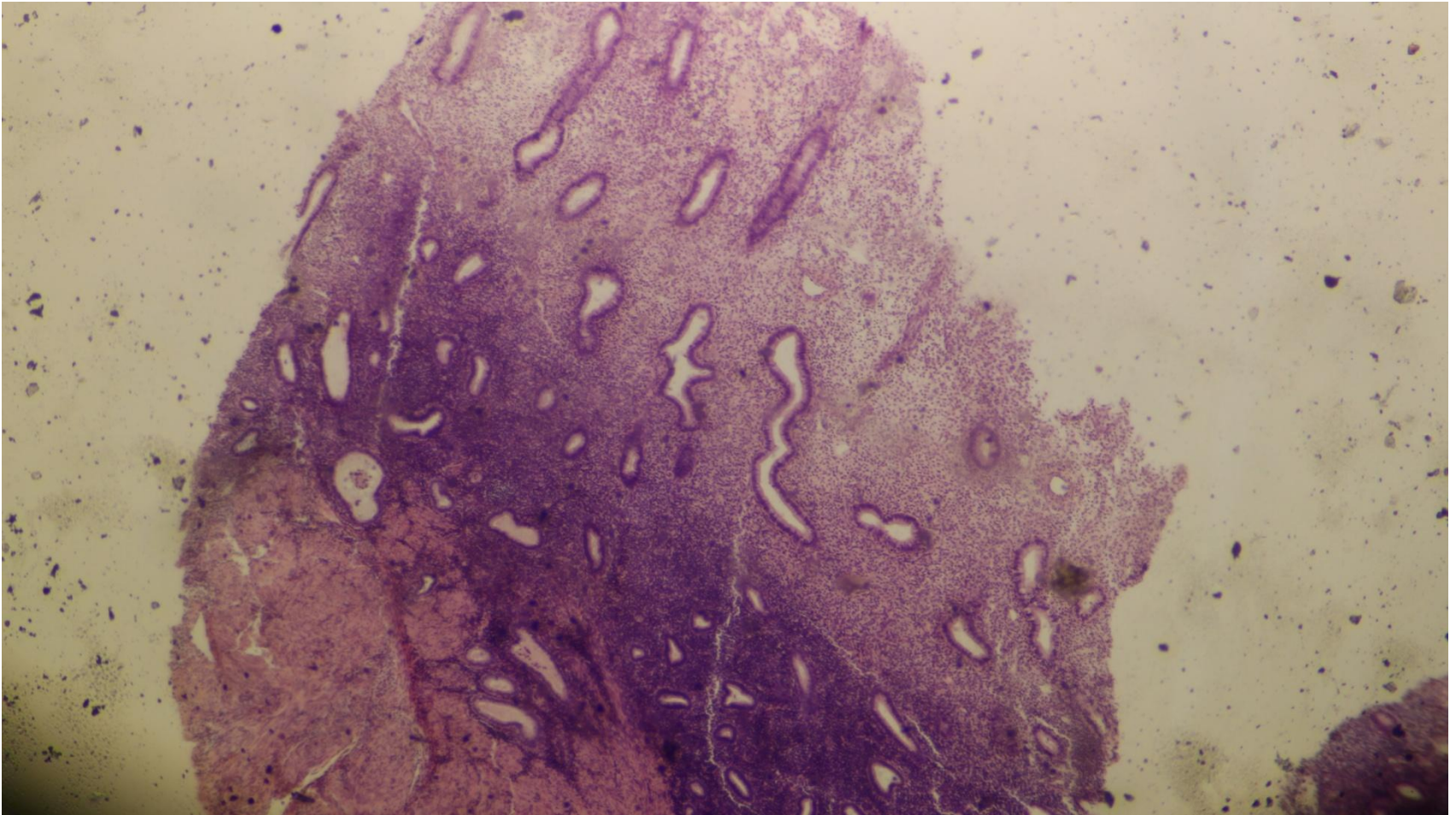
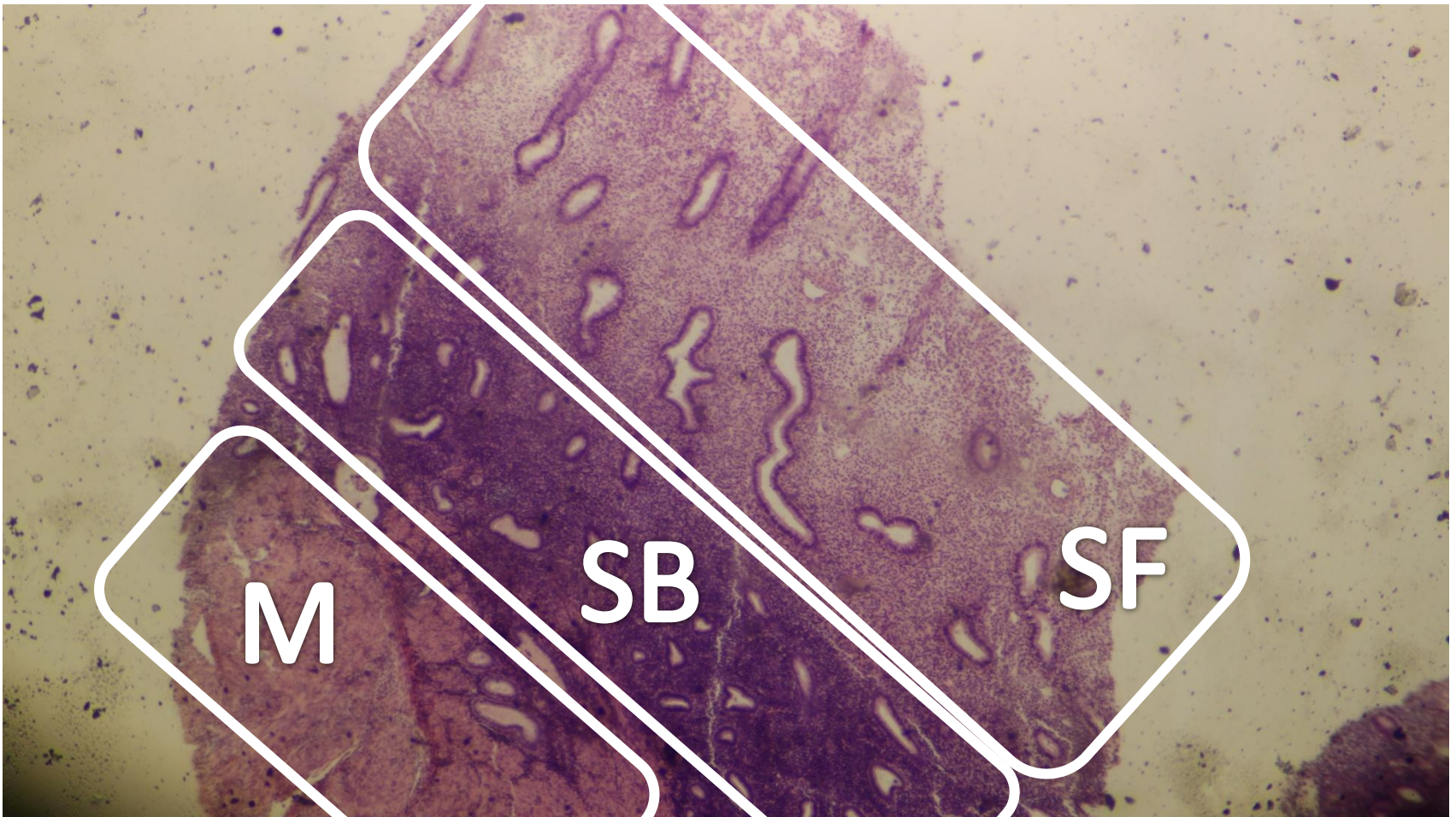


# Female reproductive system part 2

# Proliferative phase of endometrium

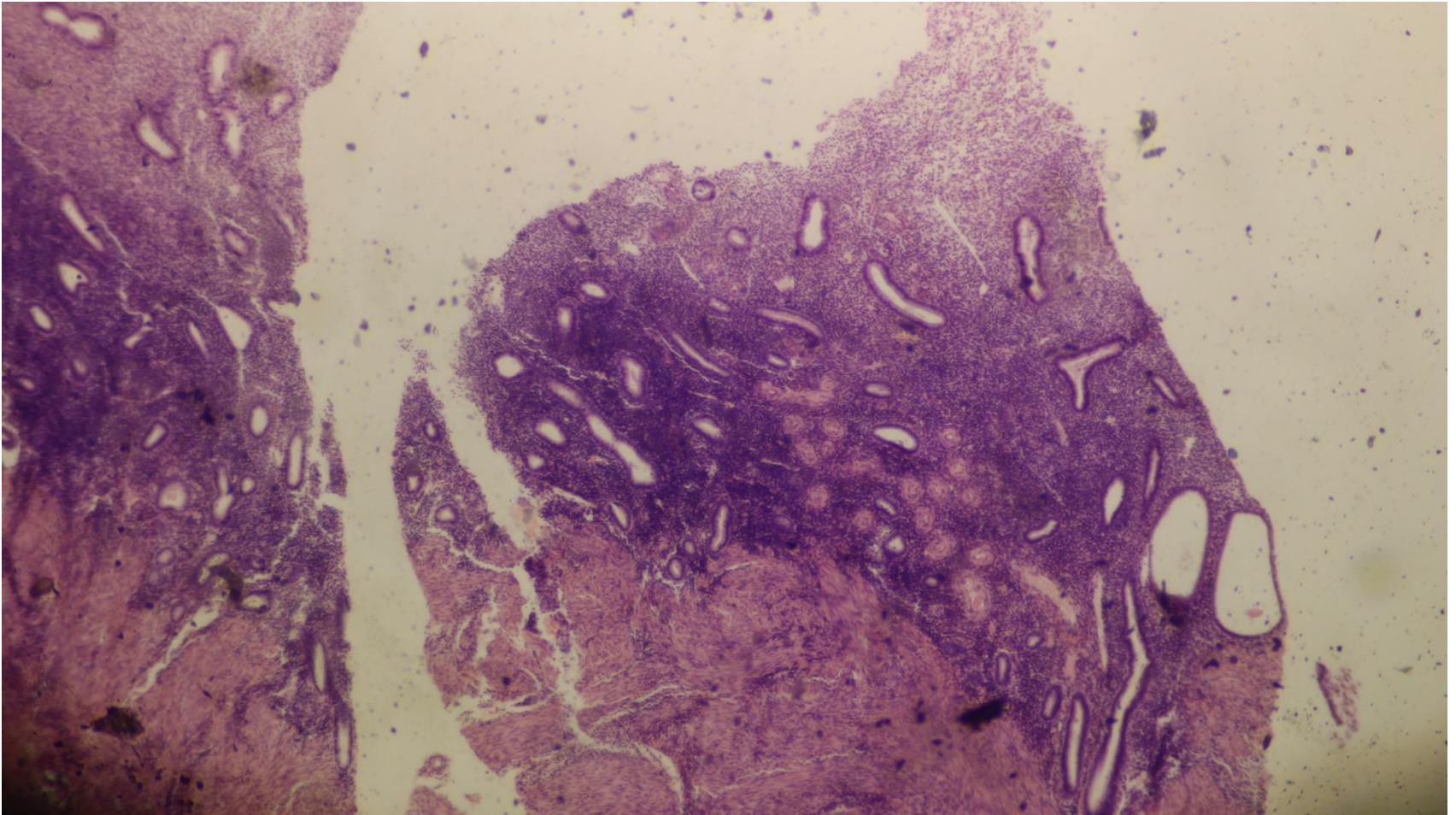


Proliferative phase of endometrium, stratum basale (SB), stratum functionalis (SF) & myometrium (M)



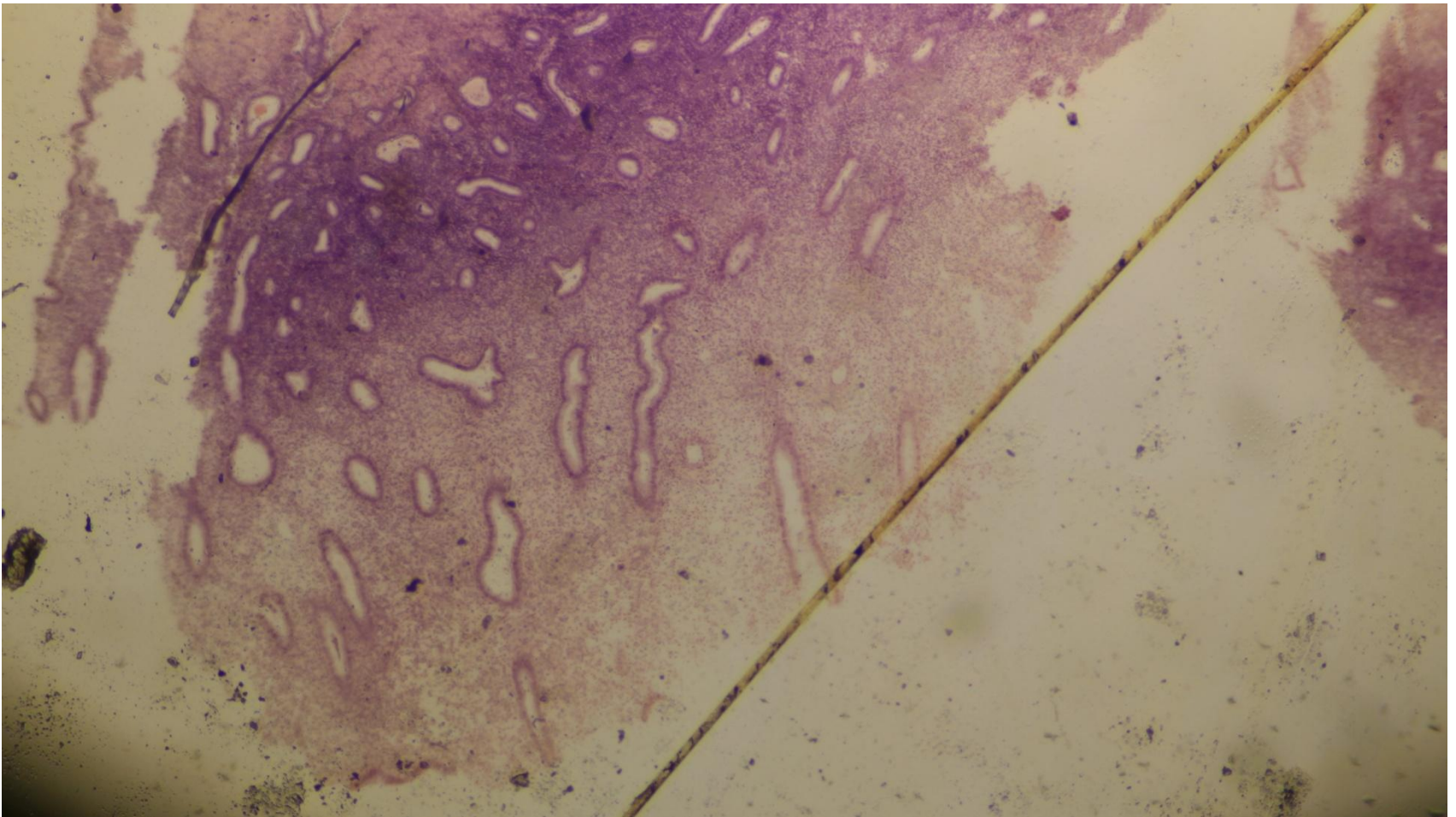


# Proliferative phase of endometrium

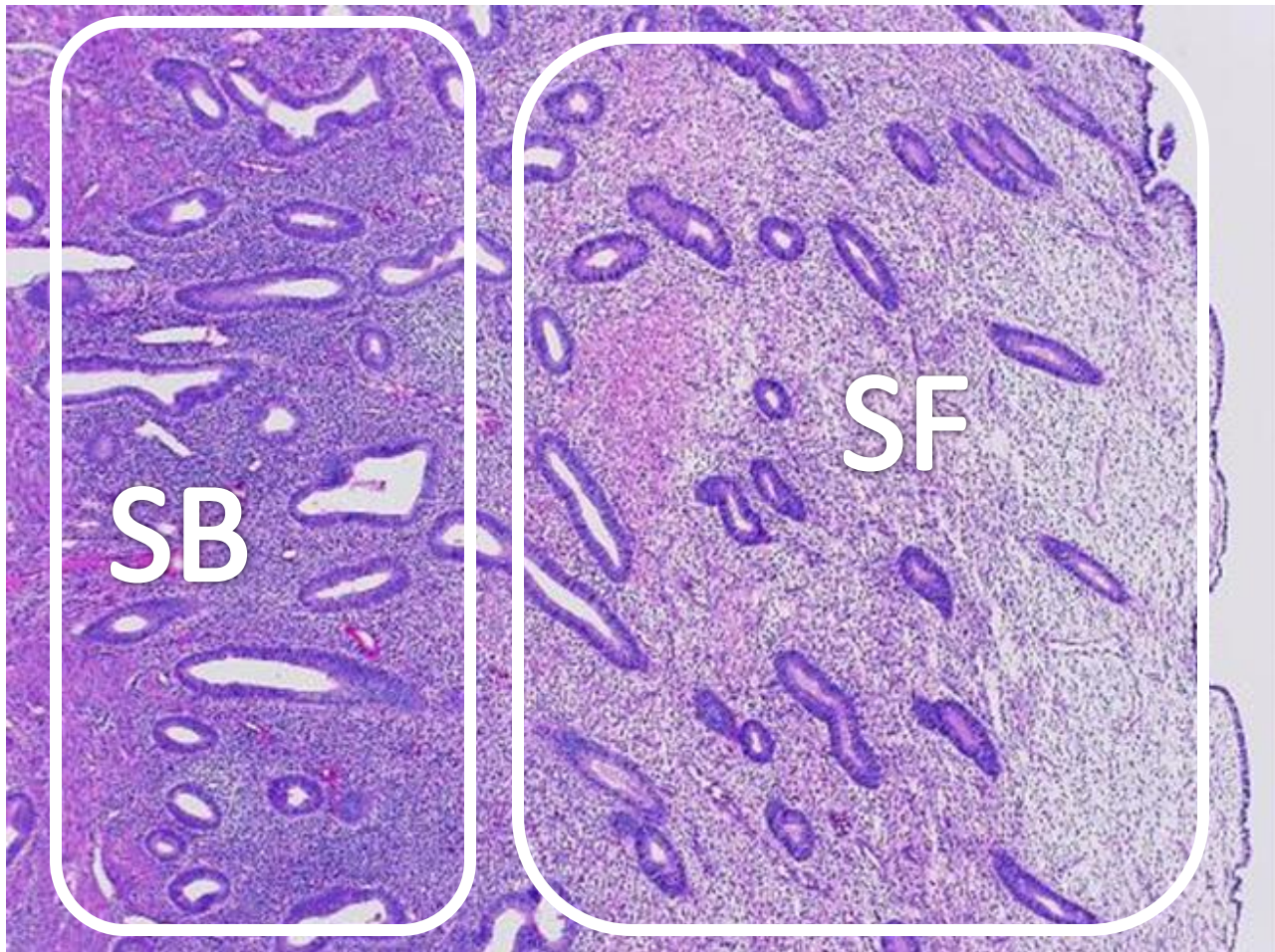




# Proliferative phase of endometrium

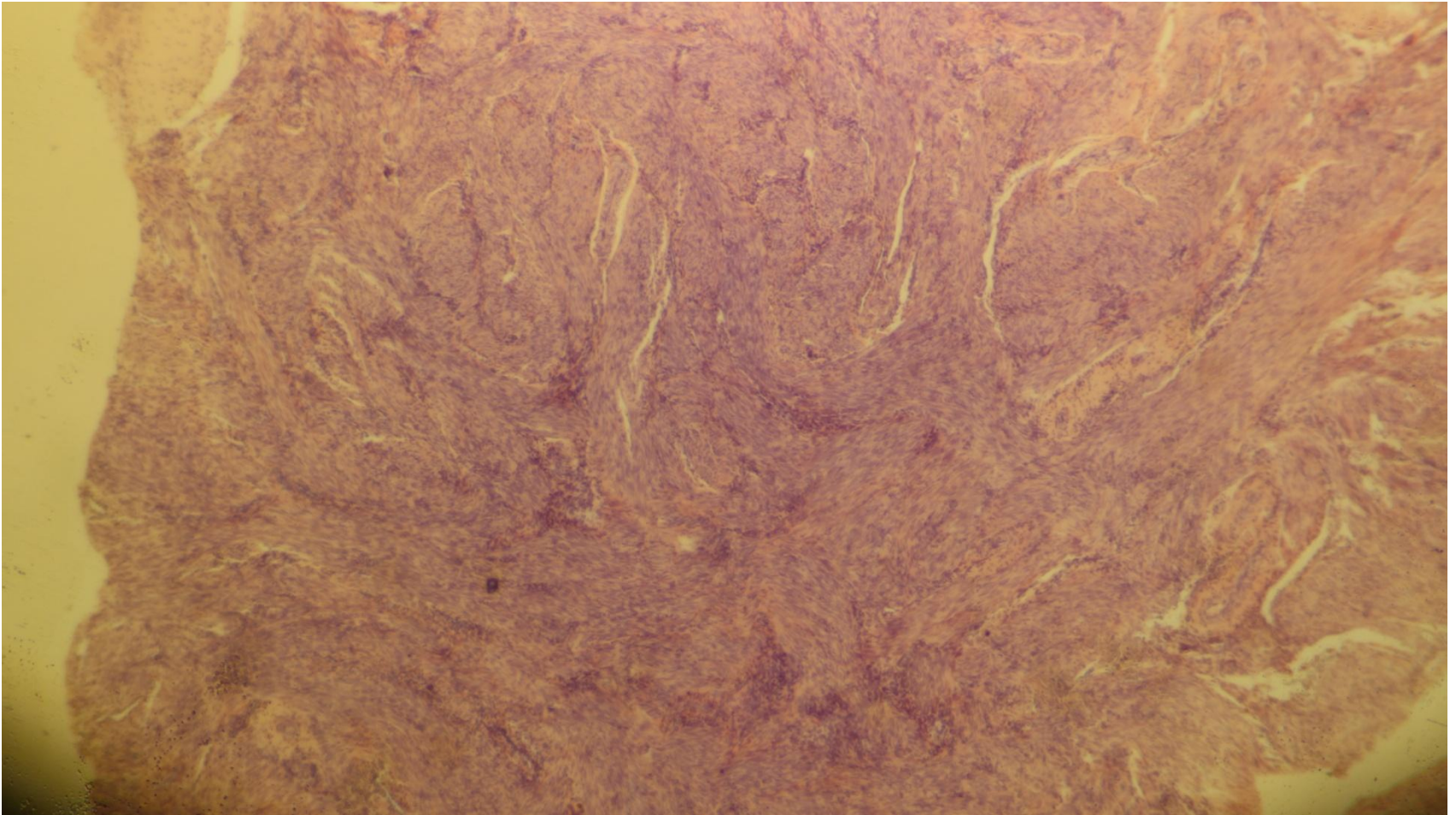


# Proliferative phase of endometrium- stratum basale (SB) & Stratum functionalis (SF)

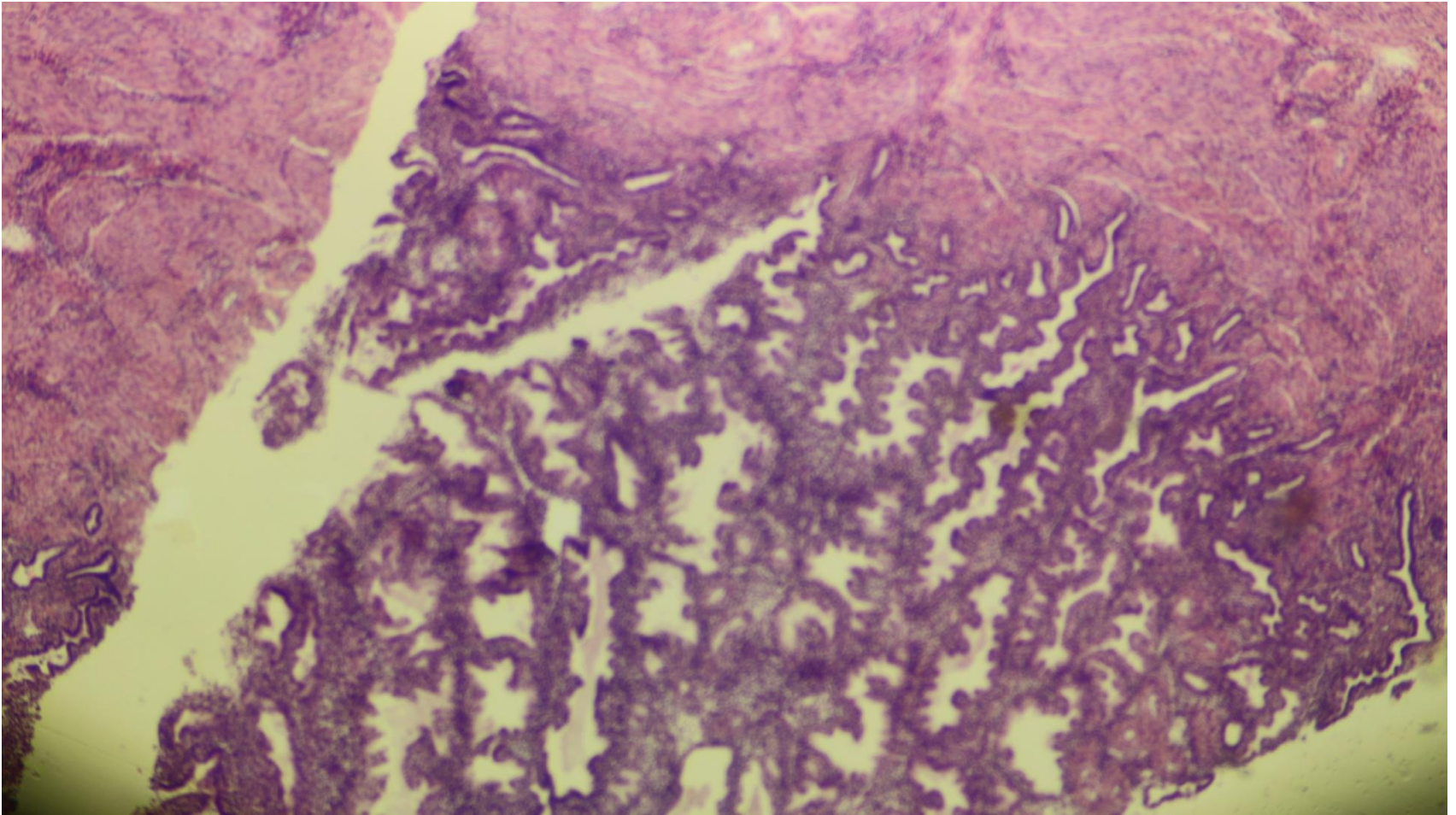




# Myometrium

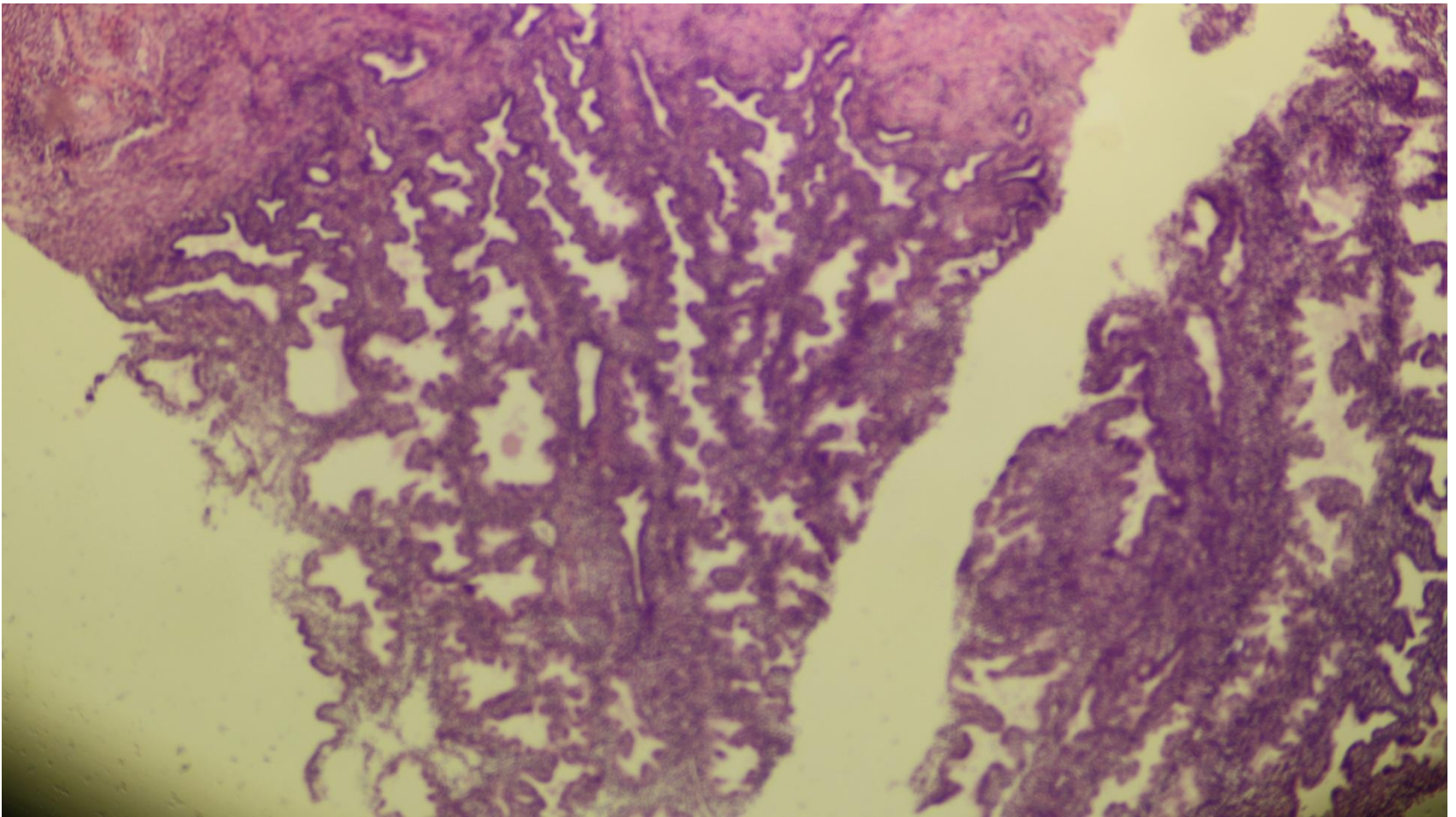


# Secretory phase of endometrium



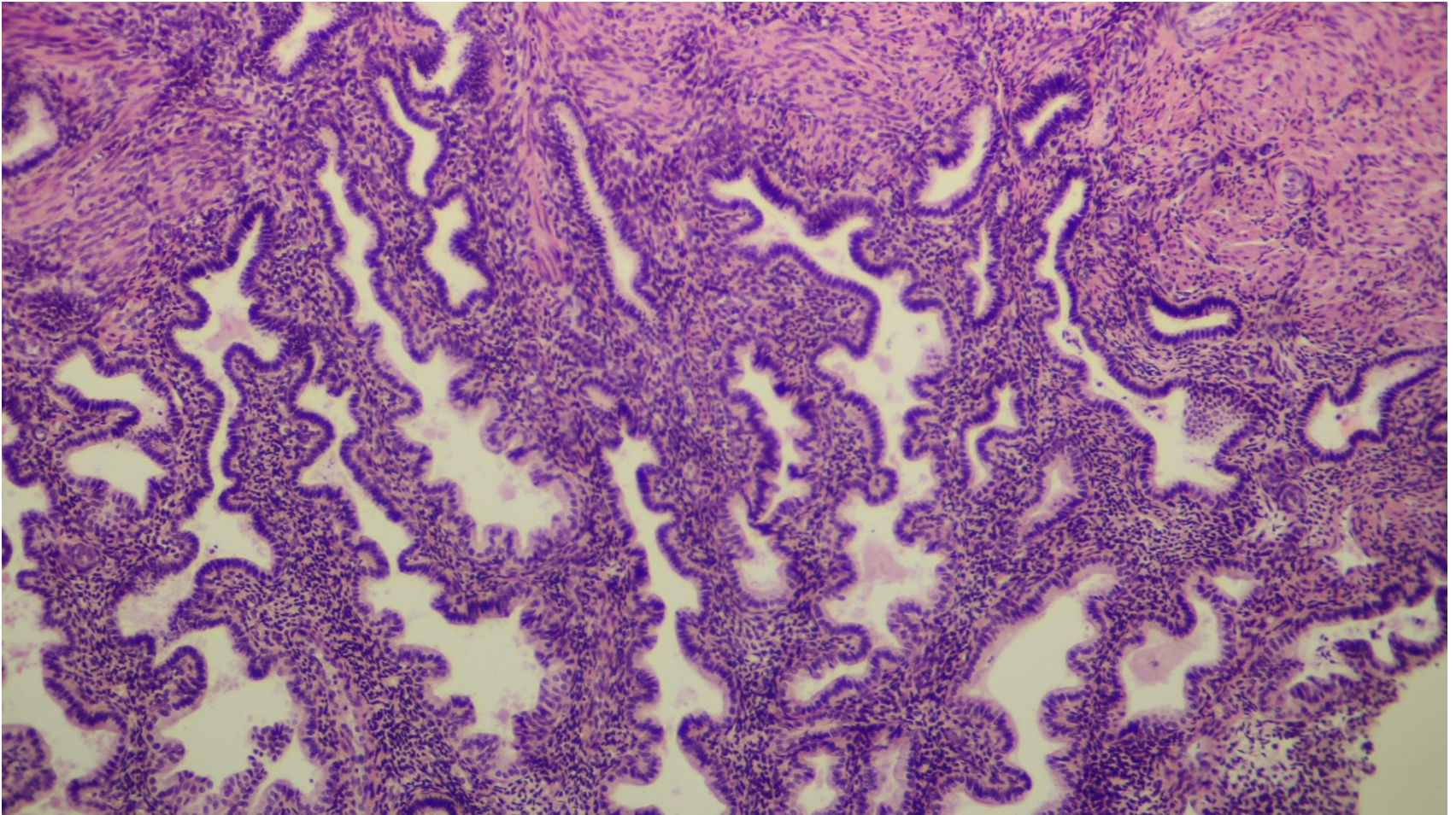


# Secretory phase of endometrium



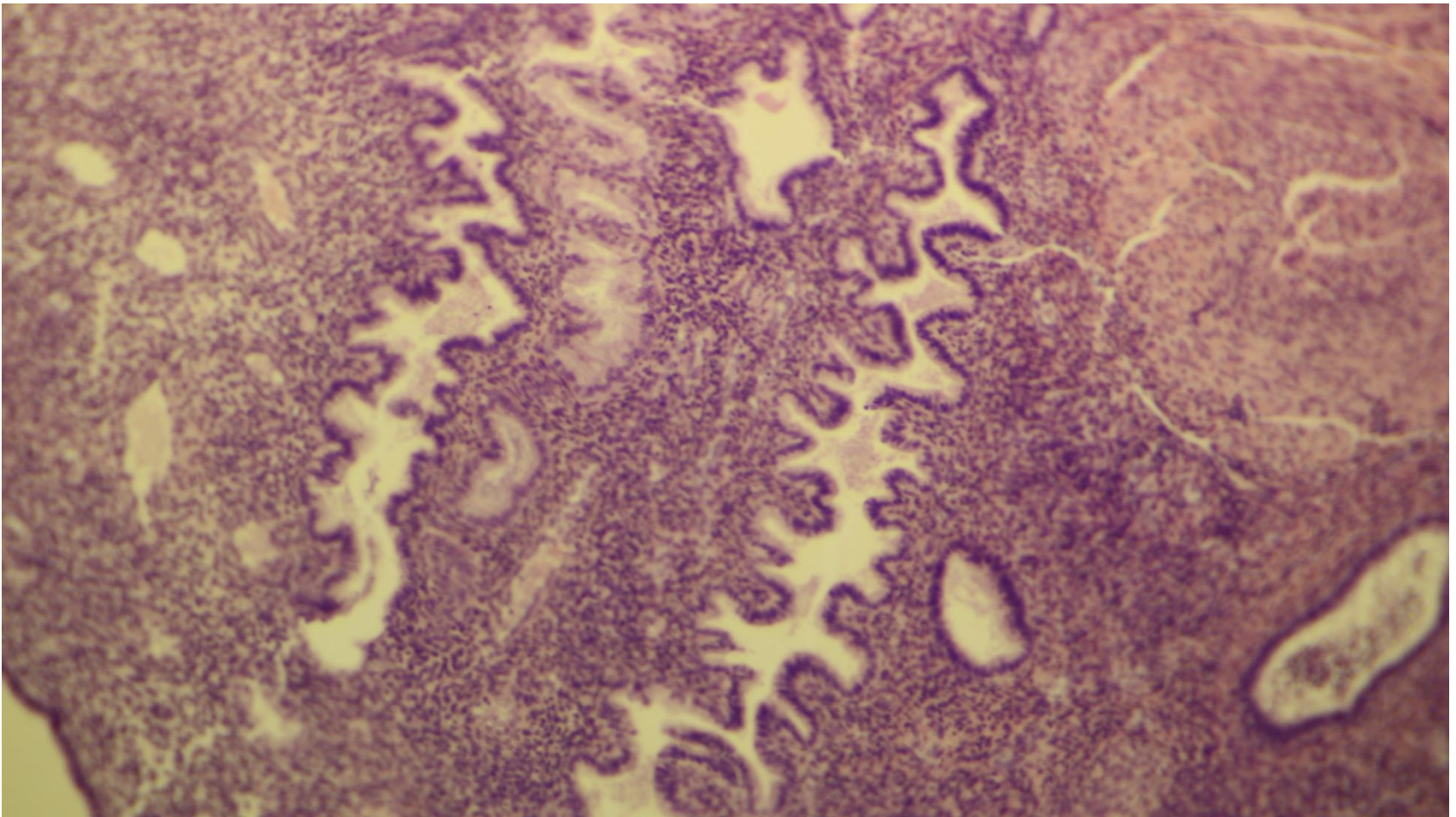


# Secretory phase of endometrium

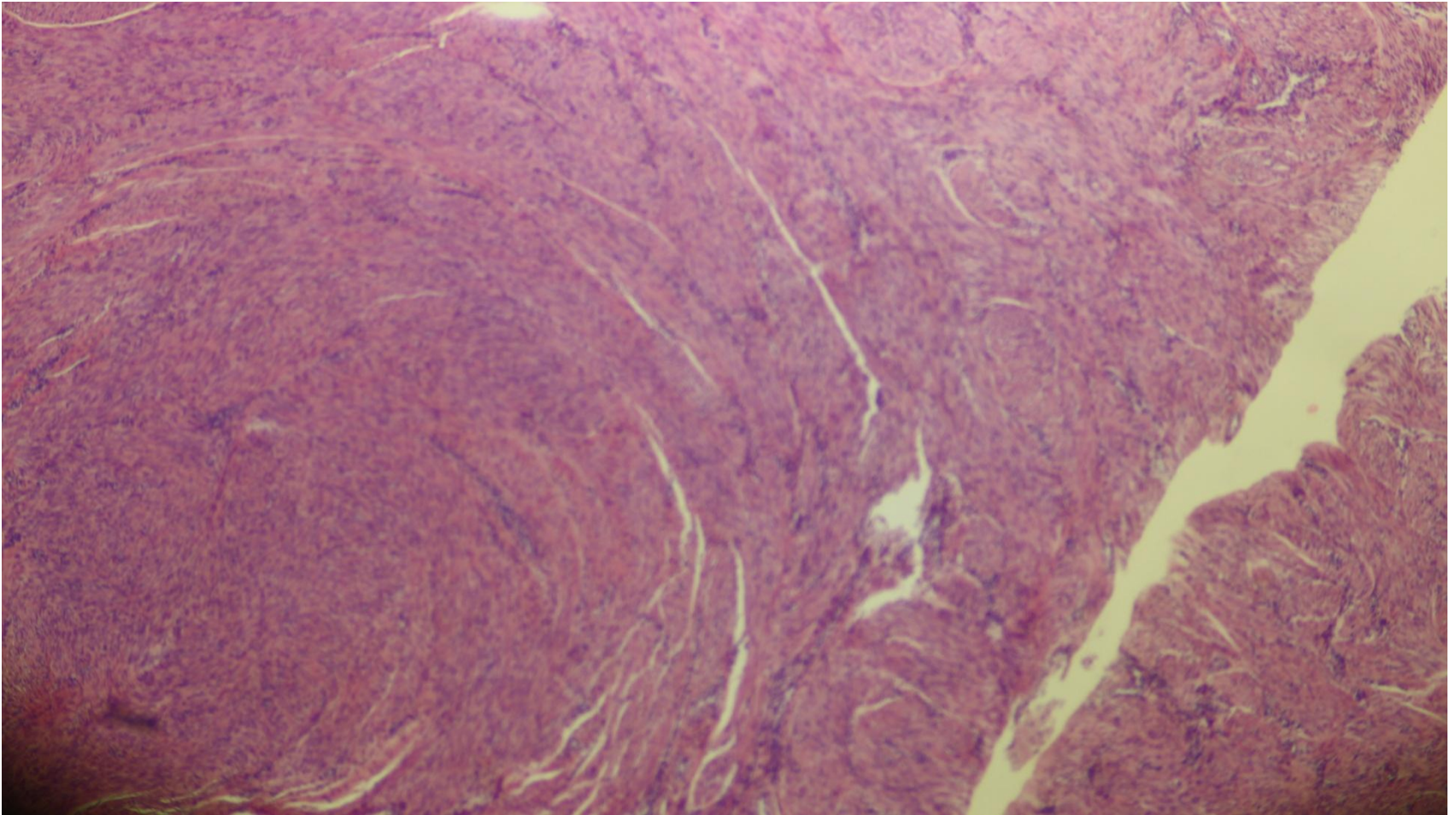




Secretory phase of endometrium- saw  
tooth appearance of uterine glands

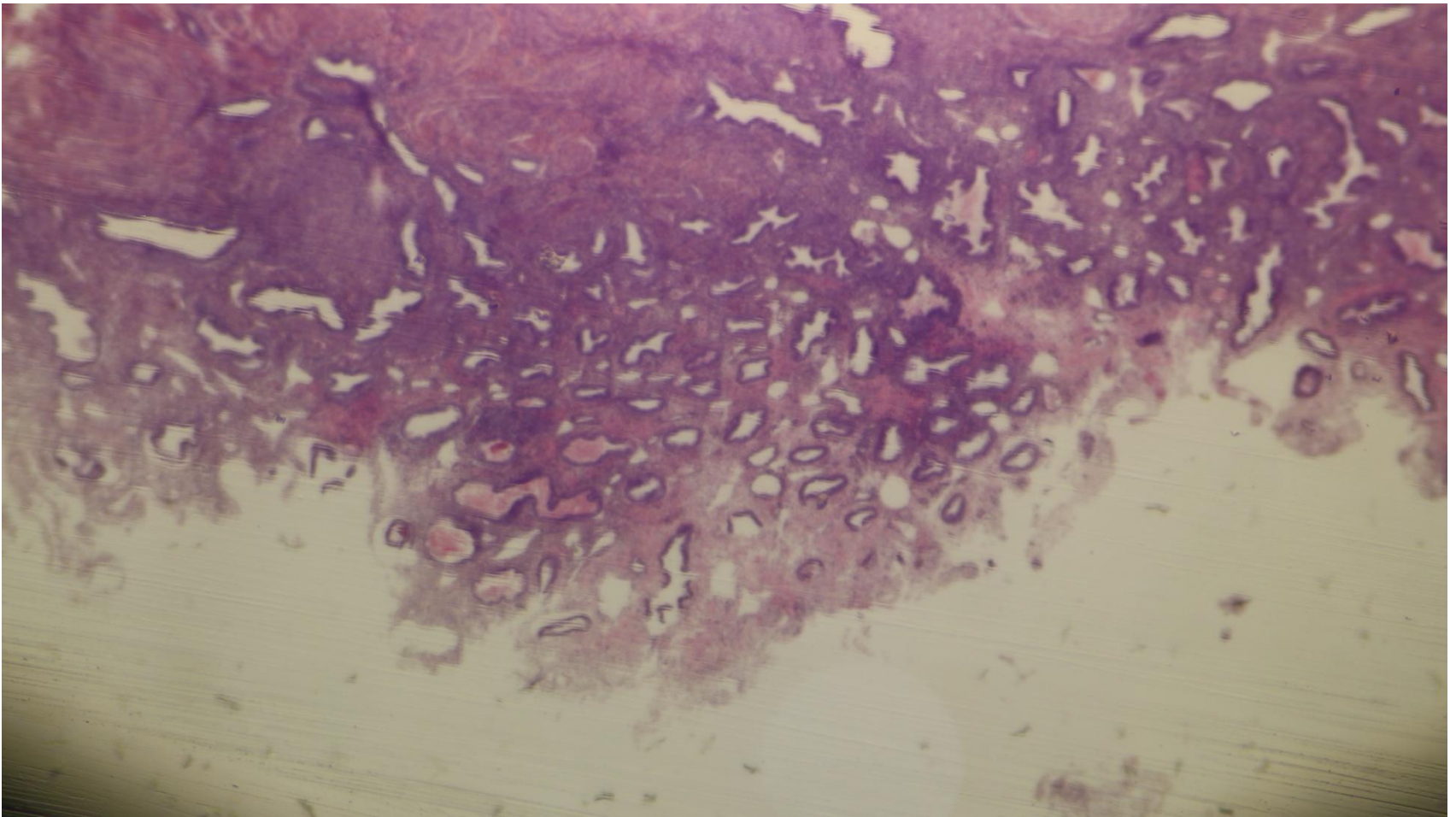


# Myometrium

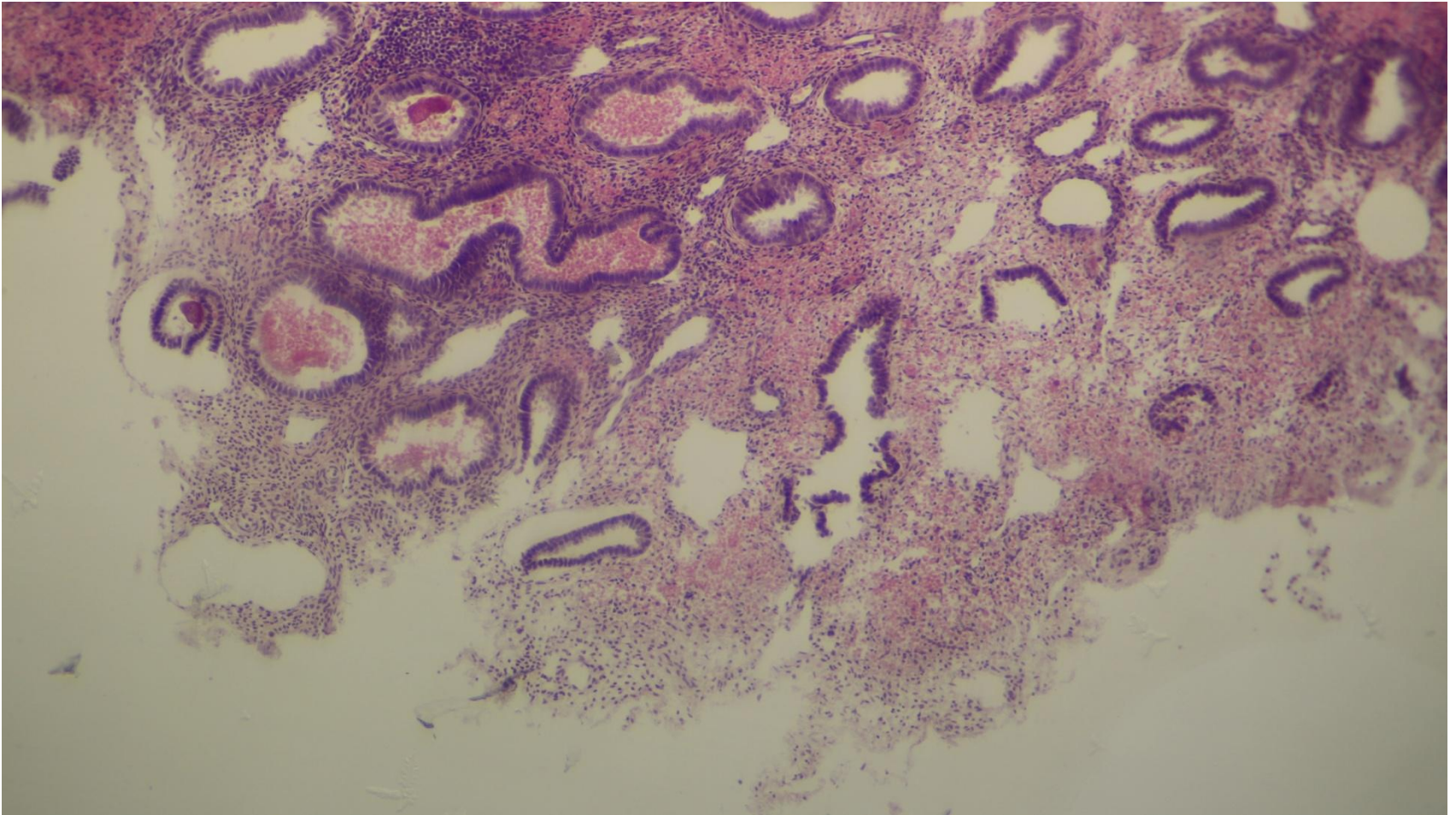




# Menstrual phase

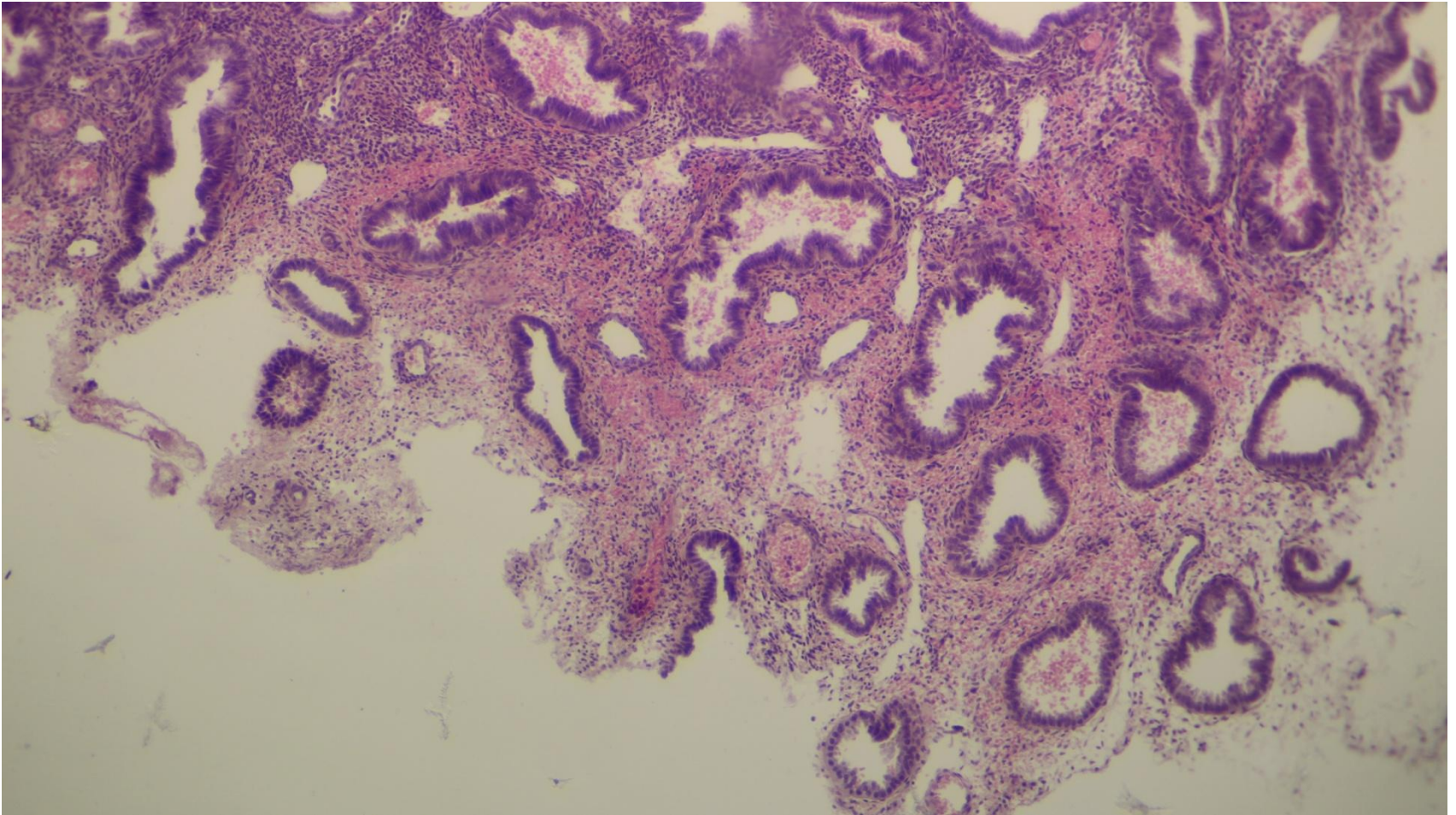


# Menstrual phase

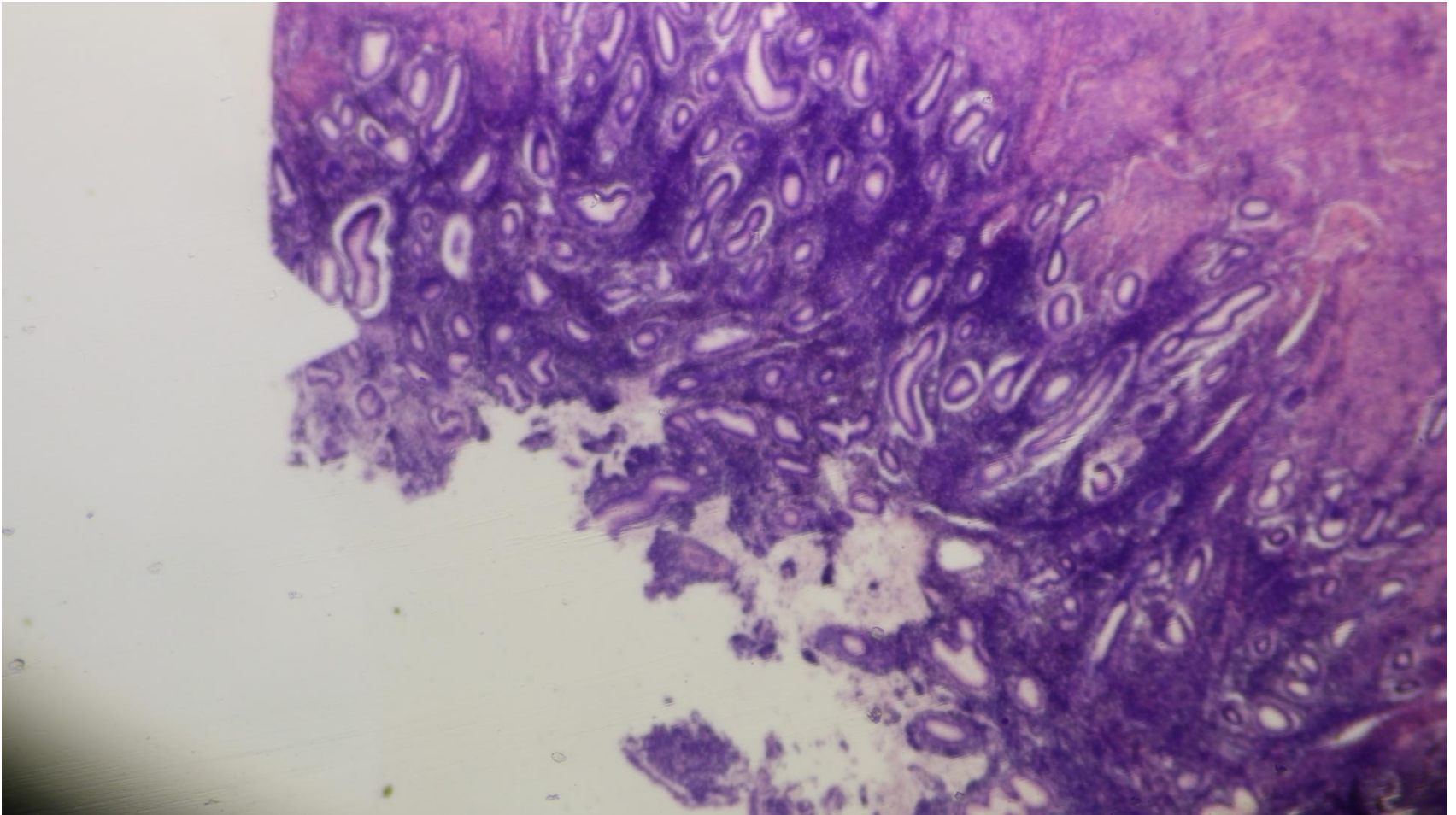




# Menstrual phase

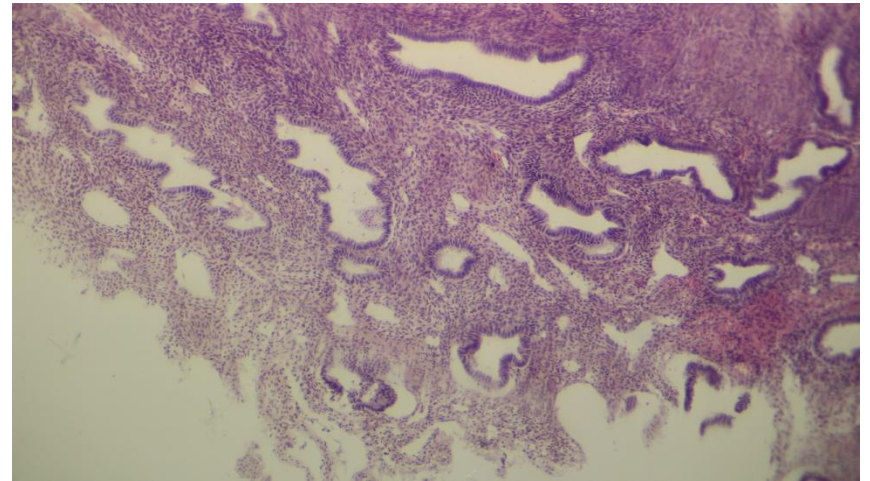
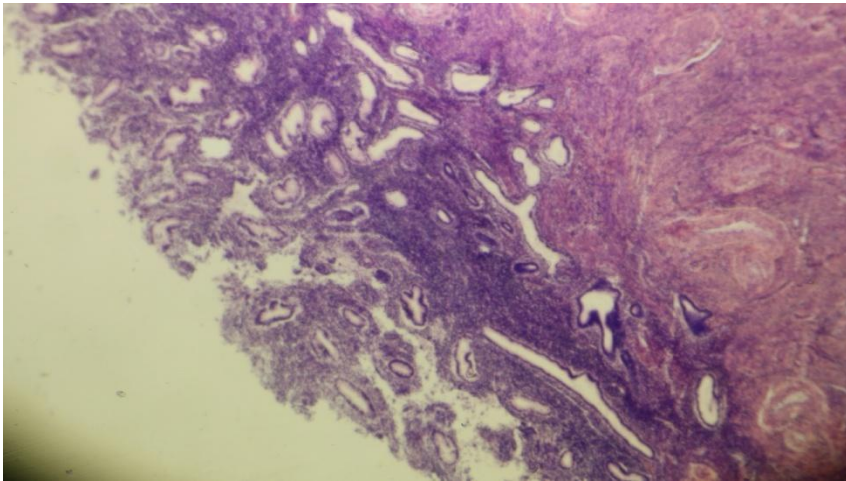


# Menstrual phase

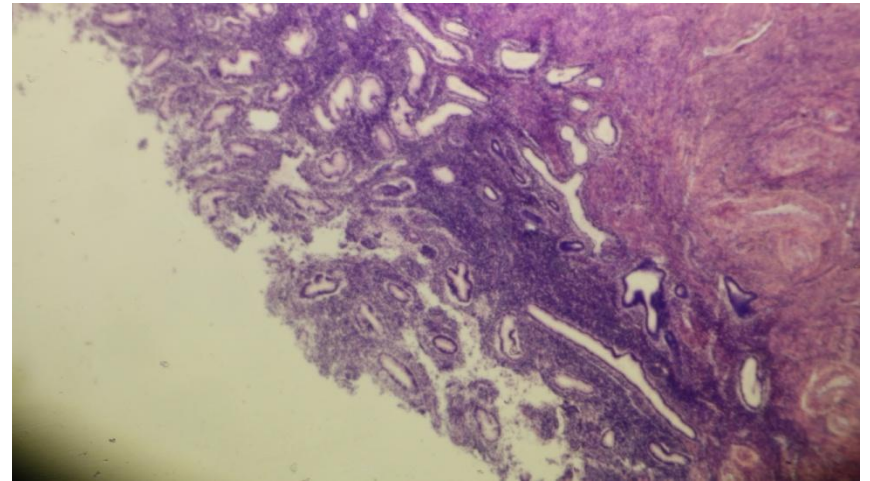
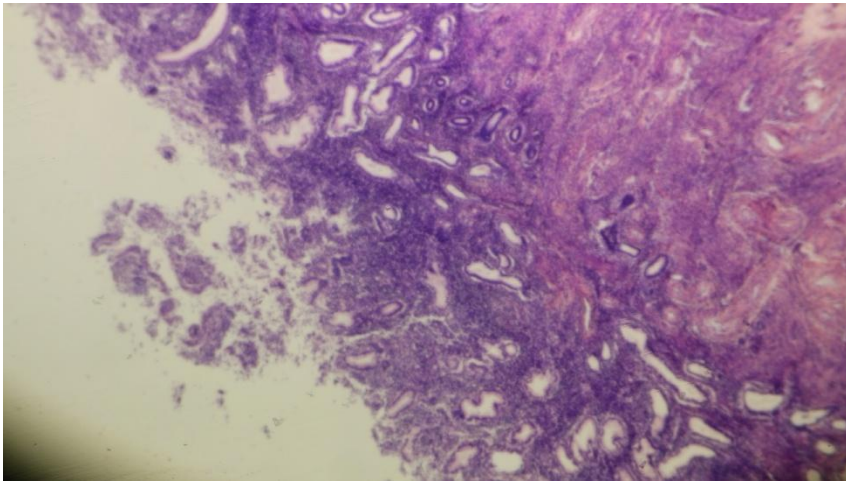




# Menstrual phase

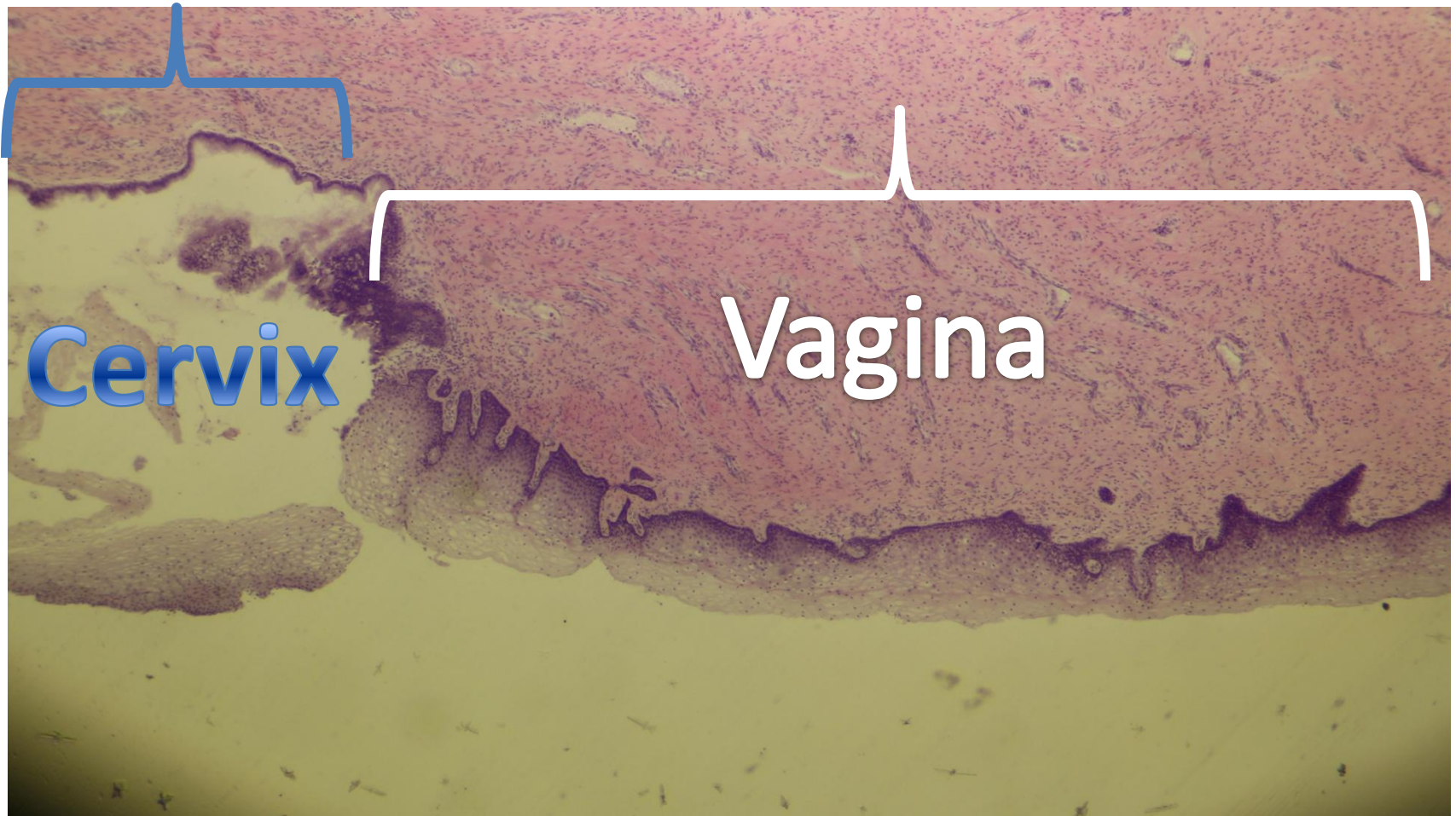


# Menstrual phase

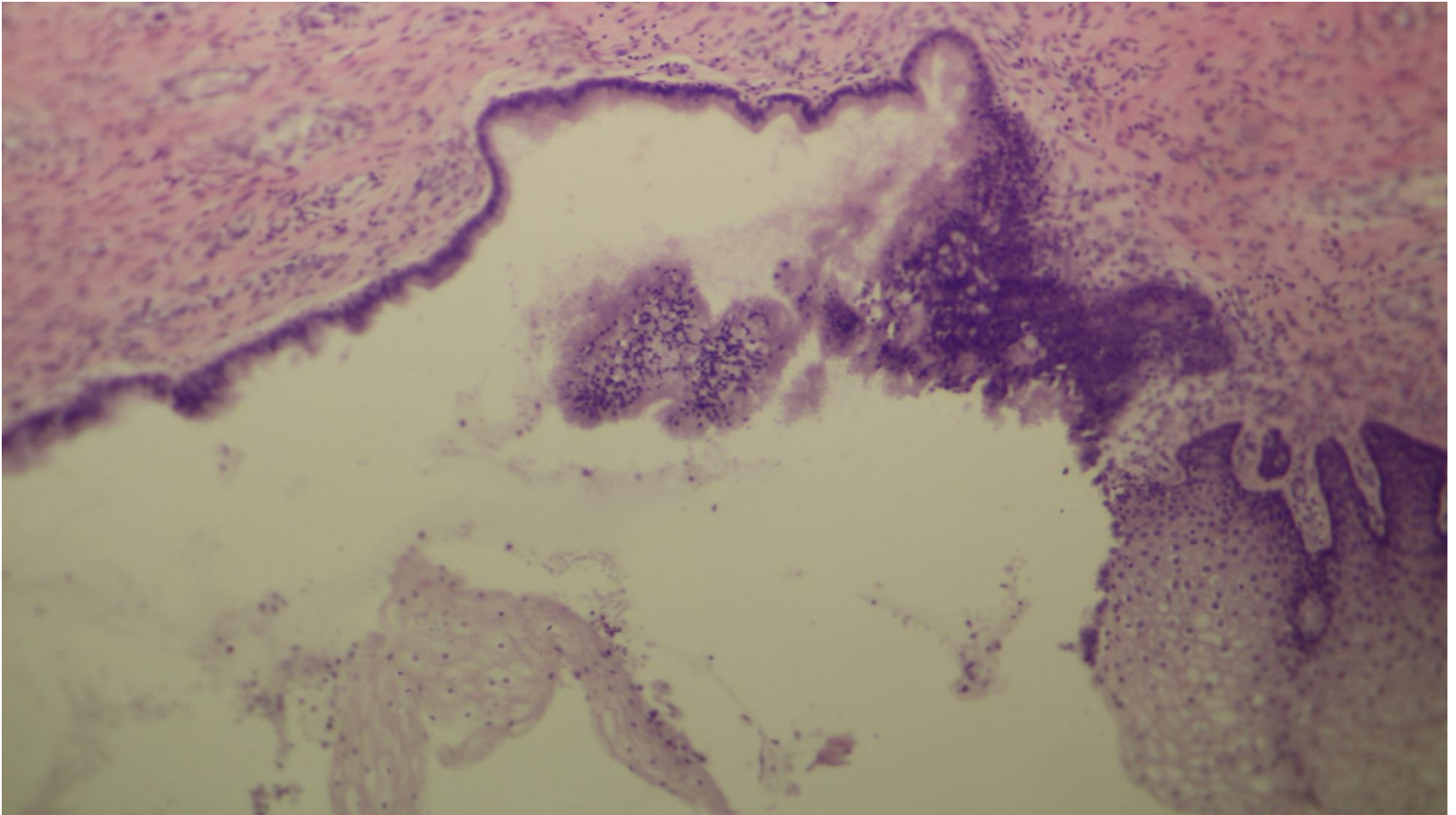




# Cervico-vaginal junction

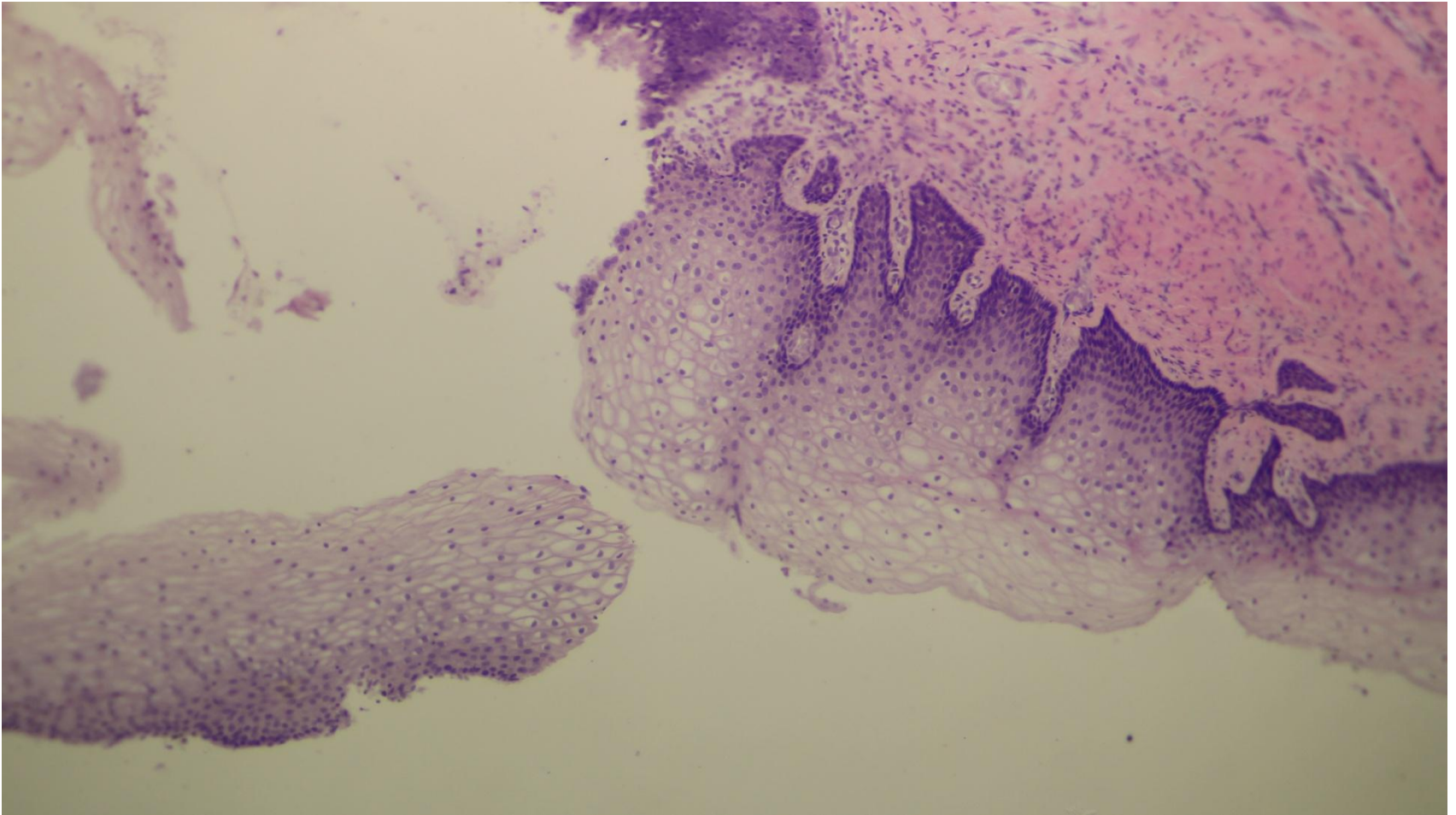


# Cervico-vaginal junction

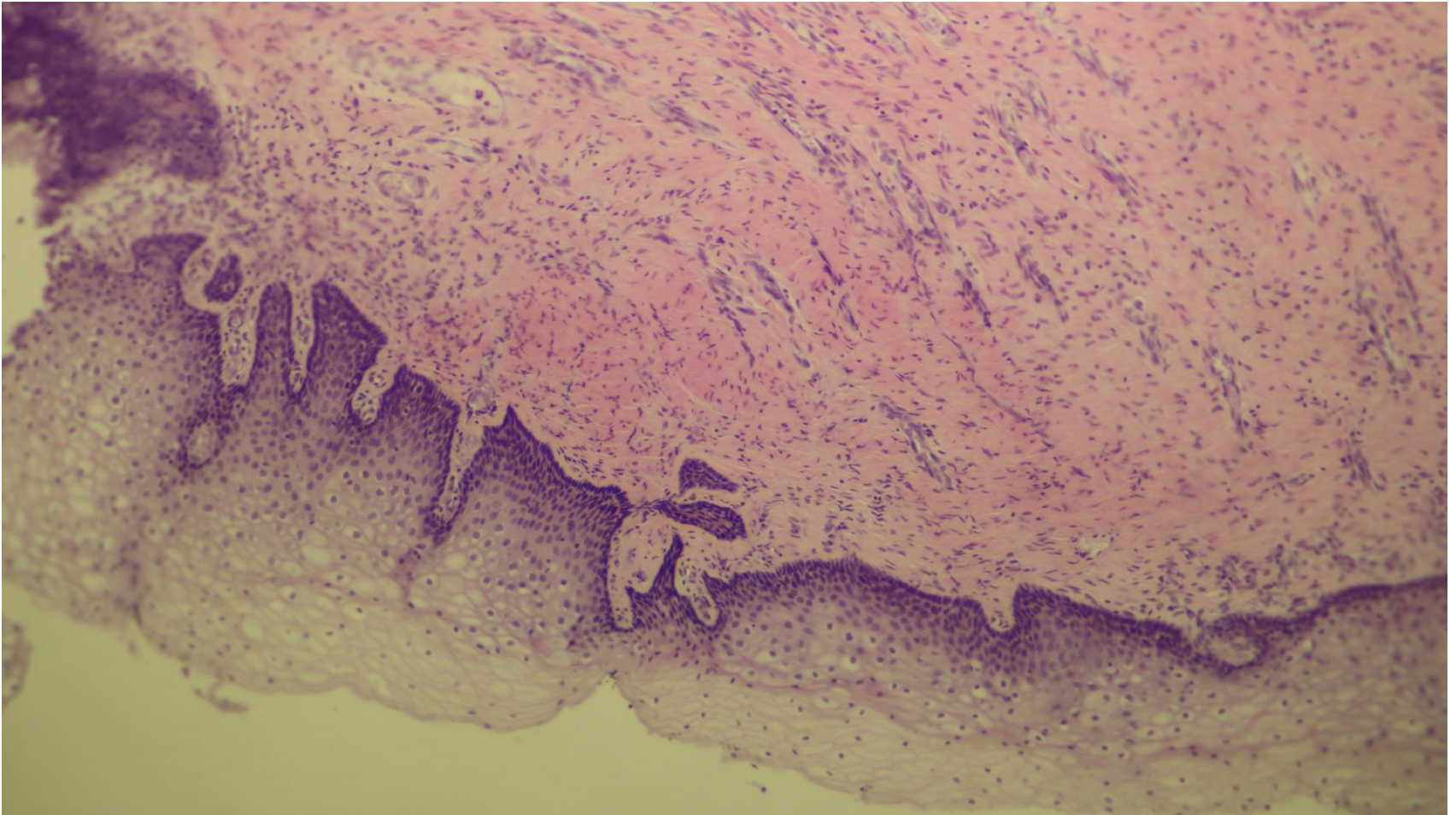




# Vagina

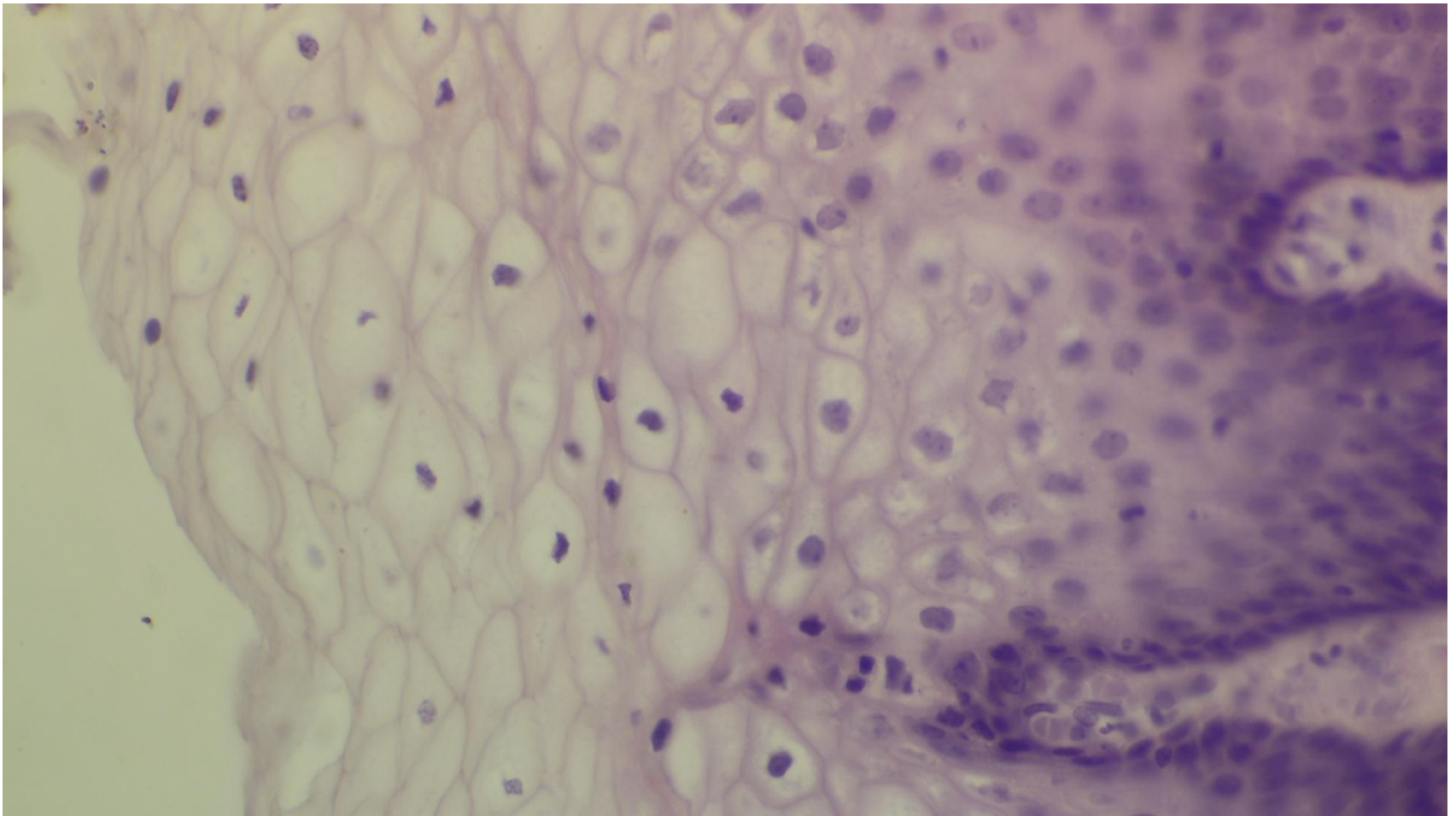


# Vagina

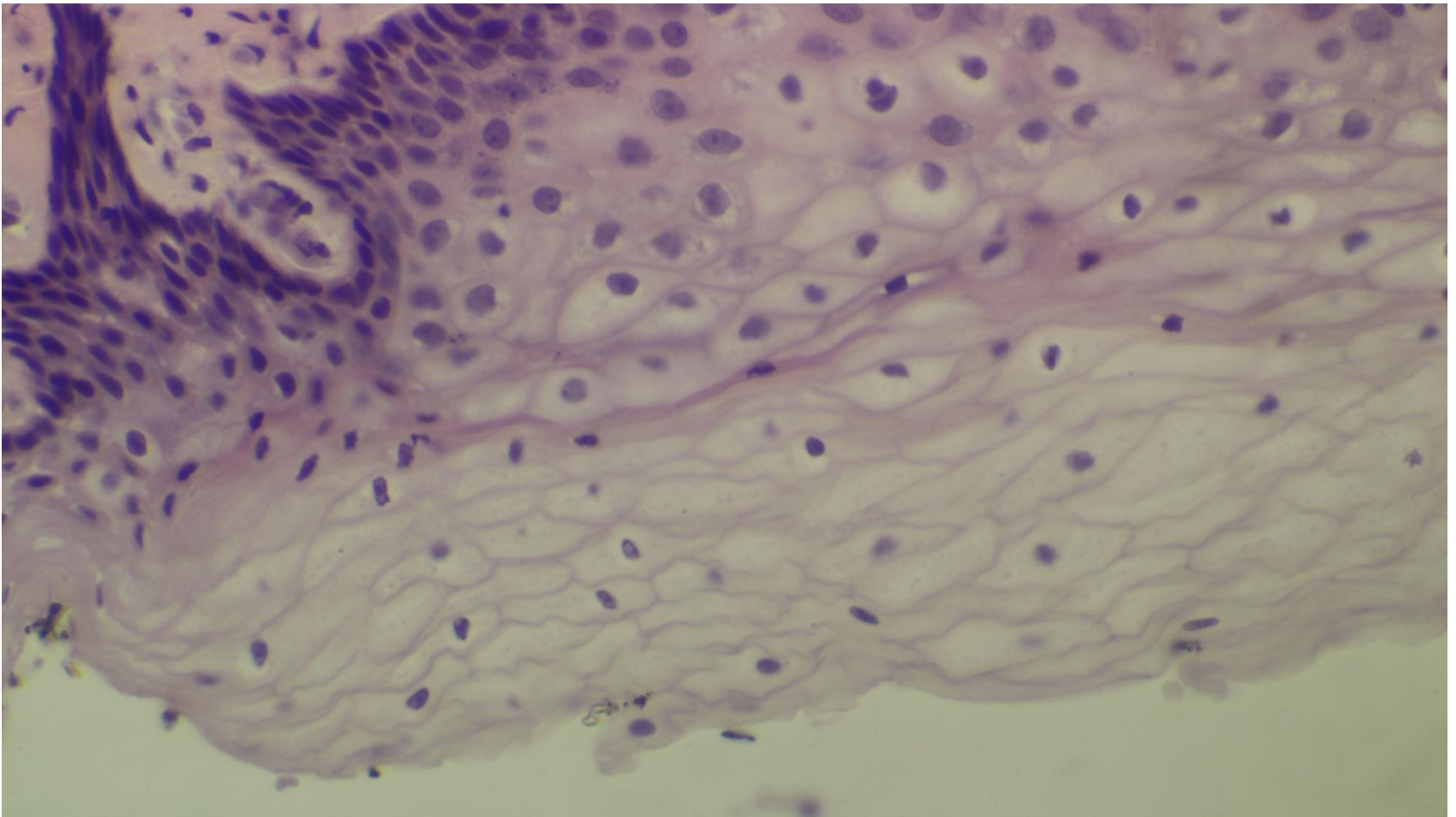




# Vaginal epithelium

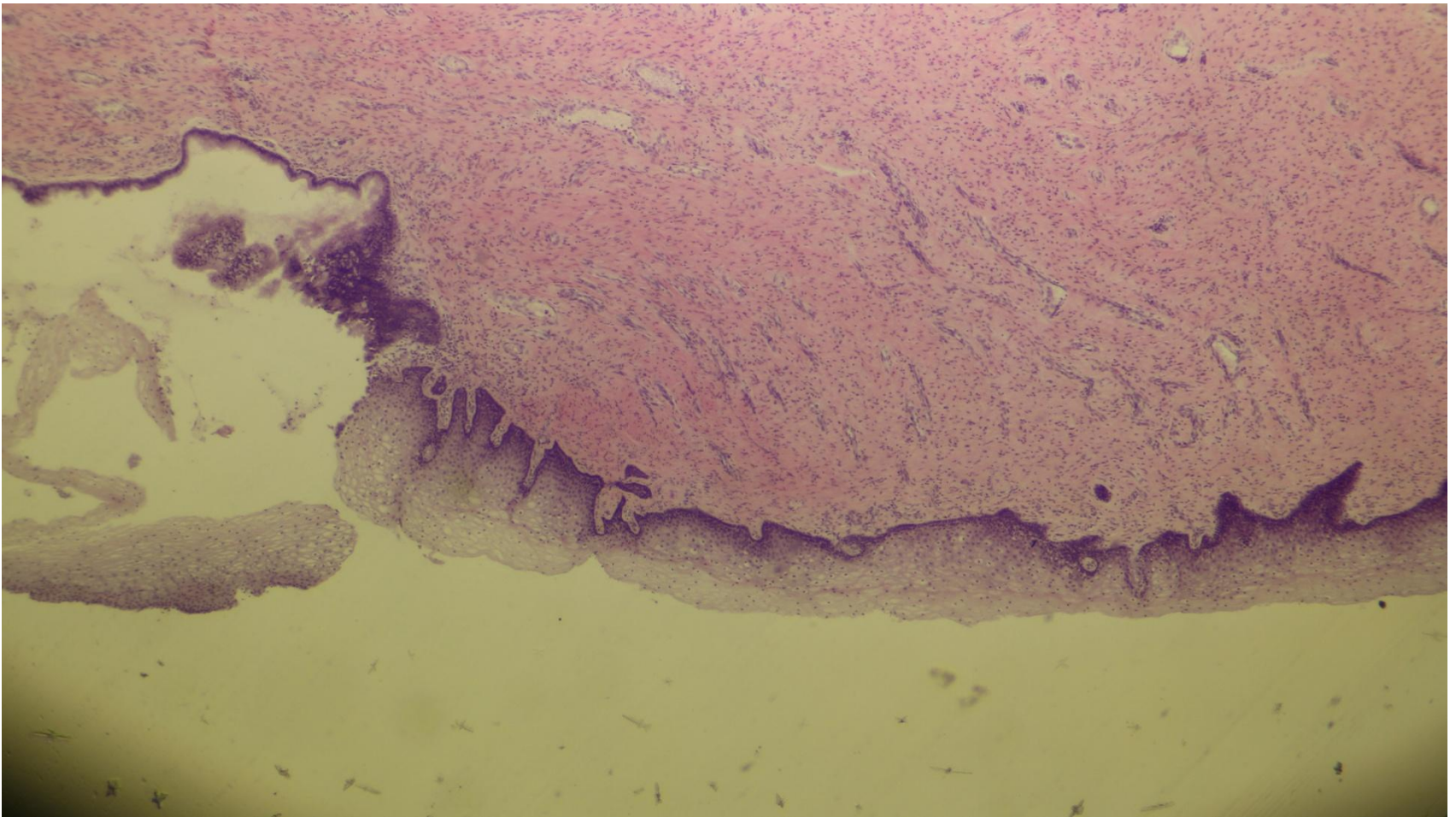


# Vaginal epithelium

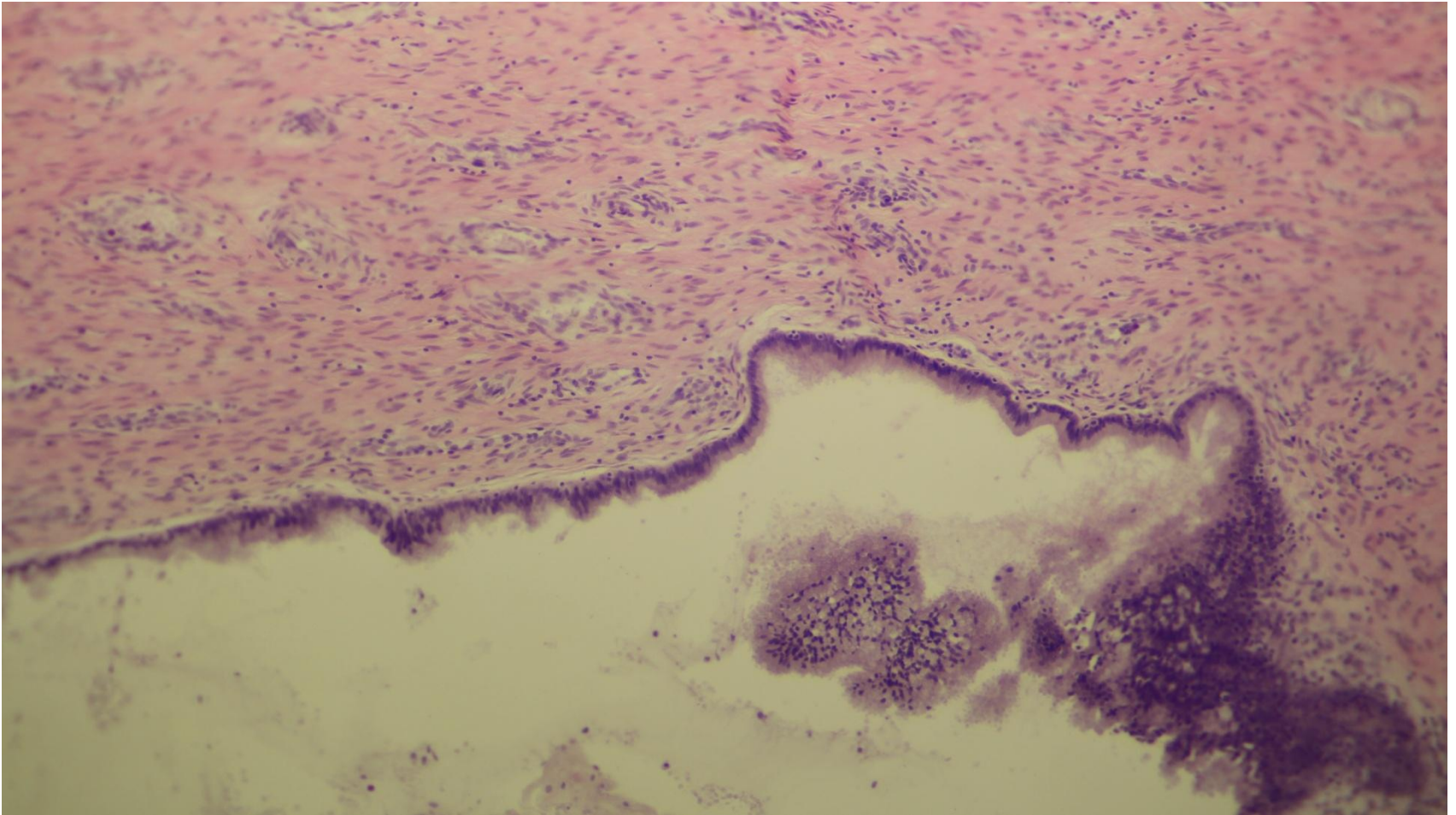




# Cervico-vaginal junction

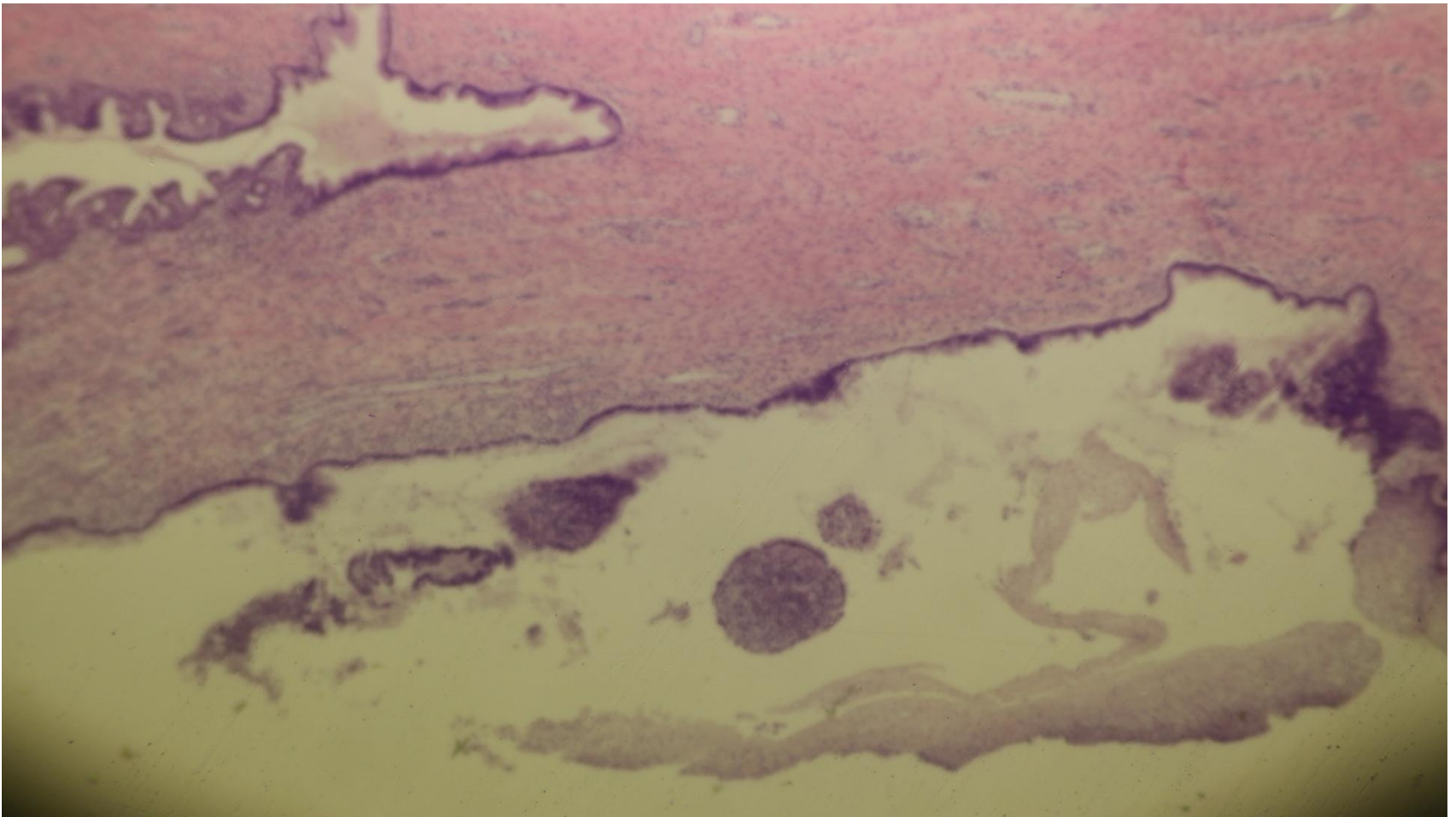


# Cervix

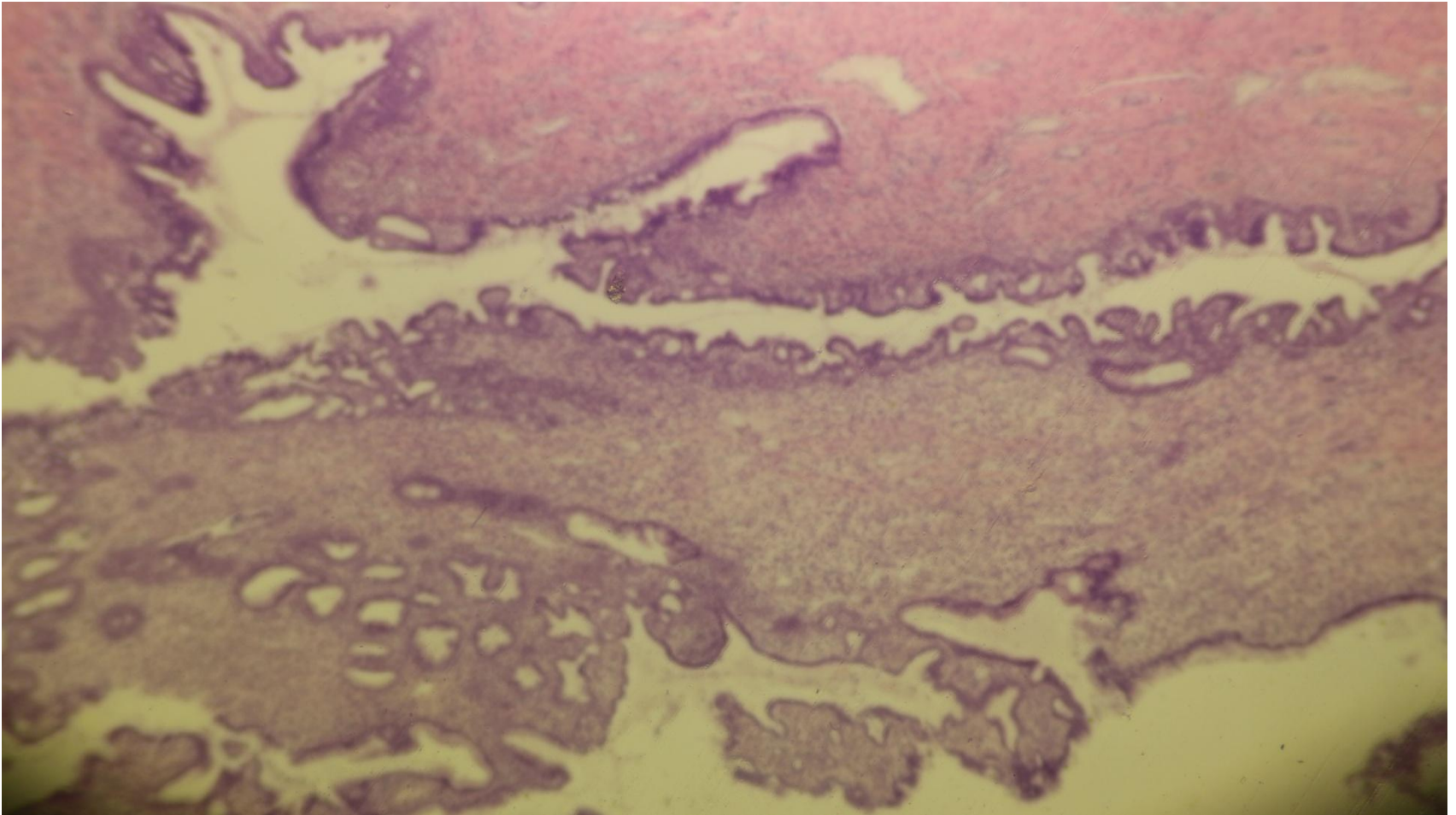




# Cervix

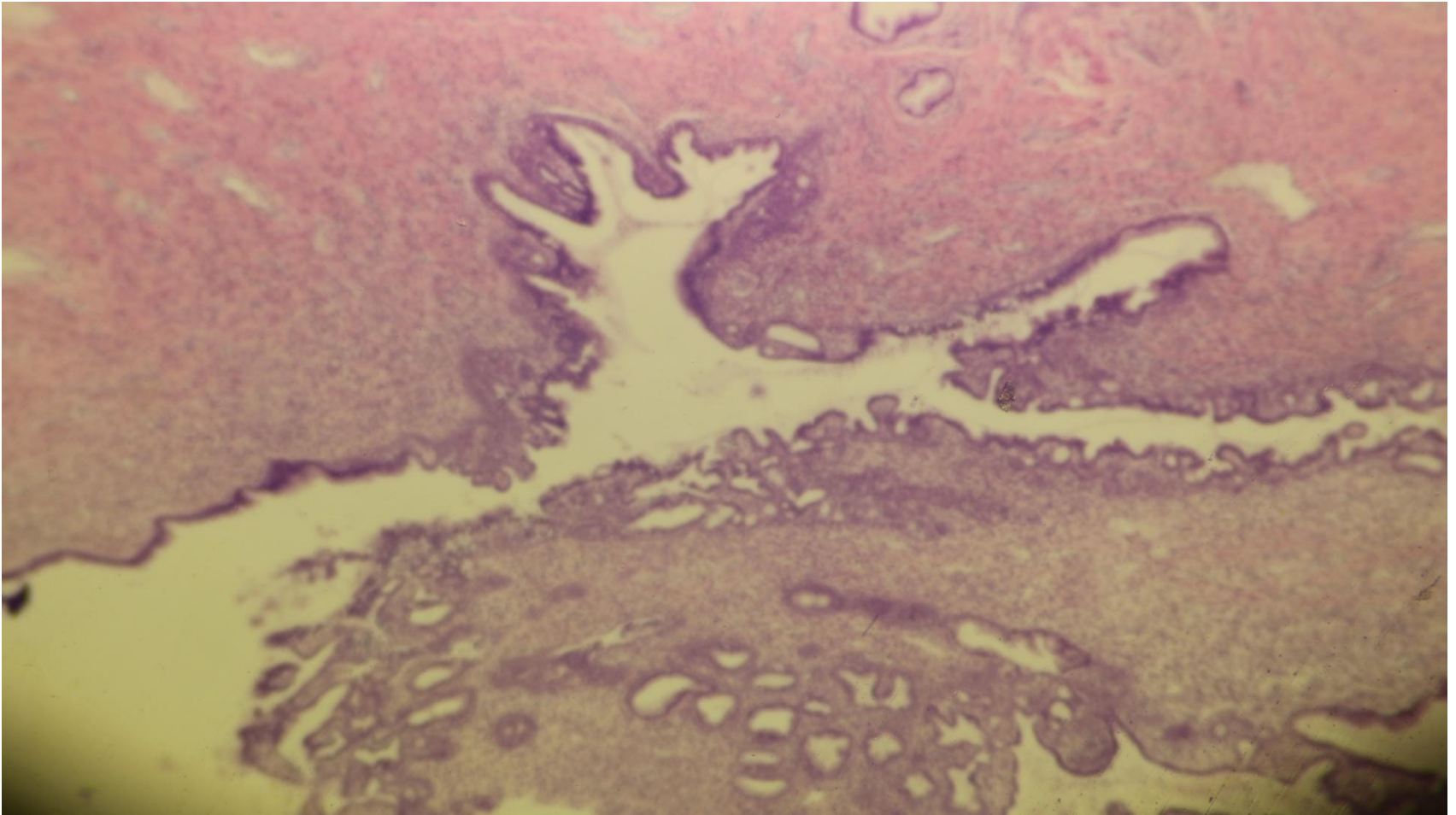


# Cervical glands

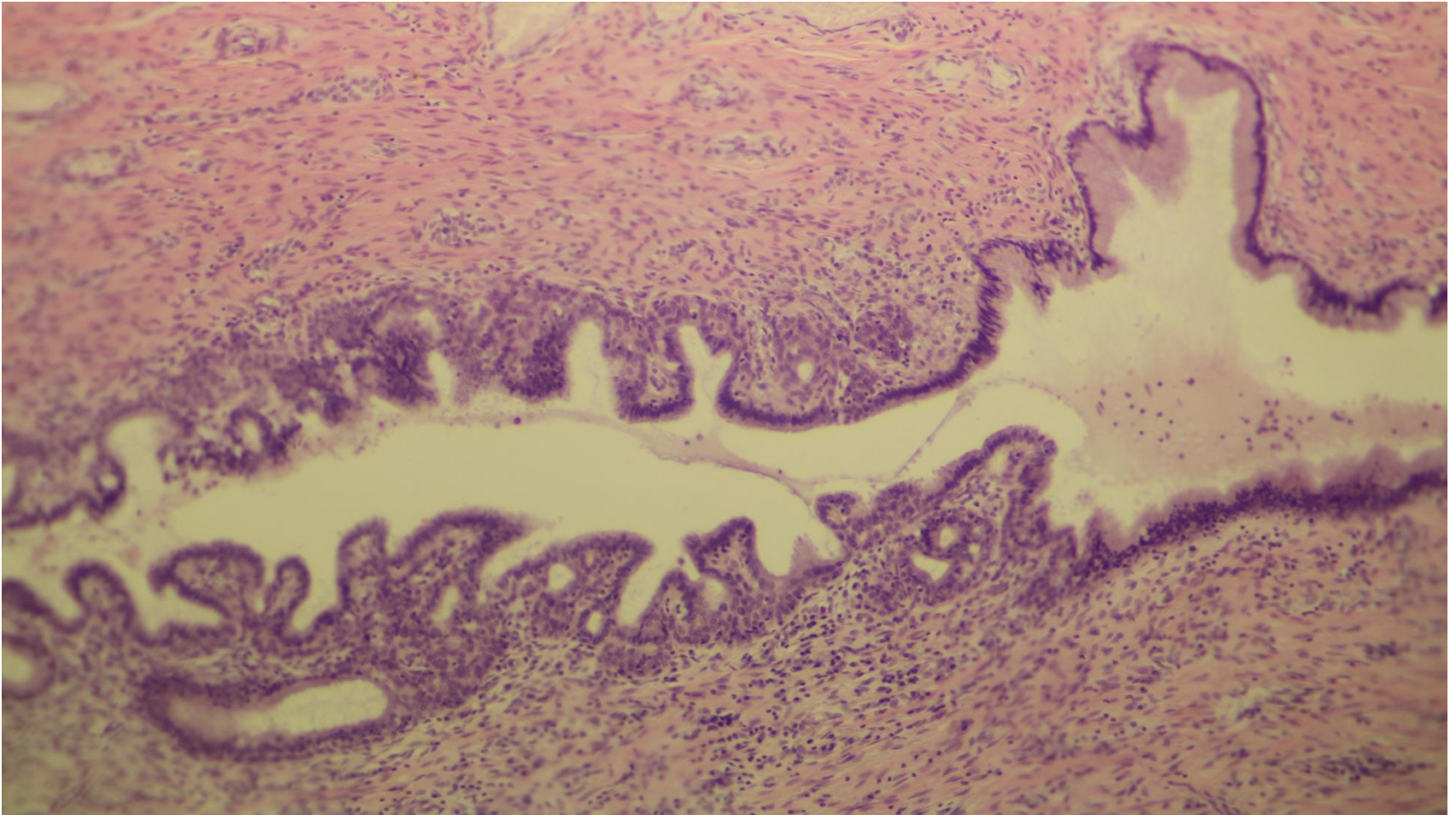




# Cervical glands

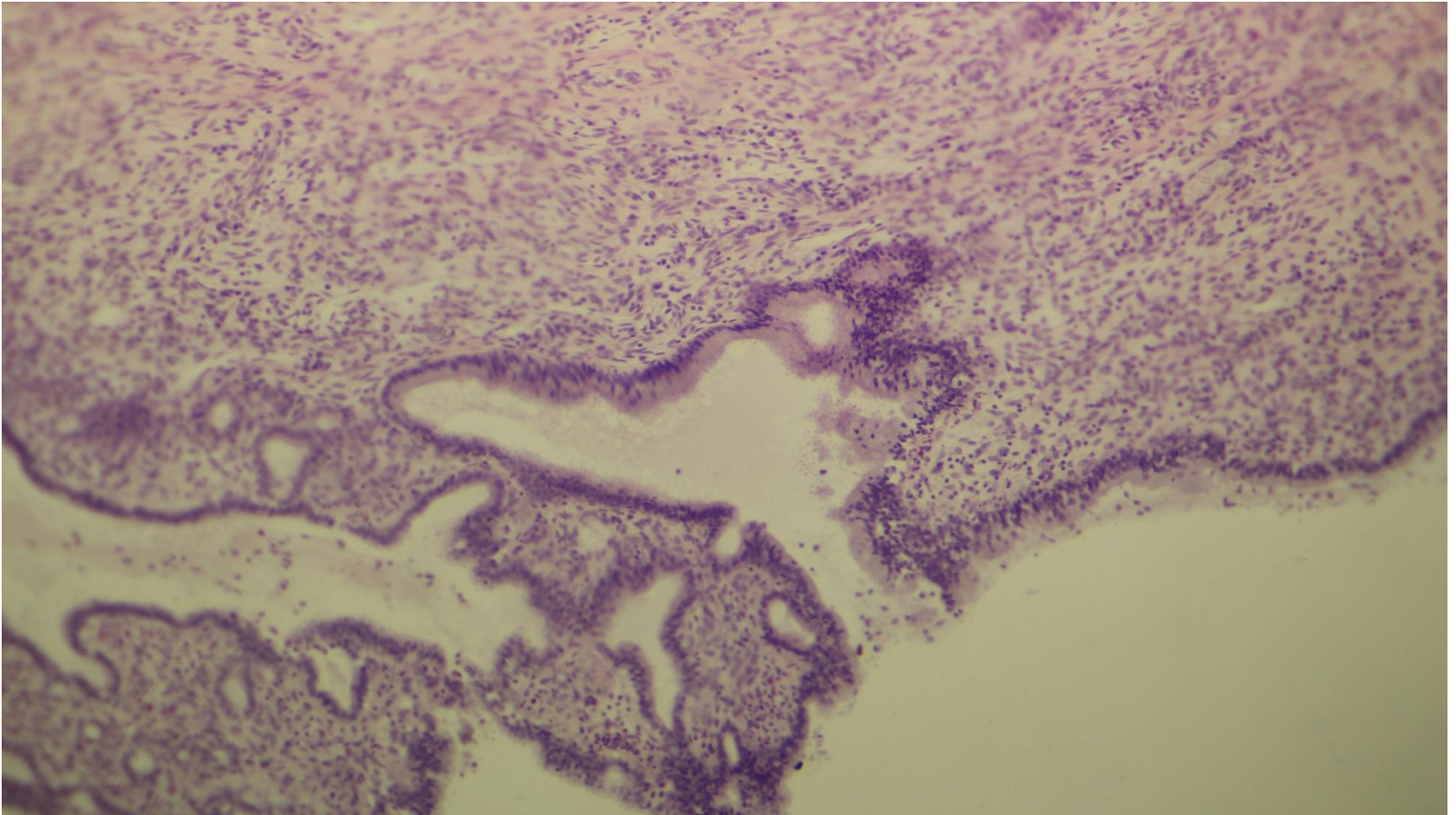


# Cervical glands

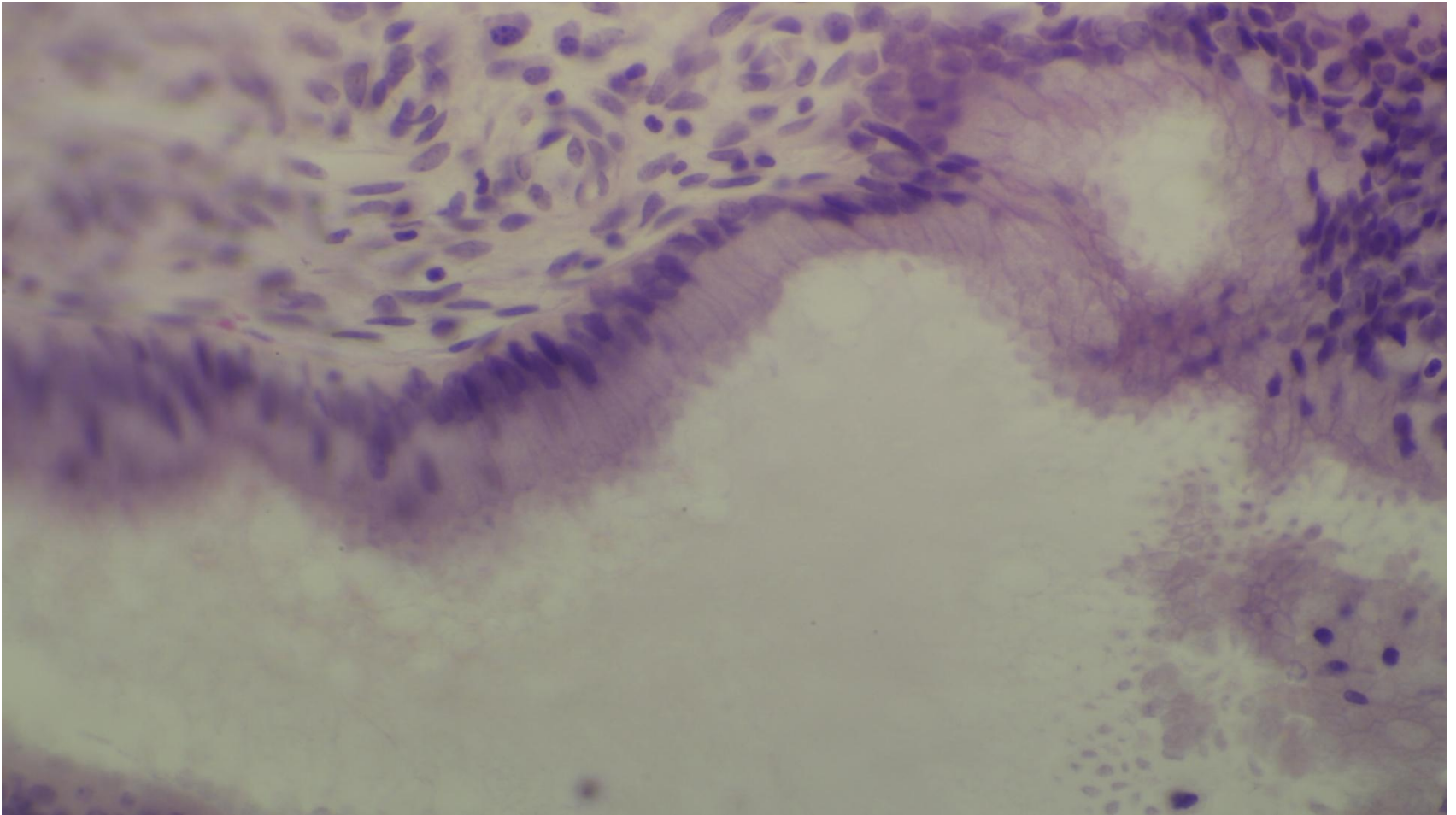




# Cervical glands

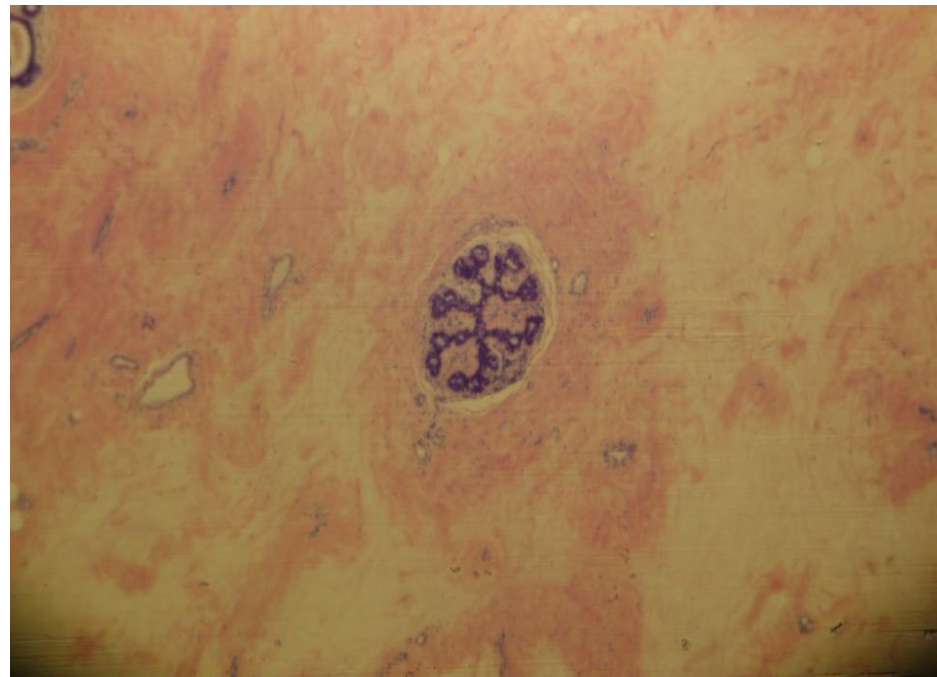
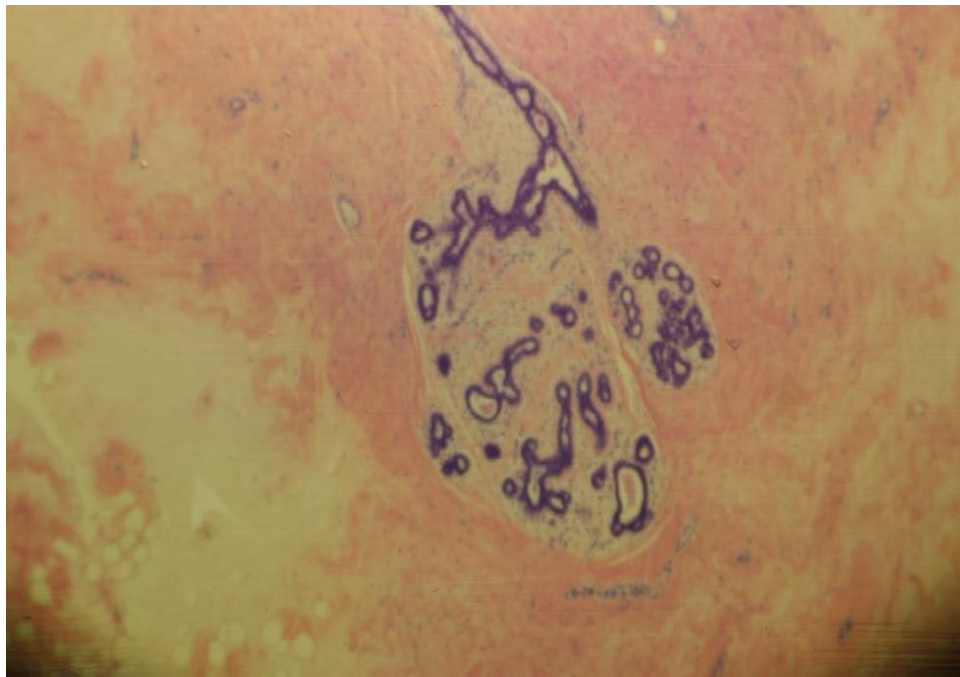


# Cervical epithelium

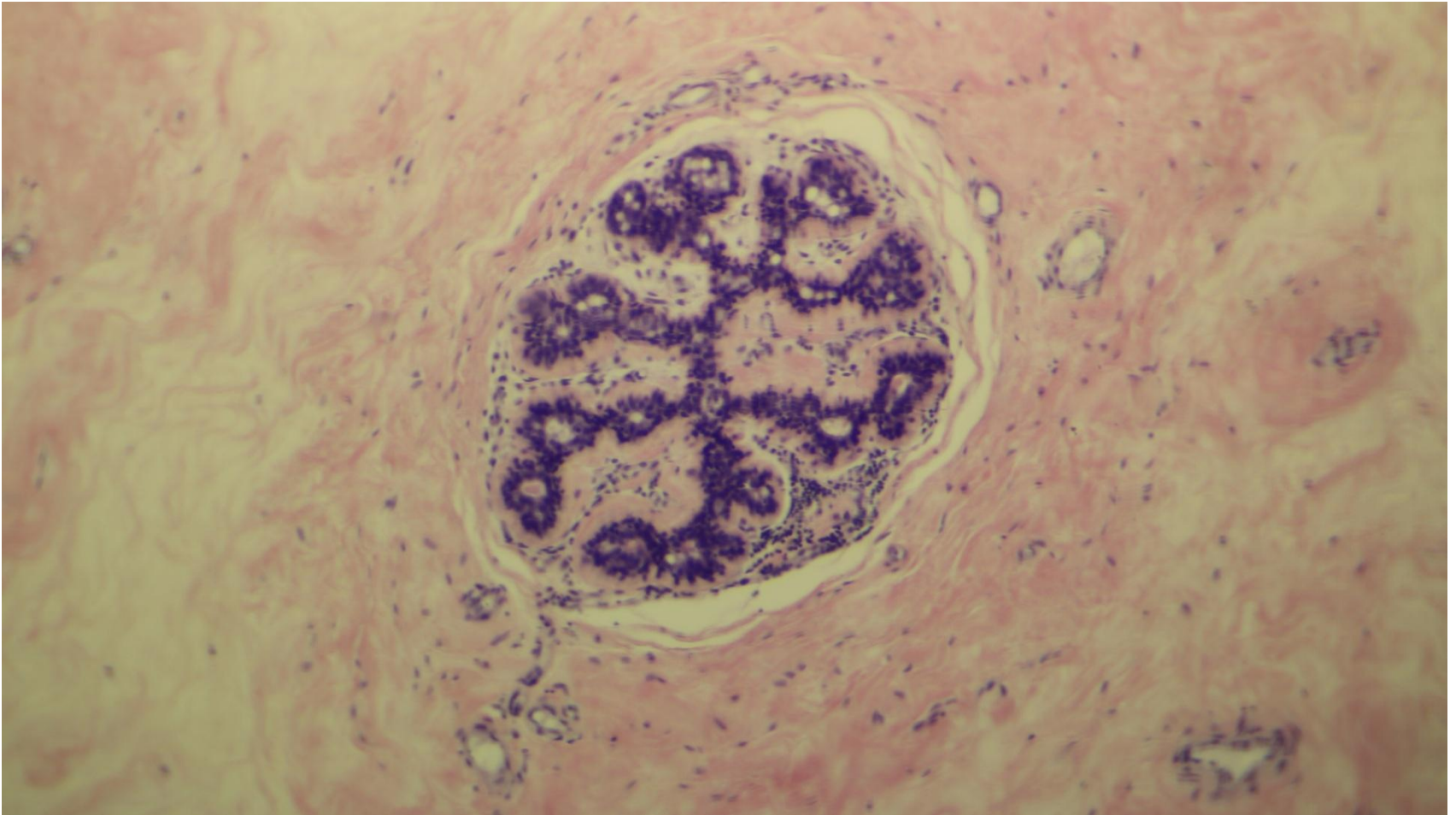




# Mammary gland (inactive)

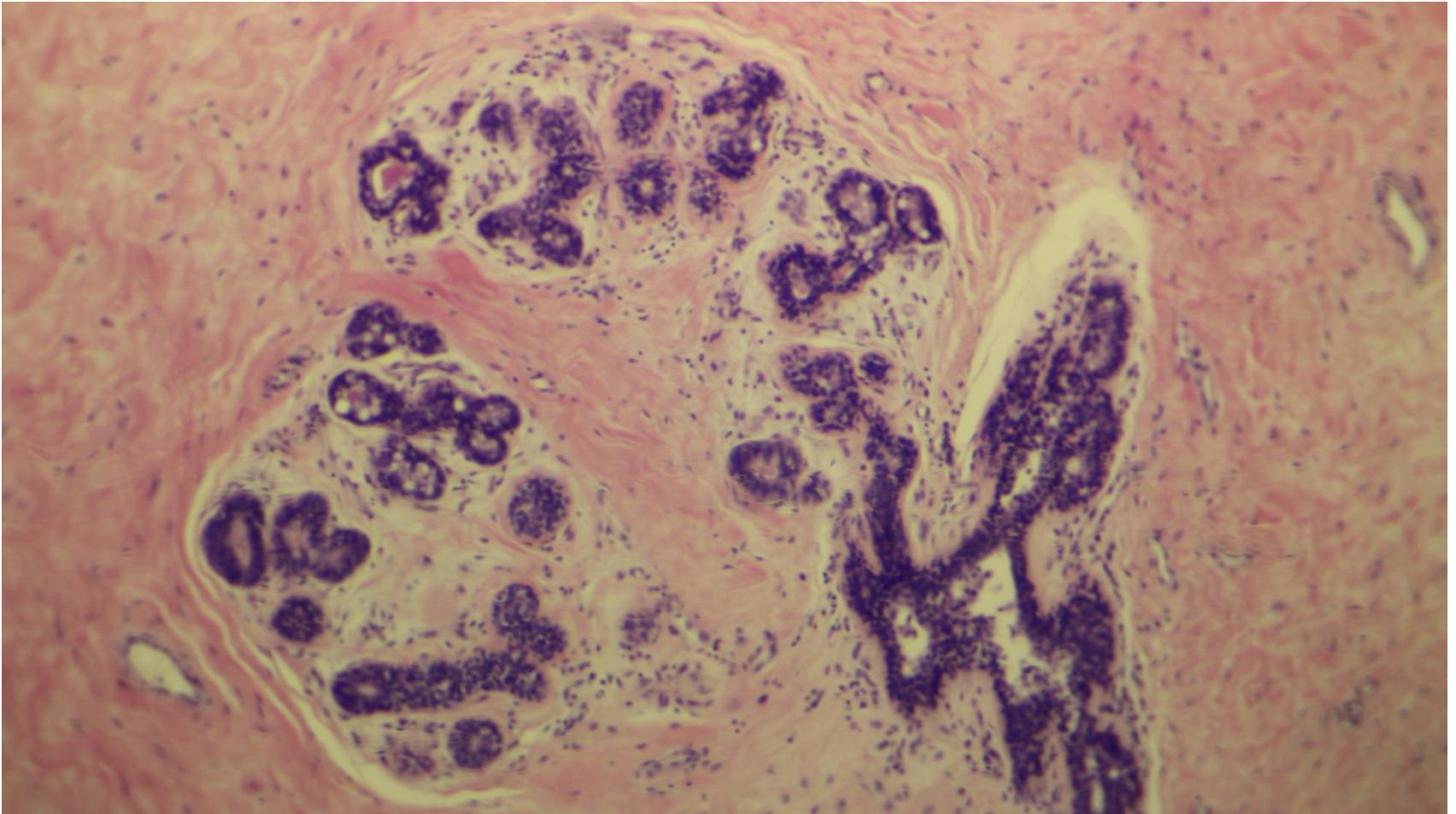


# Mammary gland (inactive)

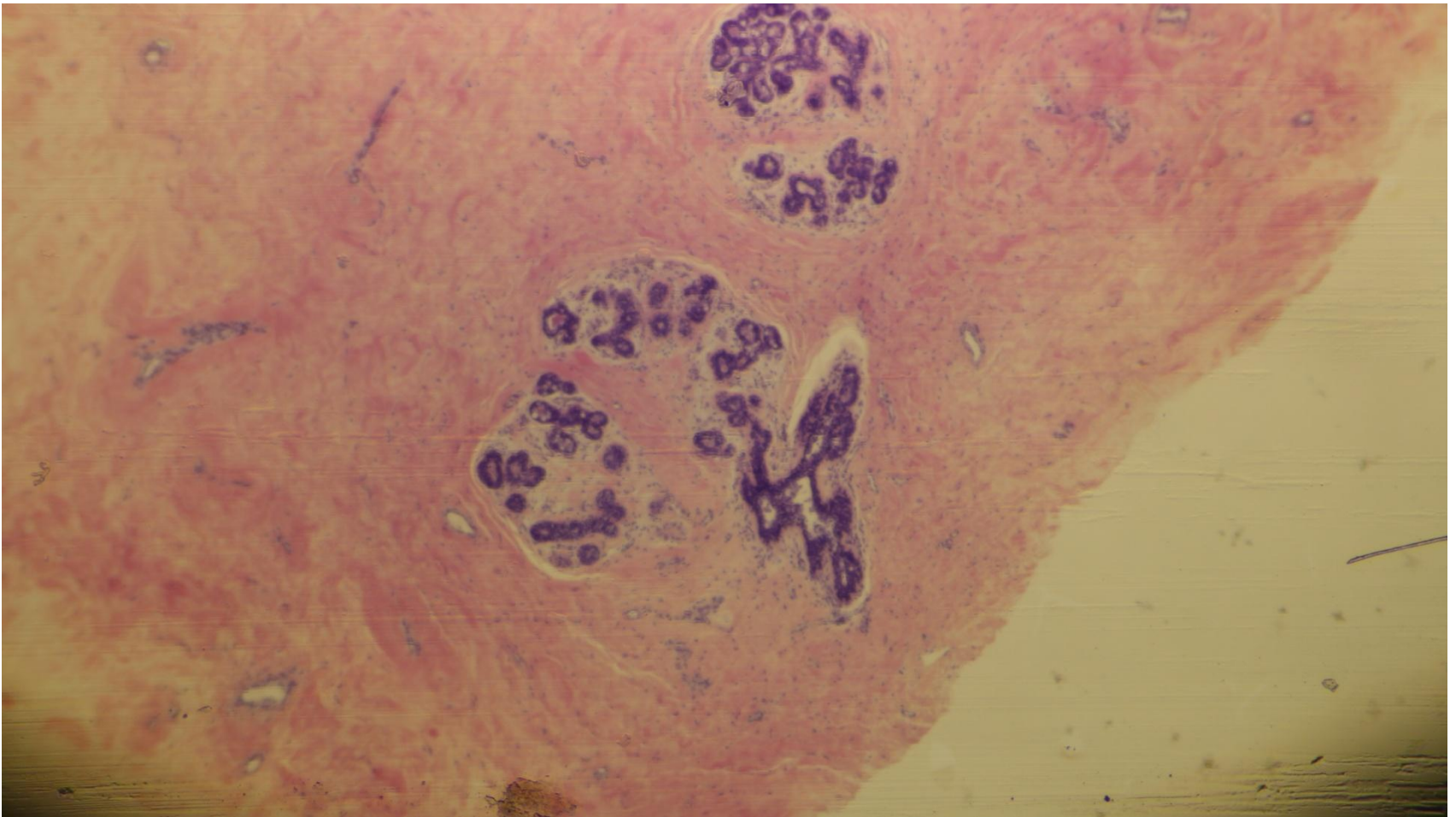




# Mammary gland (inactive)

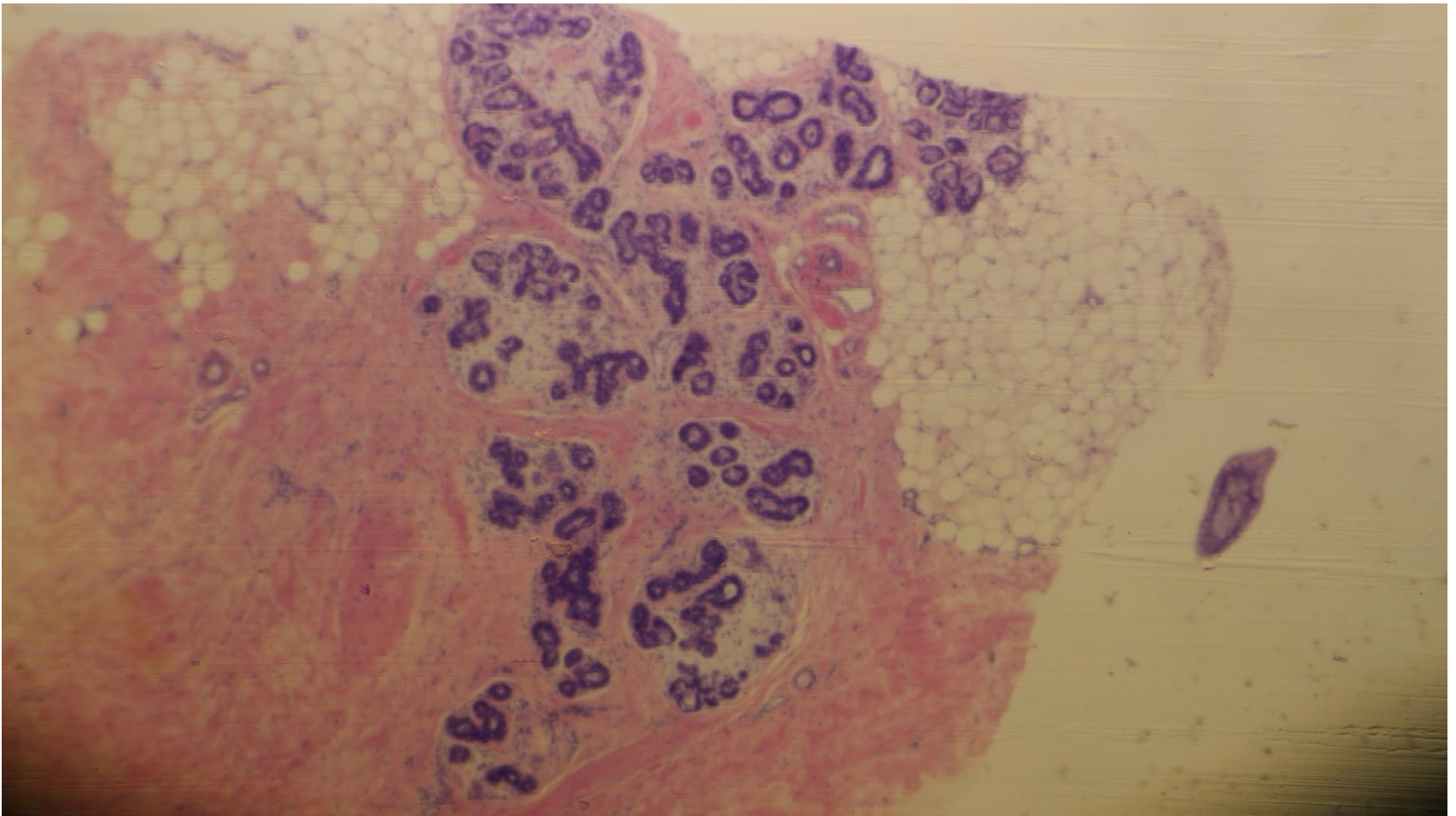


# Mammary gland (inactive)

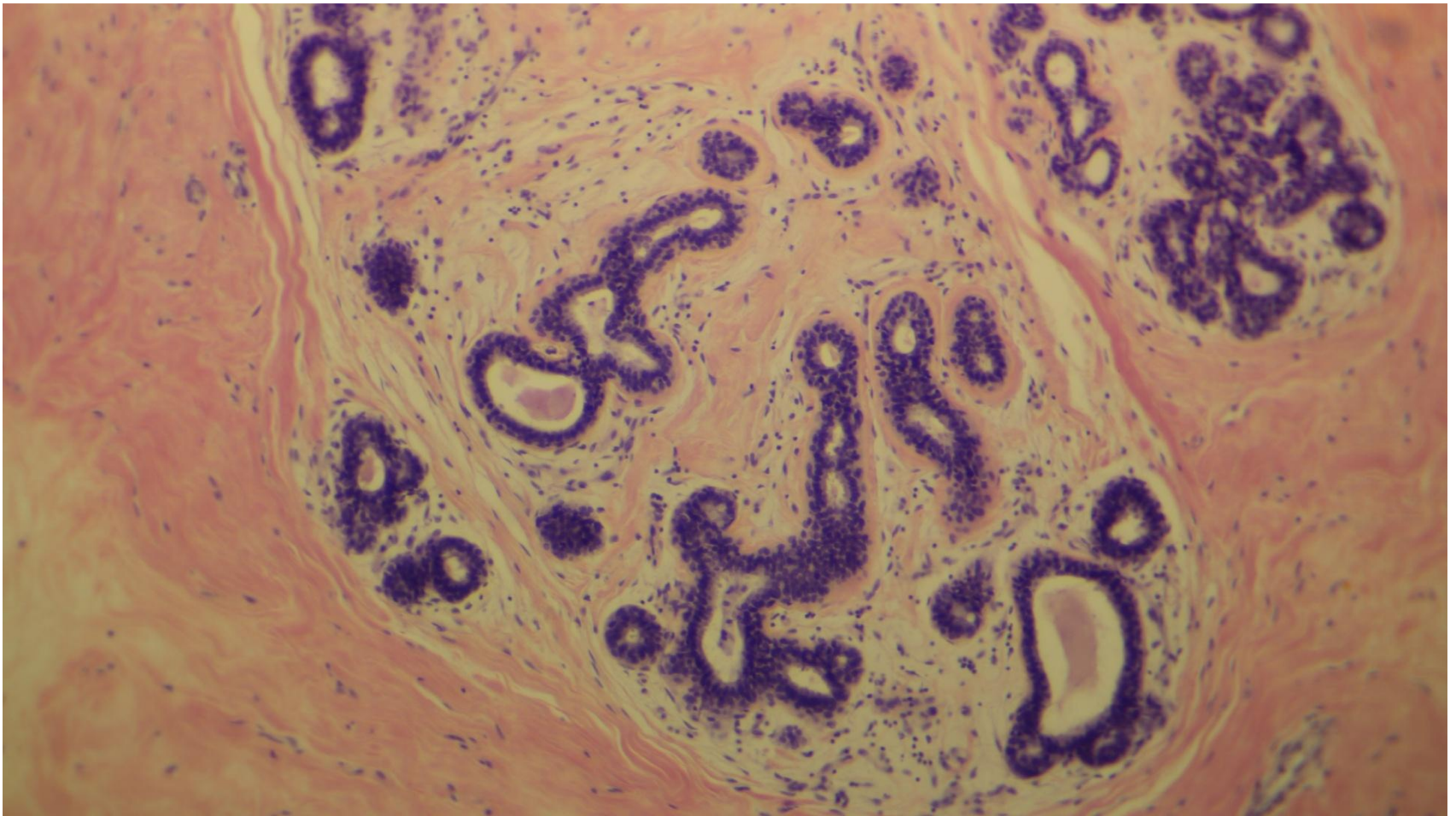




# Mammary gland (inactive)

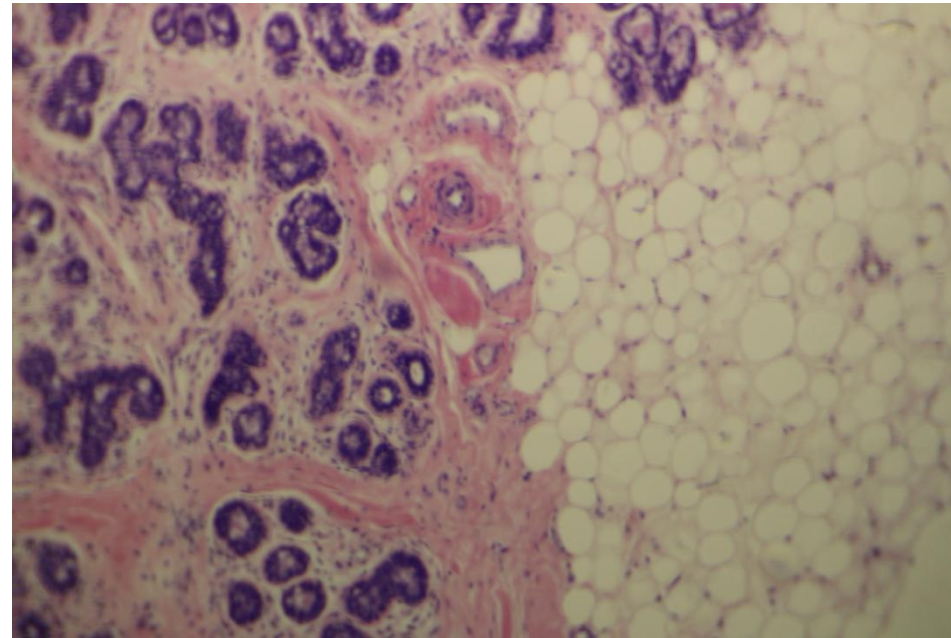
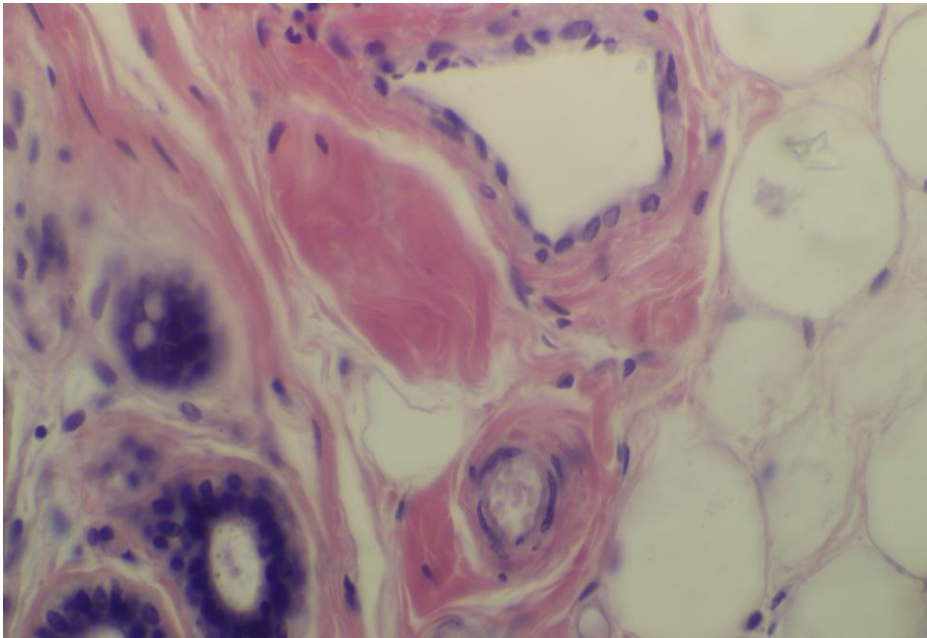


# Mammary gland (inactive)

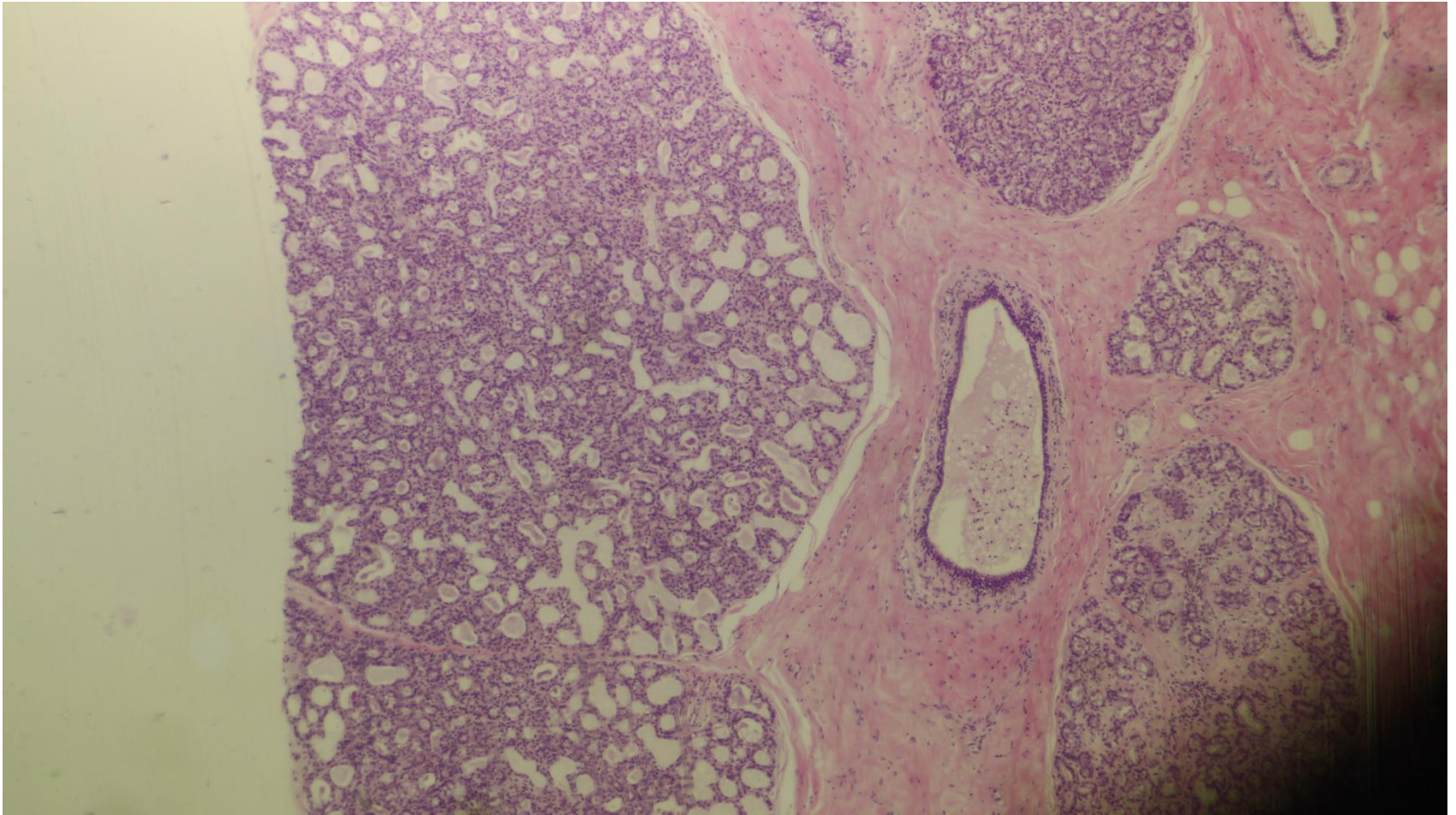




# Arteriole and venule

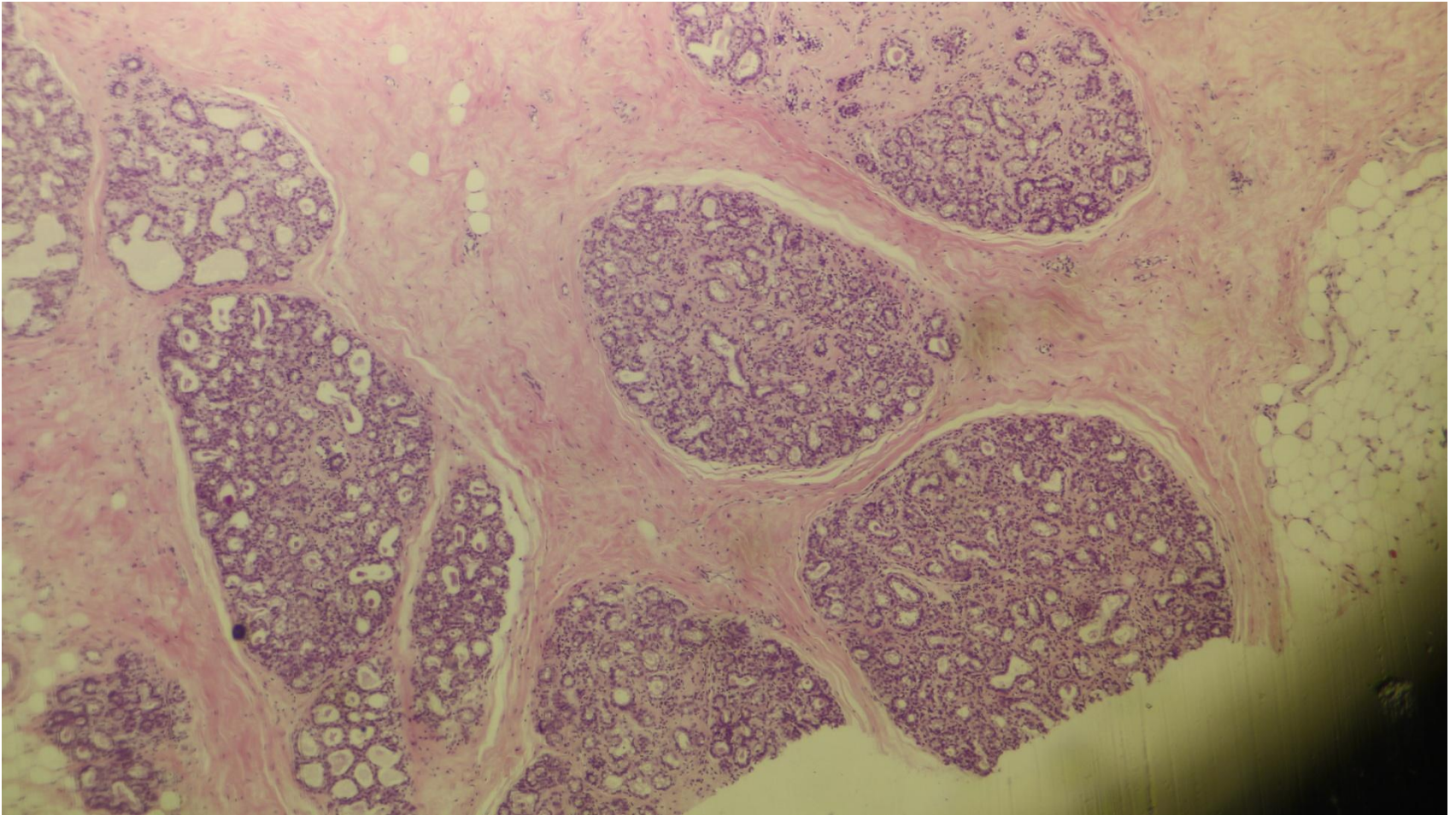


# Mammary gland (active)



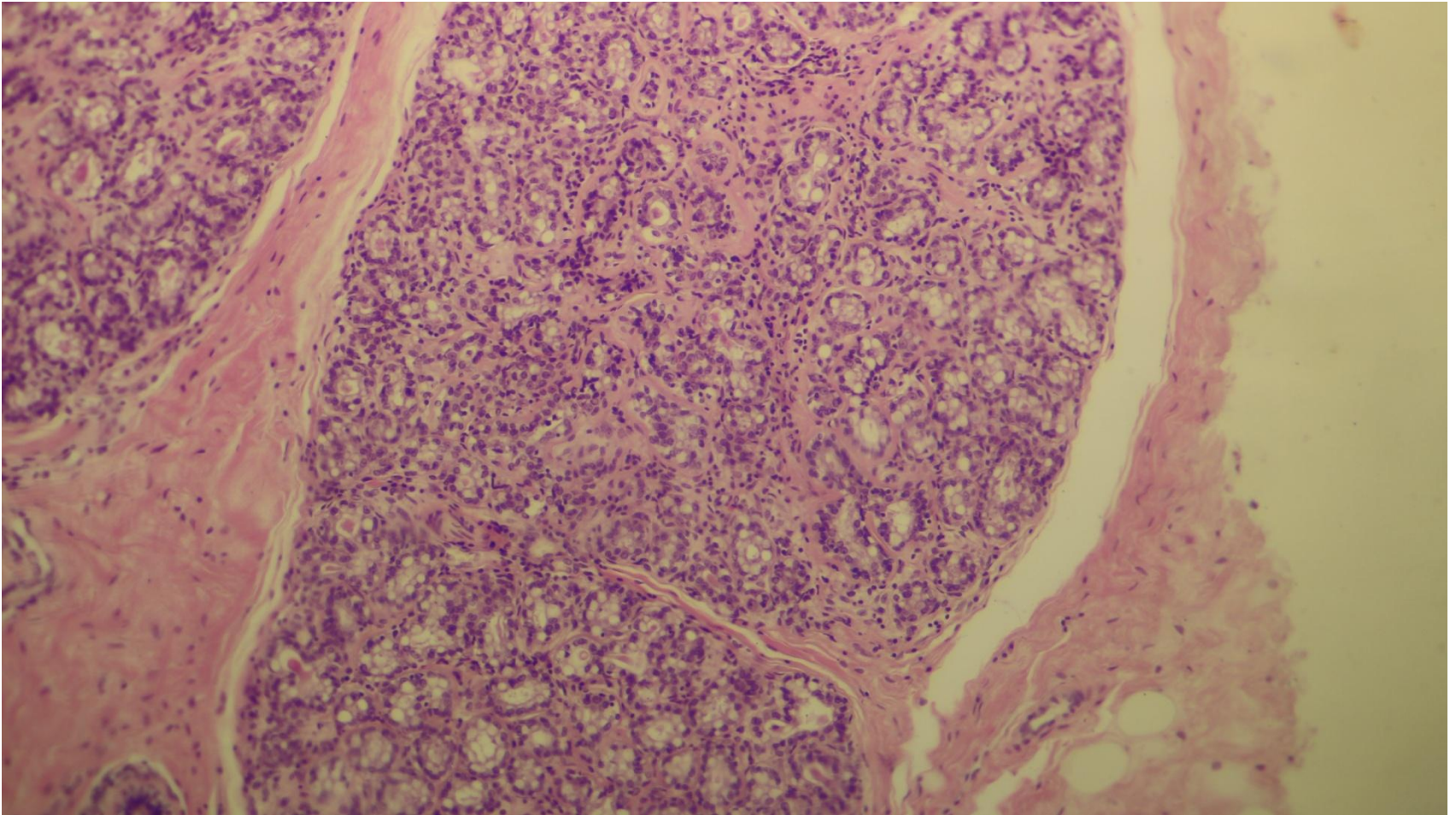


# Mammary gland (active)



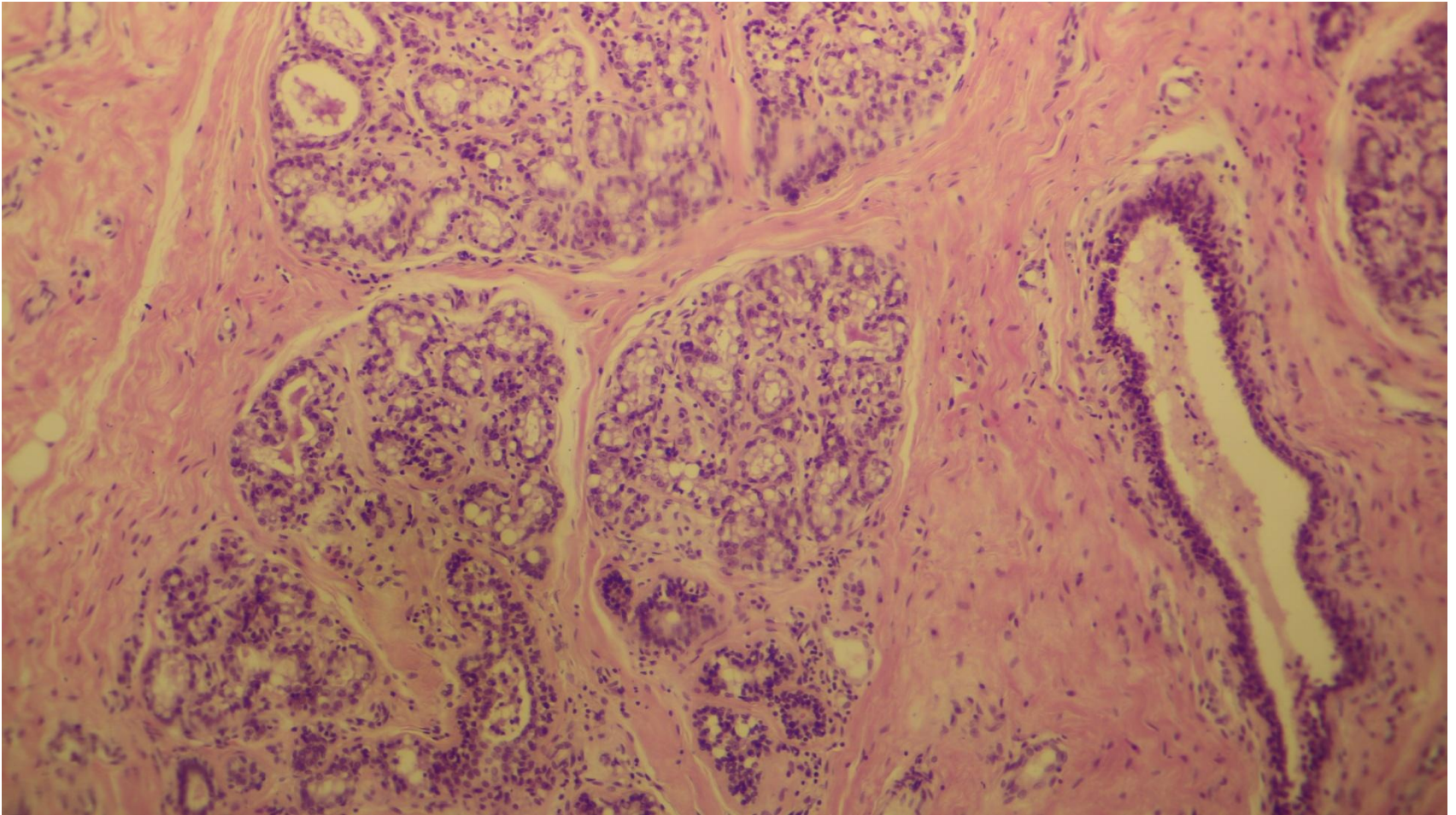


# Mammary gland (active)



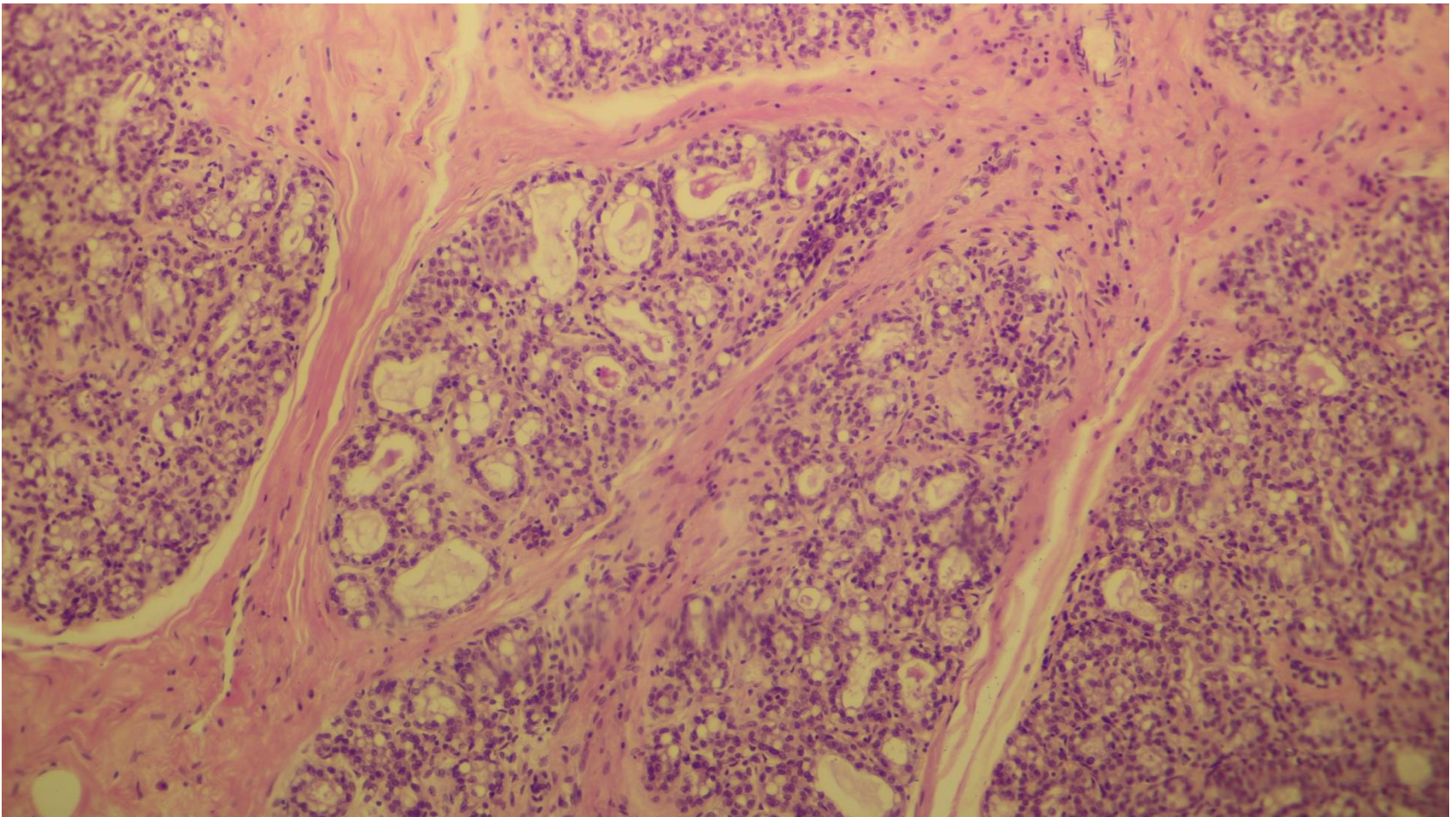


# Active mammary gland+ duct



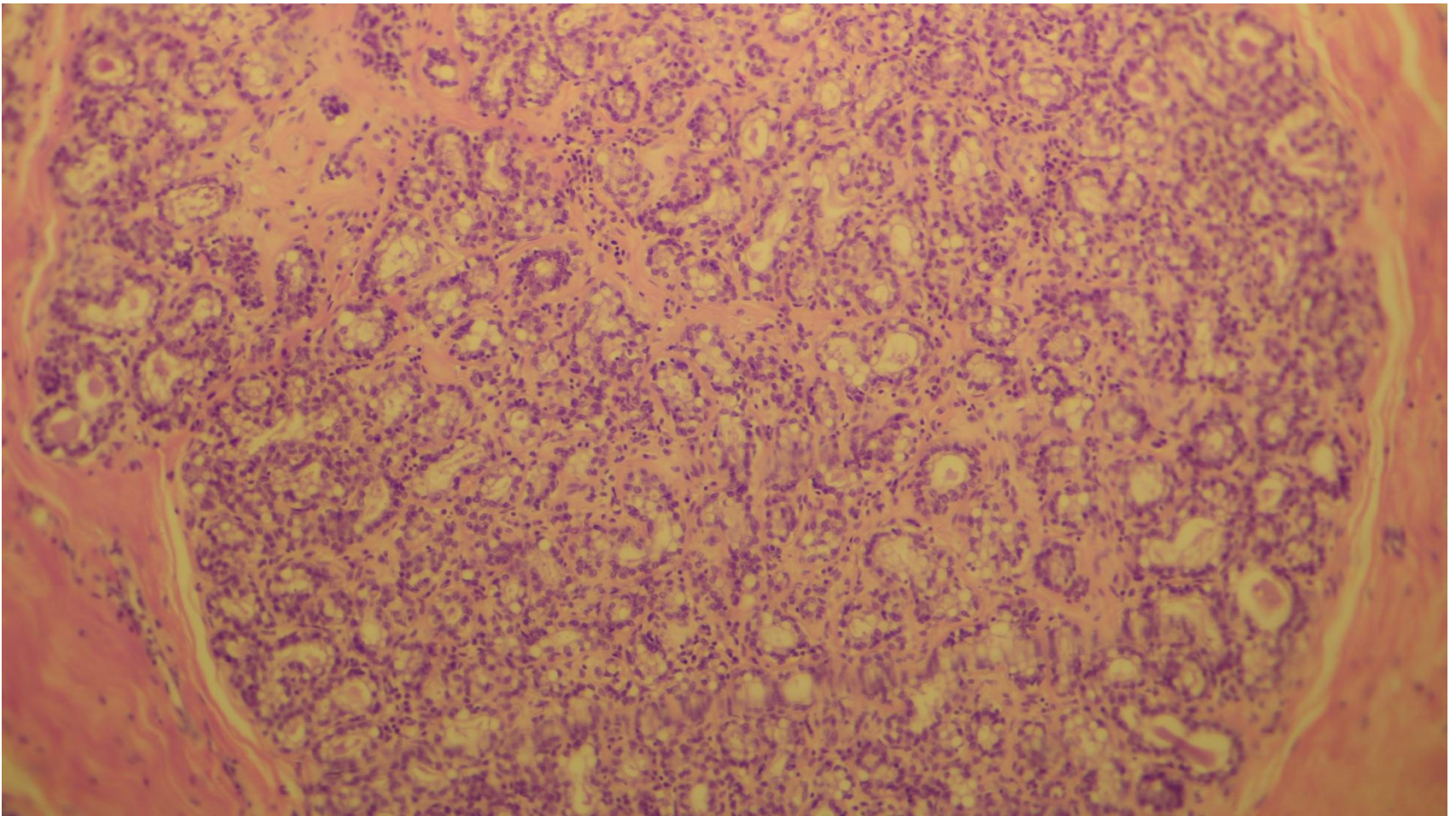


# Mammary gland (active)

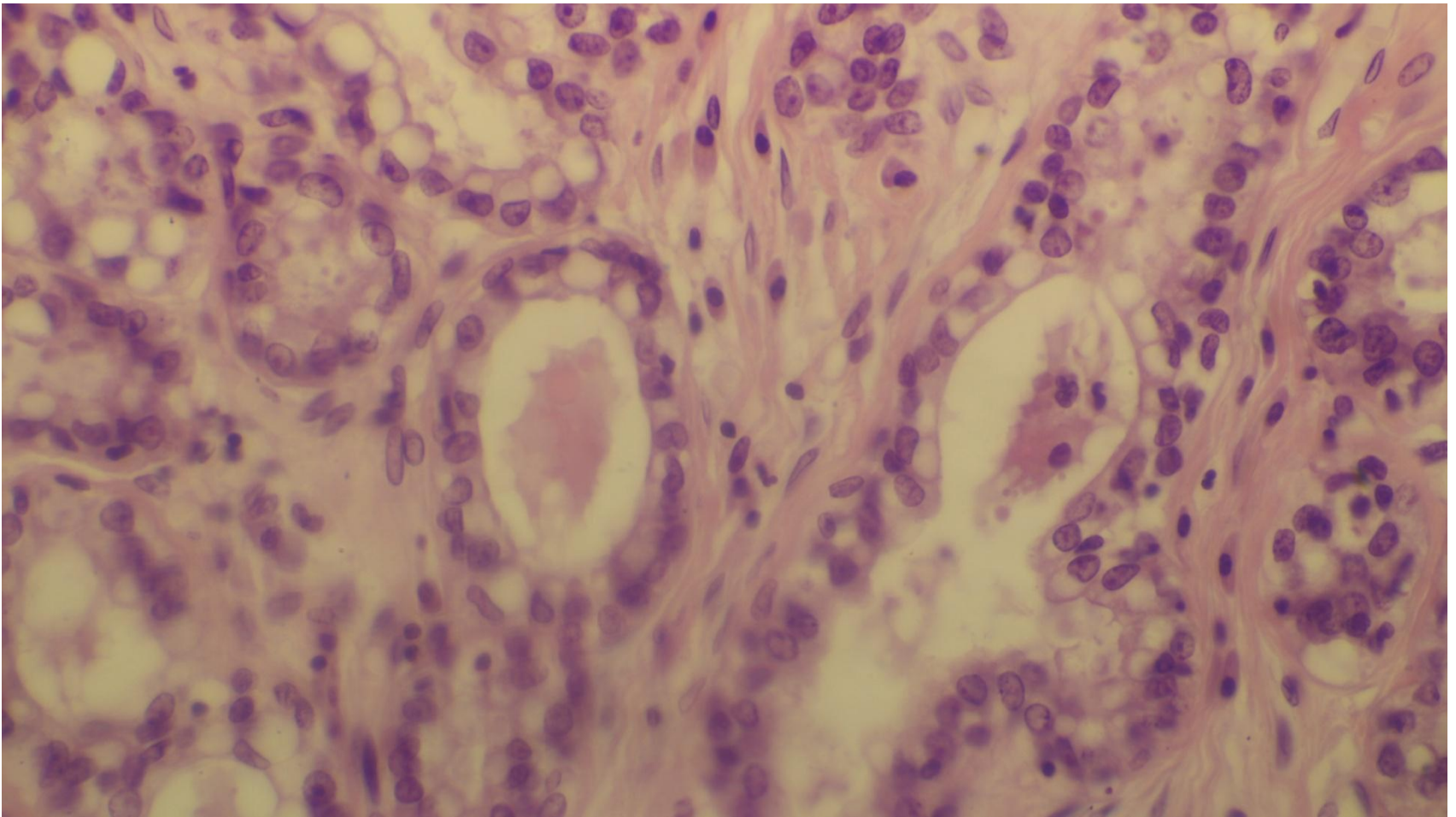




# Mammary gland (active)

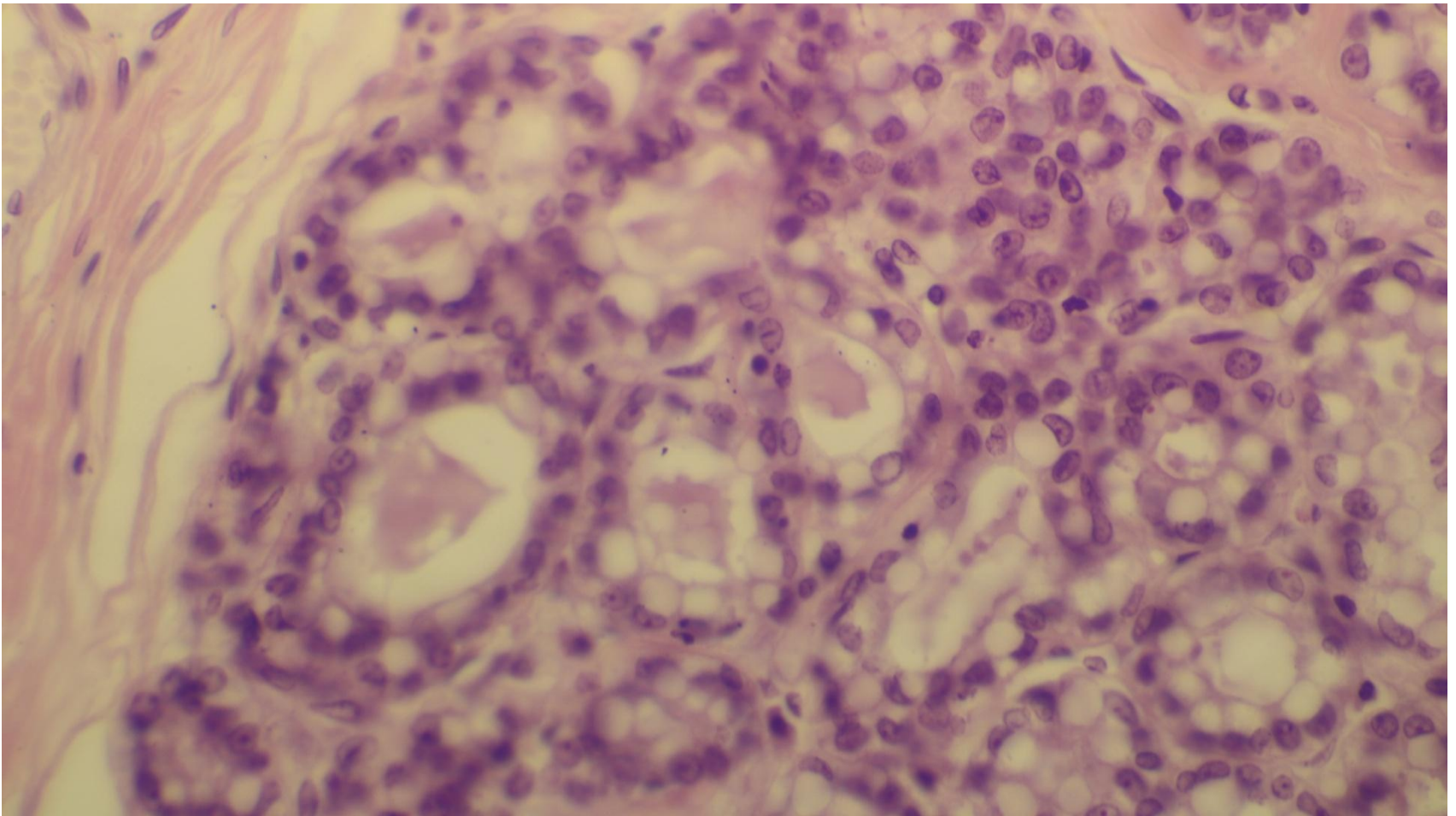


# Mammary gland (active)

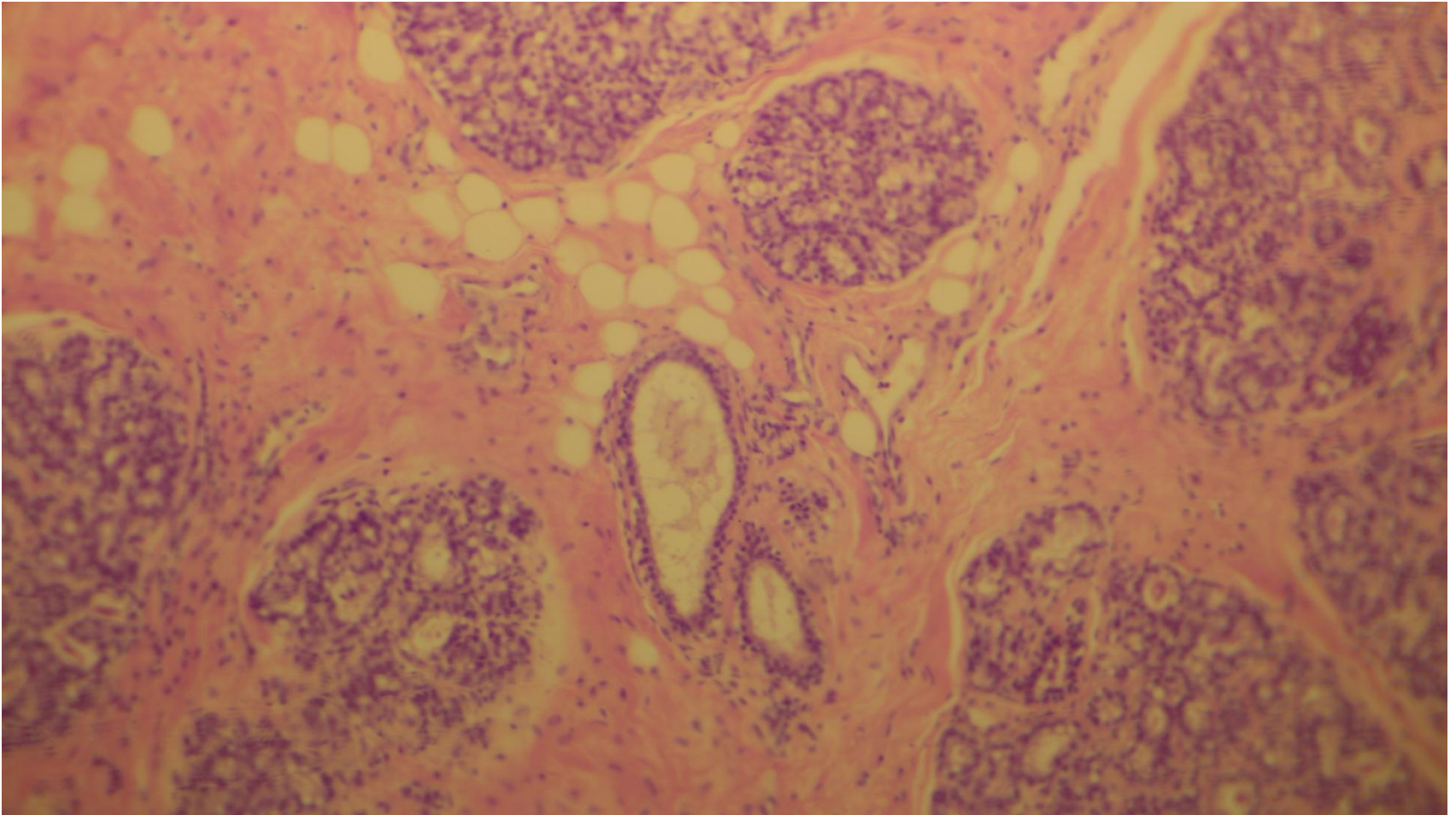




# Mammary gland (active)

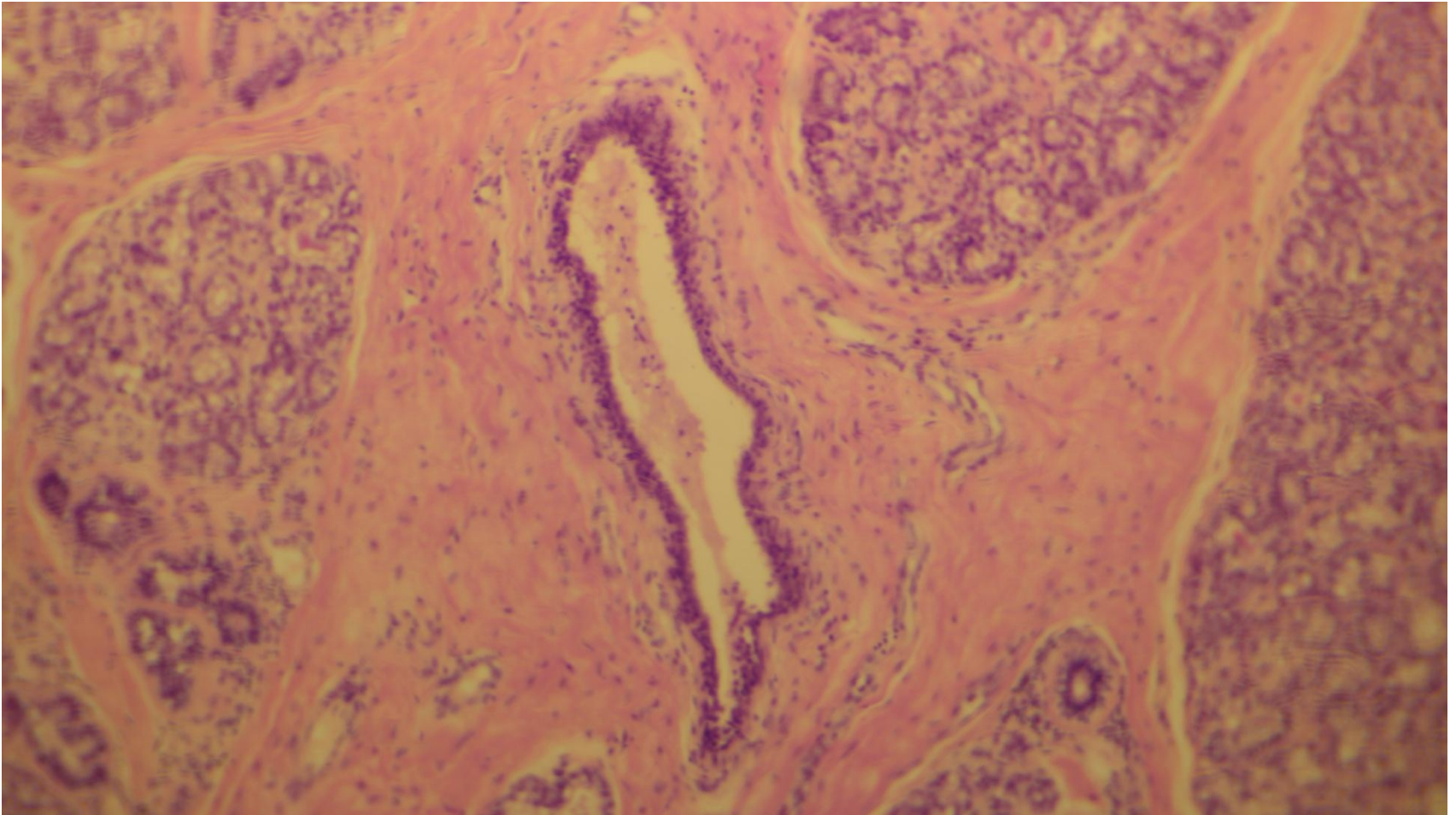


# Duct in active mammary gland





# Duct



**Thank you**