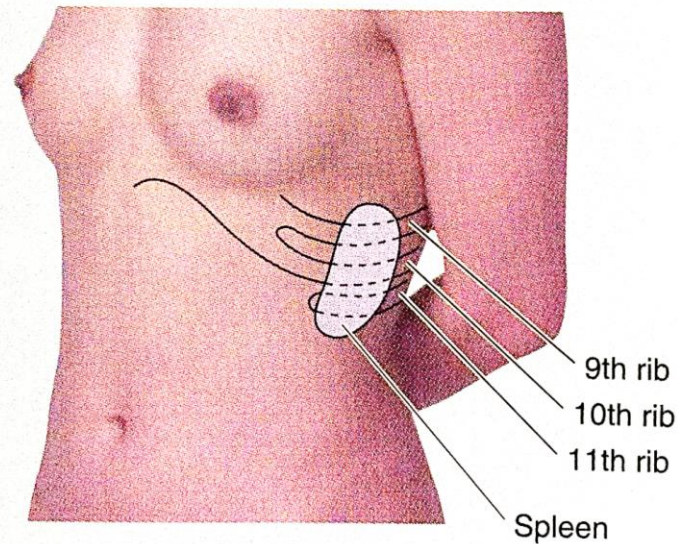
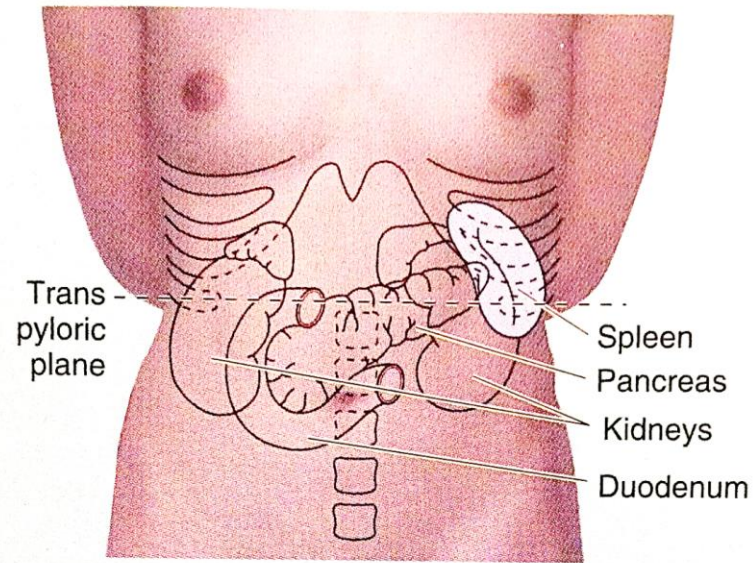


Spleen

# Surface anatomy



# Borders and Surfaces

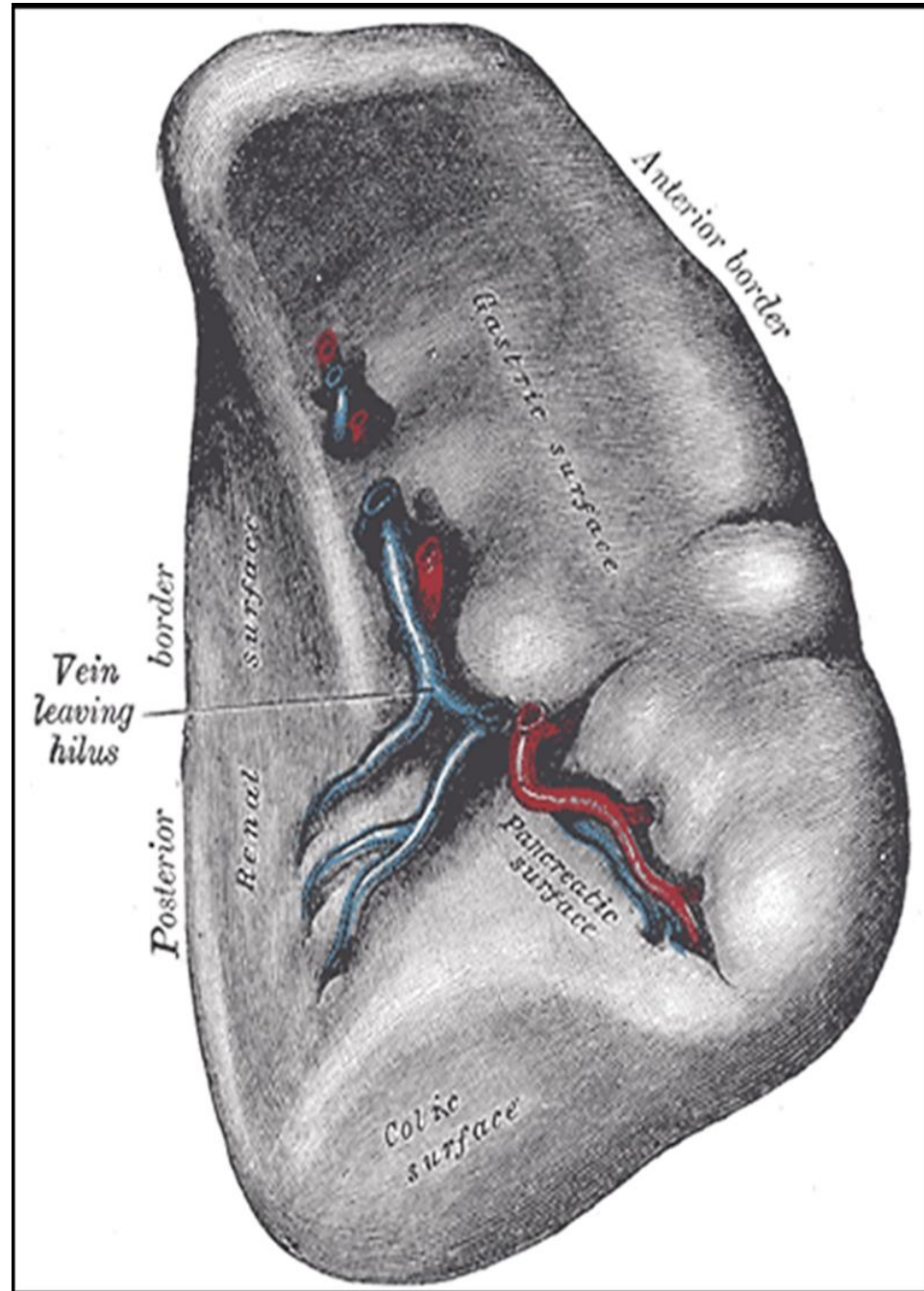
3 borders, 2 ends, 2 surfaces.

## A. Ends

- 1) lateral end (Broad)
- 2) medial end (tapering)

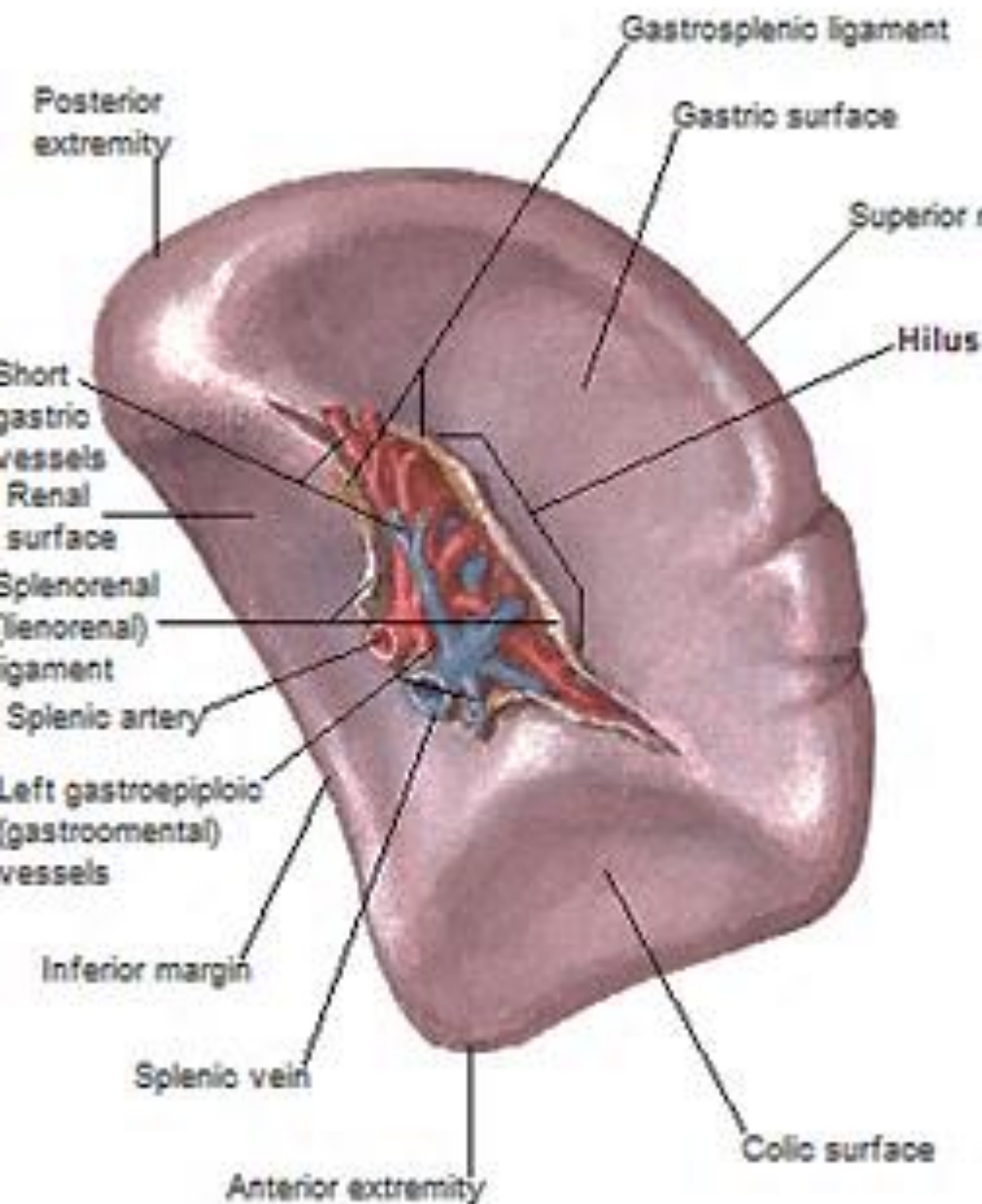
## B. Borders

- **Upper(Anterior) border:** Sharp & notched
- **Lower (Posterior)border:** (Broad)
- **Intermediate border:** thick, incomplete. Extends from the medial end till the hilum).

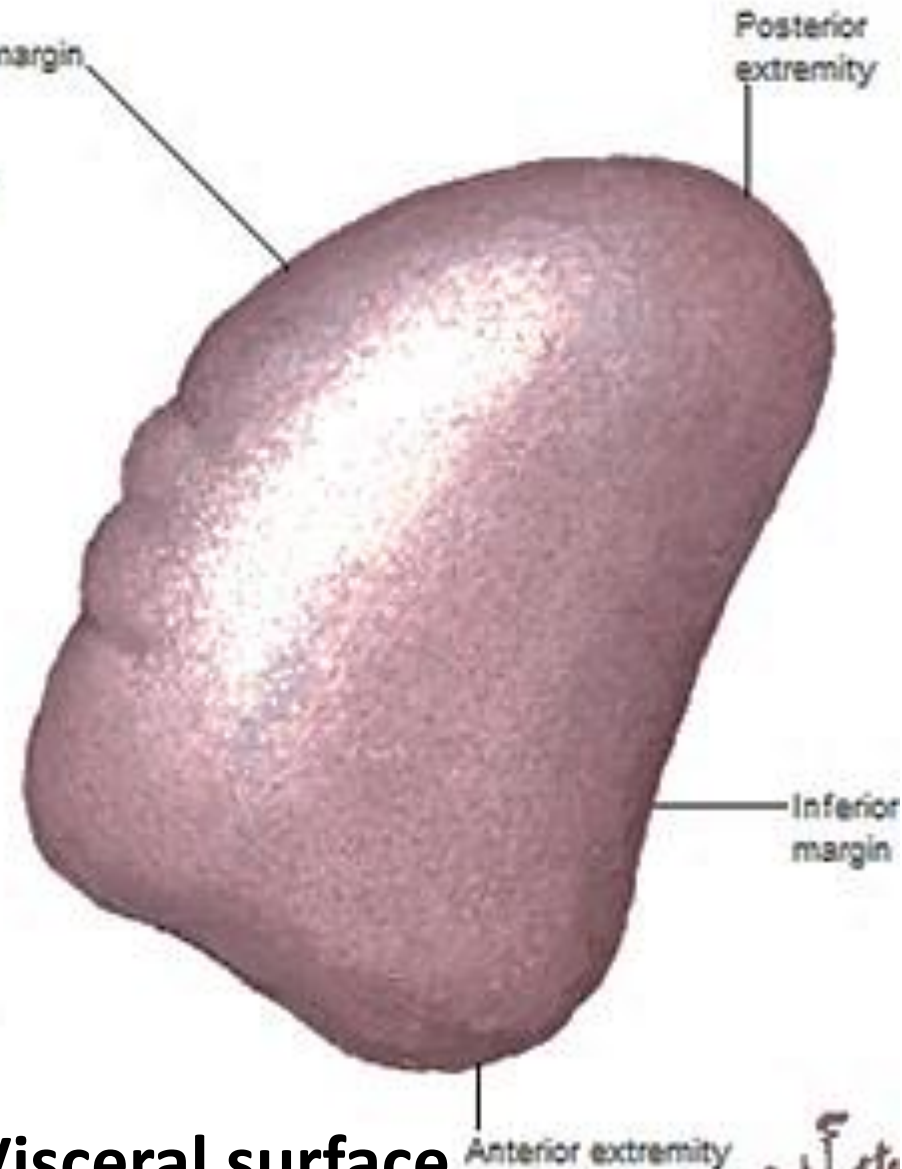




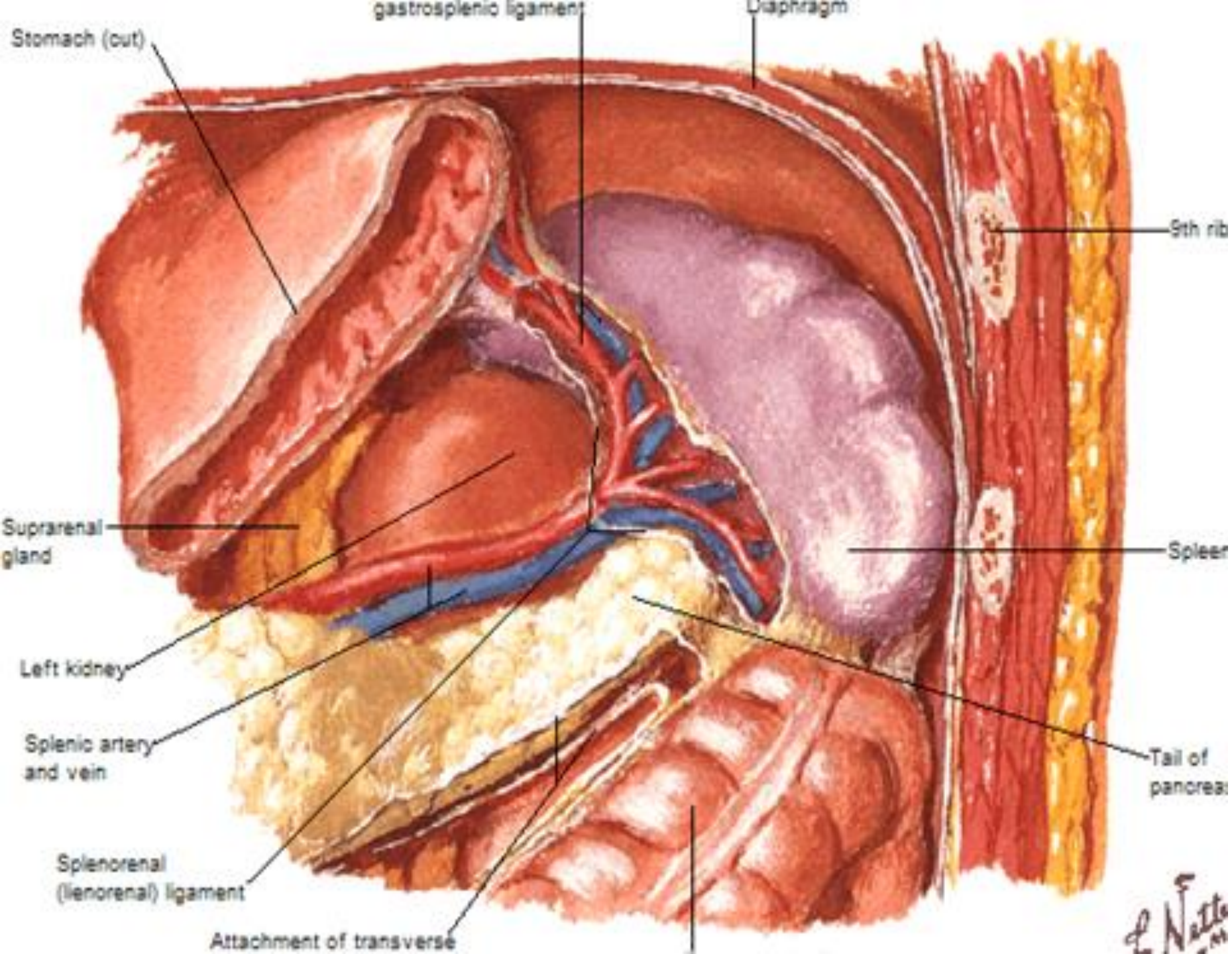
# Borders and Surfaces



**Diaphragmatic surface**

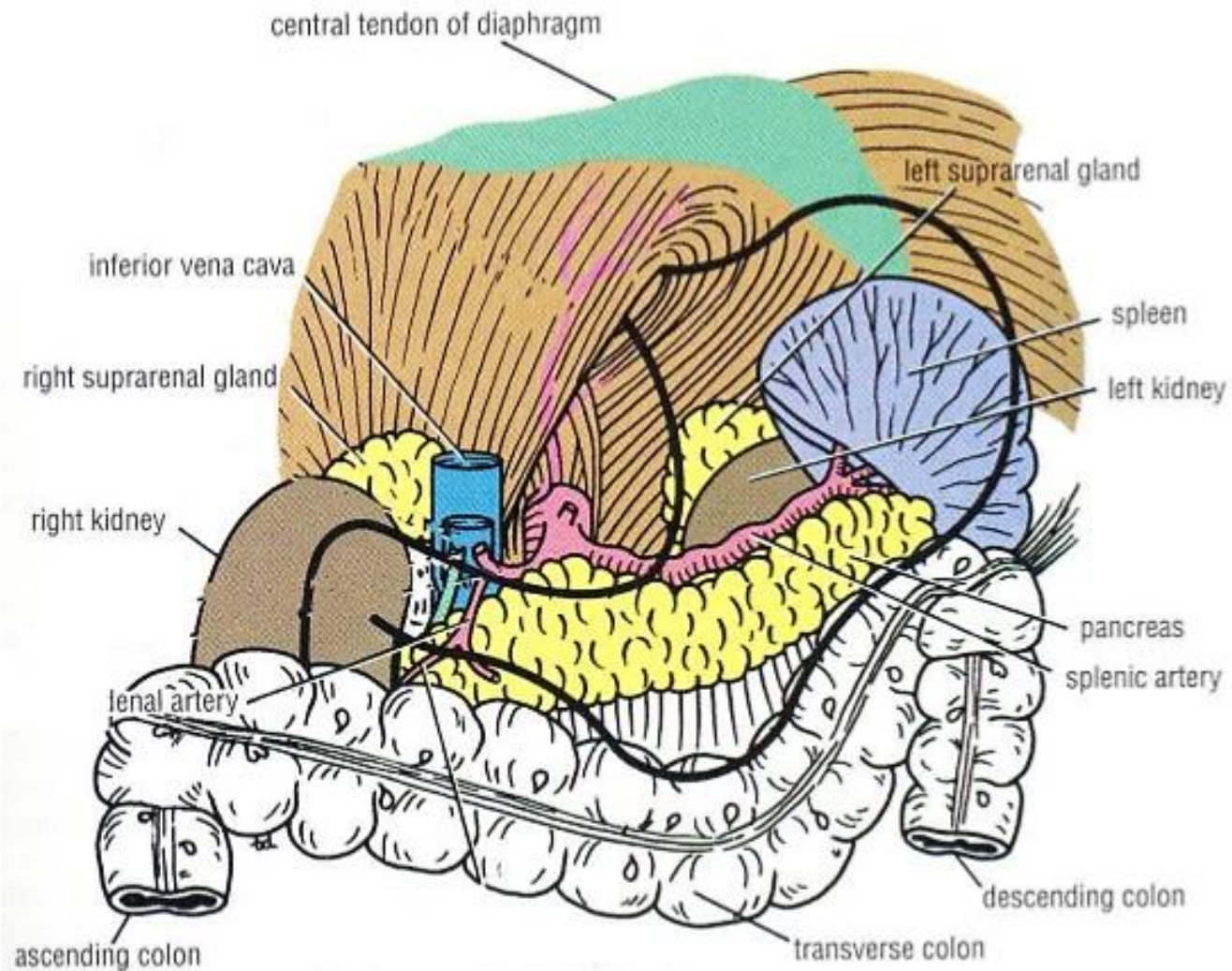


**Visceral surface**

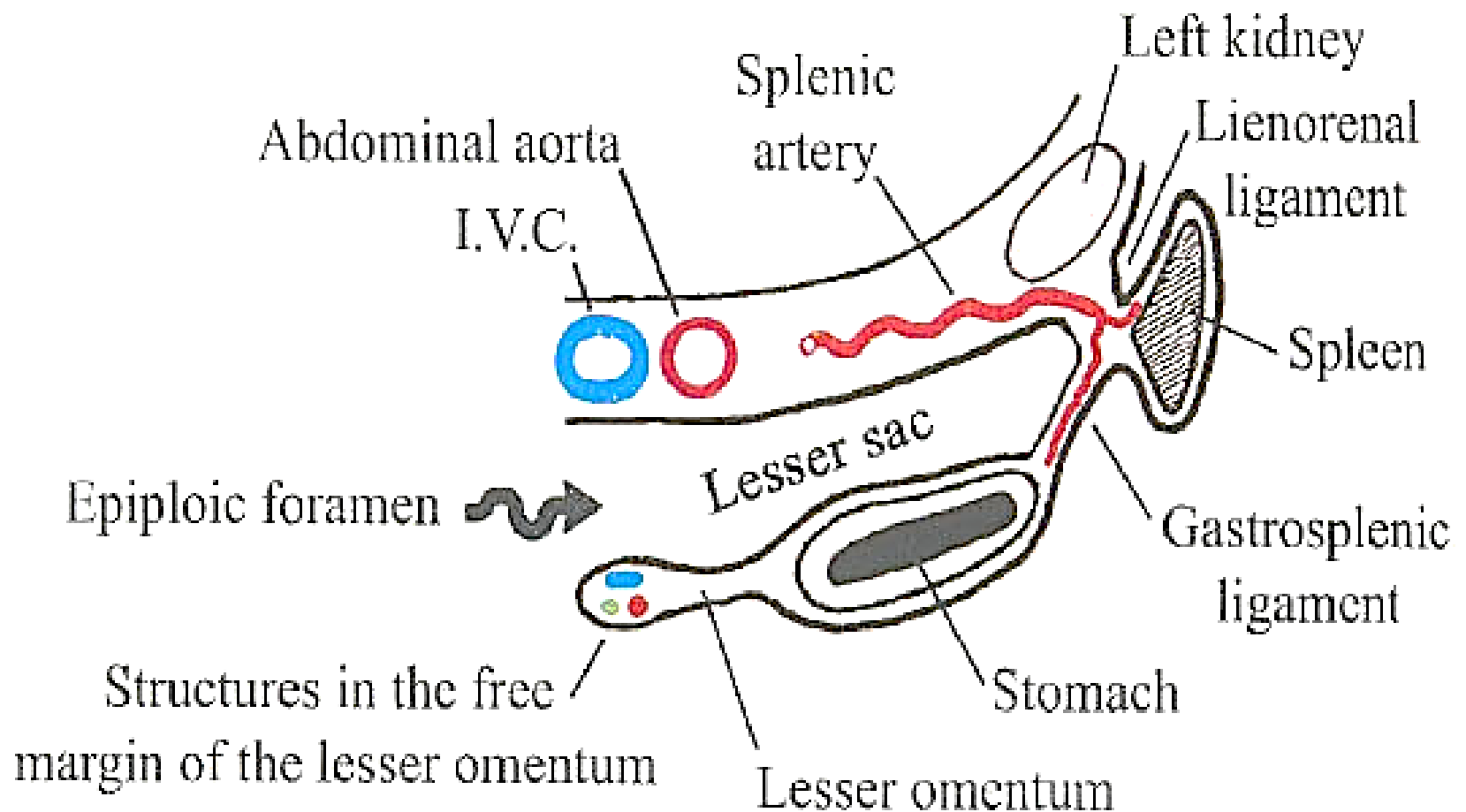




# Relations



# Peritoneal connections



# Peritoneal relations

-The **gastrosplenic ligament** contains:

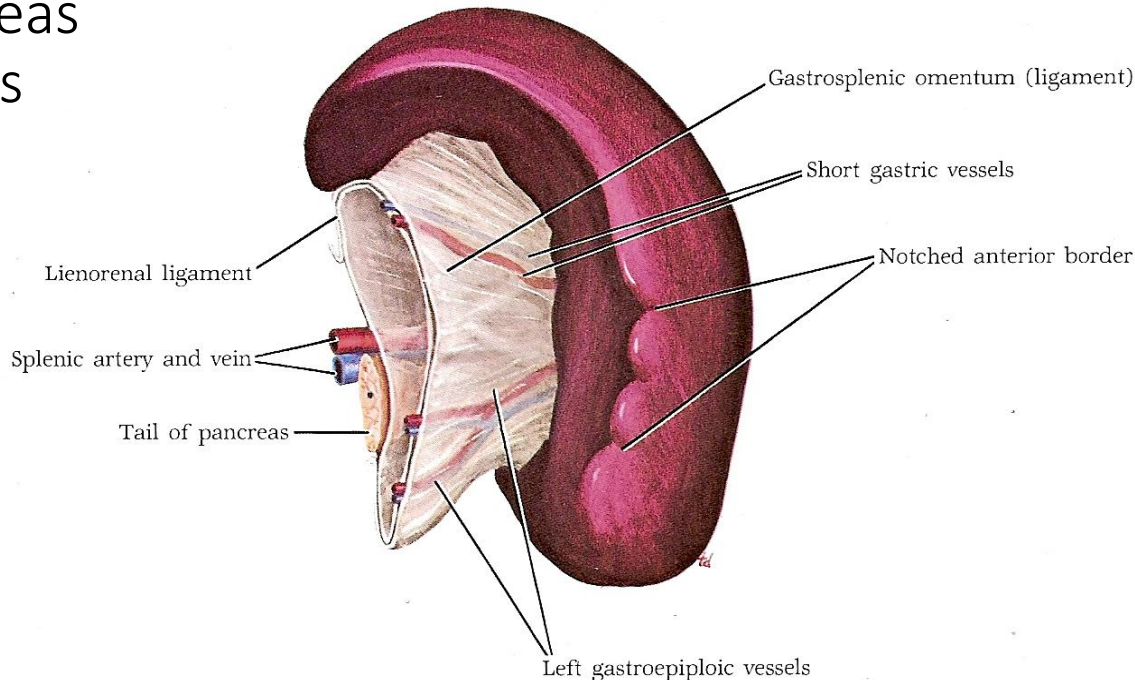
- Short gastric vessels
  - Left gastroepiploic vessels
  - Lymph nodes
- The spleen is completely covered by peritoneum of the greater sac except at the hilum.
- It is attached and related to the following ligaments:

1- Gastro-splenic ligament

The **lienorenal ligament** contains:

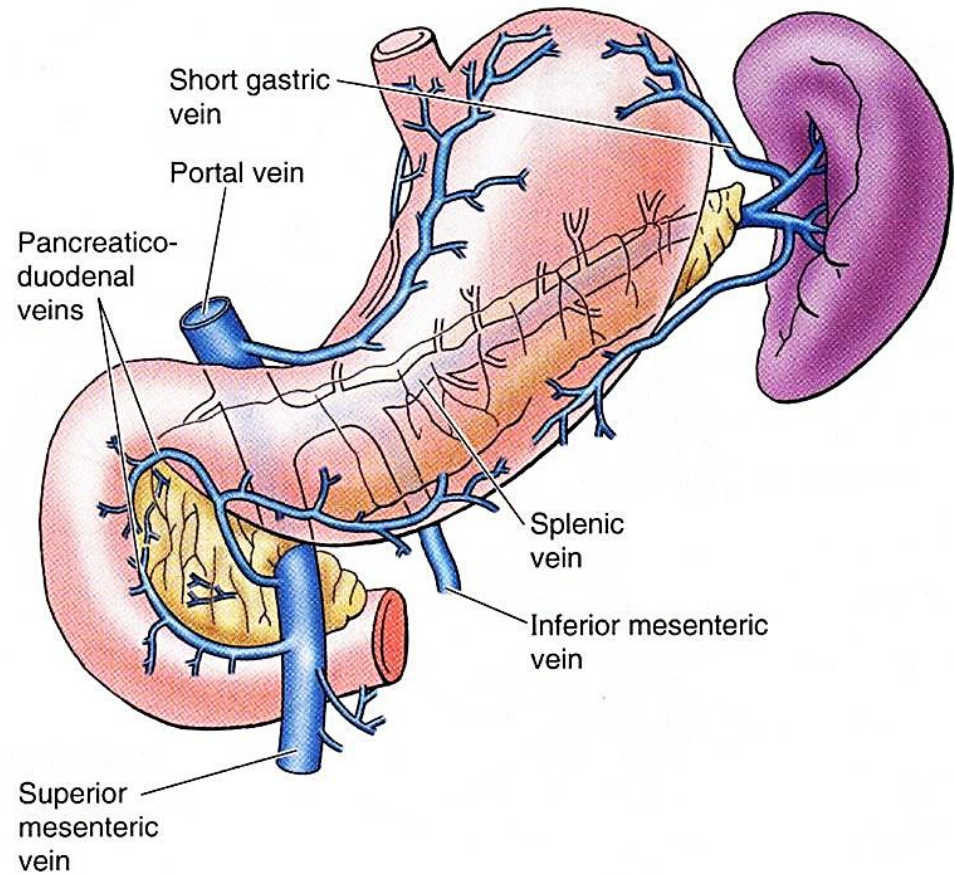
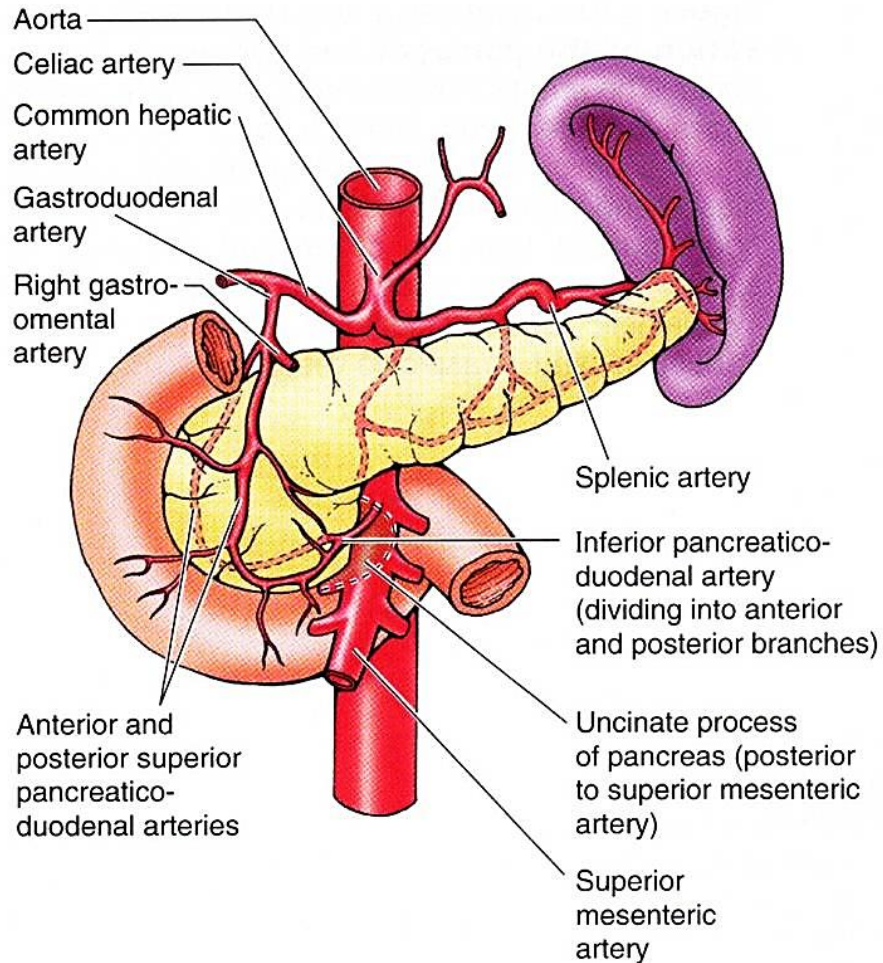
2- Lienorenal ligament.

- Tail of pancreas
- Lymph nodes

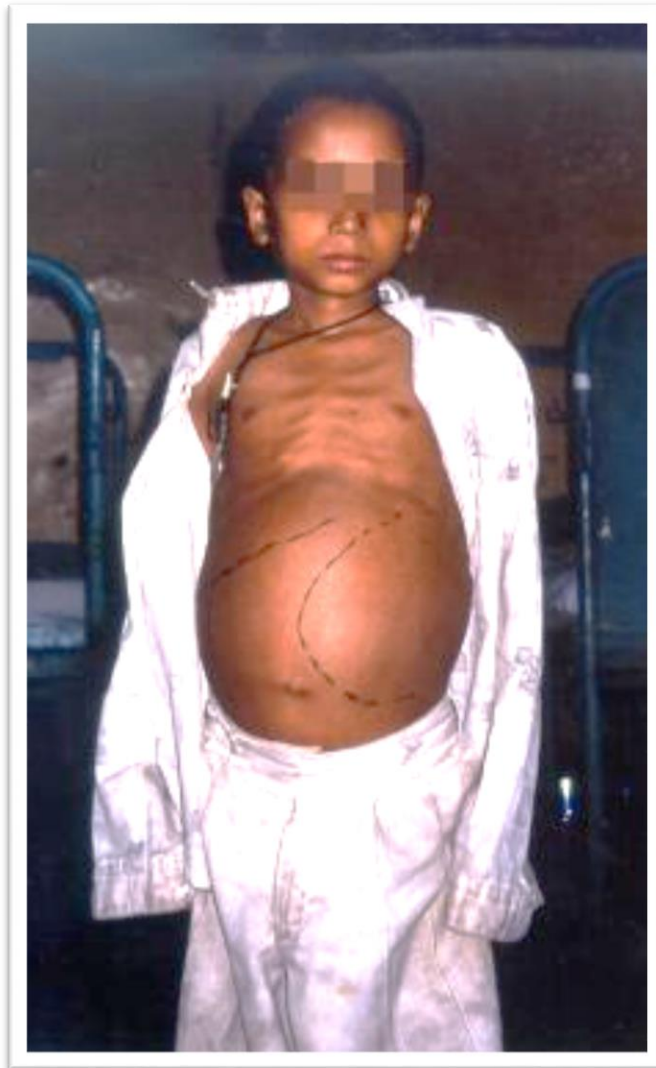



# Blood Supply



# Splenomegaly



# Injured Spleen





# Rupture Spleen

